

Sarcoidosis Masquerading as Atrial Fibrillation: Interesting Case Discussion as Well as Recent Advances in Diagnosis and Management of Cardiac Sarcoidosis

¹Jefferson Curimbaba, MD, ²João Pimenta, MD, PhD, ³José Marcos Moreira, MD, ⁴UISilvia Carla Sousa Rodrigues, MD, PhD, ⁵Ester Nei Aparecida Coletta, MD, PhD, ⁶Carlos A.C. Pereira, MD, PhD.

¹Coordinator of the Cardiology Clinic, Hospital do Servidor Público Estadual, São Paulo, SP, Brazil; ²Director of the Cardiology Service, Hospital do Servidor Público Estadual, São Paulo, SP, Brazil; ³Coordinator of the Holter Section, Cardiology Service, Hospital do Servidor Público Estadual, São Paulo, SP, Brazil; ⁴Pneumology Service, Hospital do Servidor Público Estadual, São Paulo, SP, Brazil; ⁵Pathology Service, Hospital do Servidor Público Estadual, São Paulo, SP, Brazil; ⁶Director of the Pneumology Service, Hospital do Servidor Público Estadual, São Paulo, SP, Brazil, (*) From the Cardiology and Pneumology Services, Hospital do Servidor Publico Estadual, São Paulo, SP, Brazil.

Abstract

This report presents a case of cardiac sarcoidosis initially manifested with atrial fibrillation. This behavior is very uncommon in spite of the fact that the disease is multisystemic, affecting predominantly the lungs. It is emphasized that the diagnosis of the cardiac involvement is difficult, and when this occurs, can lead to conducting system disturbances, heart failure or sudden death (SD). The diagnosis can be made by evaluating the clinical manifestations, the noninvasive tests like ECG, Holter monitoring, chest radiography, thoracic computed tomography, magnetic resonance image and positron emission tomography. In general, sarcoidosis is treated with steroid compounds with good outcome, mainly when performed in the initial phases of the disease. Other cardiac manifestations, such as arrhythmias, atrio-ventricular block or heart failure, are managed similar to other cardiomyopathies.

Introduction

Sarcoidosis is a rare multisystemic disease of unknown origin, characterized by the formation of noncaseating granulomas of epithelioid cells, and it is more common in subjects aged between 2nd and 5th decades of life, but can be occur at any age.^{1,2} This disease is frequently benign with high rates of spontaneous remission and low mortality. It was first described in 1869 by Hutchinson³ as a case of cutaneous sarcoid, but the name of the

disease was suggested in 1899 by Caesar Boeck,⁴ a Norwegian dermatologist, who described epithelioid cell lesions of skin nodules. Almost all organs of the body are affected, mainly the respiratory (lung – 90%) and lymphatic systems.

The cardiac involvement was described by Bernstein et al. in 1929⁵ with different prognosis and outcome. The first series of necropsied cases was reported by Longscope in 1952,⁶ who evaluated 92 cases with 20% of cardiac sarcoidosis (CS). In 1978,

Corresponding Address : Joao Pimenta, MD, PhD, R das Camélias, 357, CEP 04048-060, Sao Paulo, SP, Brazil.

Silverman et al.⁷ described 84 necropsied cases and 27% of them had granulomas in the heart. Although the heart is commonly affected by granulomas, the presence of clinical manifestation is observed in a minority of patients. For example, in one study, 25% of patients had alterations of the myocardial specimens under histological examinations, but only 5% of the cases had clinical manifestations.⁸ The aim of this paper is to report a case of atrial fibrillation as the first manifestation of sarcoidosis, and review the literature concerning clinical manifestations, diagnosis and treatment.

Case Report

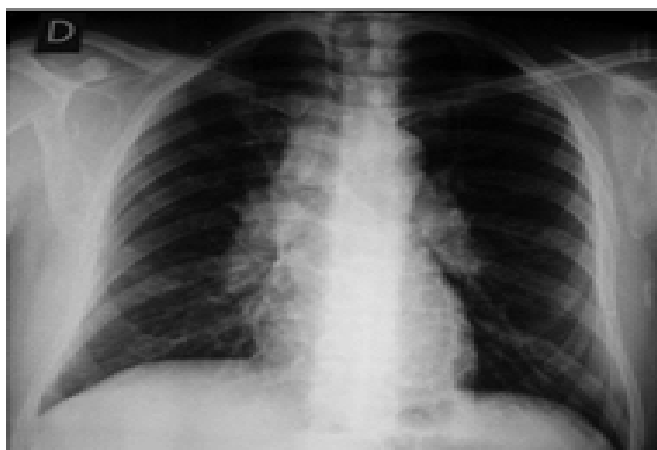
A 46-y-old male patient was admitted in the Emergency Department with pain in his right leg, and dyspnea. Deep vein thrombosis (DVT) in the right leg was diagnosed by venous Doppler ultrasound of the lower limbs, and pulmonary embolism (PE) diagnosed by computed tomography (CT) of the thorax that also showed mediastinal enlargement due to bilateral hilar and para-aortic adenopathy as well as seen in the chest radiography (fig. 1).

The electrocardiogram (ECG) showed sinus rhythm and right bundle branch conduction delay. The patient was admitted for treatment of PE, and adenopathy investigation. His medical history was unremarkable except for DVT in the left leg eight years earlier after having varicose vein surgery. Additional diagnostic tests for thrombotic disorders were negative. Mediastinoscopy with lymph node biopsy showed granulomatous

lymphadenitis without infectious causes (fig. 2).

Investigations for both fungi and tuberculosis were negative. Thus, diagnosis of pulmonary sarcoidosis was confirmed after excluding the possibility of sarcoid reactions secondary to neoplasia. As the patient had abnormal ECG at the cardiac evaluation transthoracic echocardiogram (ECHO) and 24-hour Holter monitoring were performed. ECHO revealed mild increase in the left ventricular diastolic diameter (59 mm) and left ventricle walls in the upper limit of normal. Holter was recorded 20 days later and showed atrial fibrillation (AF) during all time, and 14,90^s (18%) ventricular premature beats. Based on these findings, gallium-67 myocardial scintigraphy were carried out showing no uptake of radio-isotope contrast in the atria and but the cardiac magnetic resonance imaging (MRI) with gadolinium showed inconclusive result. Three months later, PET scan with fluorodeoxyglucose-18 was carried out showing metabolic activity in the lateral wall of the left ventricle, suggesting the diagnosis of CS. Prednisone 40mg daily was administered with significant improvement in the thoracic images, in spite of a new echocardiogram which showed unchanged parameters. He remained with a dose of 40mg by day of prednisone. Chest X-ray showed a reduction in adenopathy. After discharge, therapy with 15mg of prednisone daily was maintained and at 18 months follow up, the patient was asymptomatic in sinus rhythm and right bundle block conduction delay, documented by Holter monitoring, taking 5 mg of warfarin and 50 mg of losartan daily.

Figure 1: Chest Radiography at Admission, Showing Bilateral Hilar and Paraaortic Adenomegaly and a Normal Pulmonary Appearance

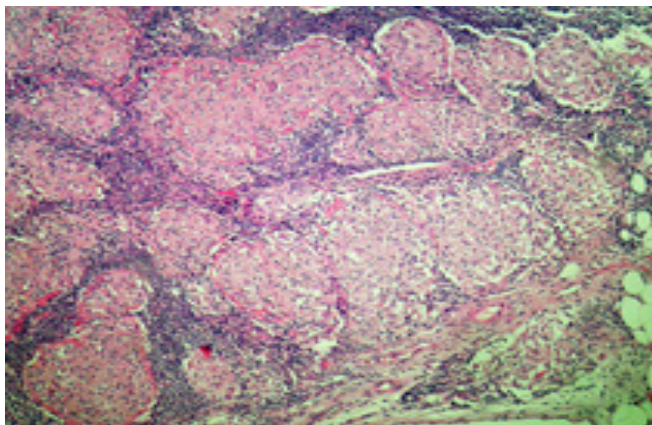


Discussion

As demonstrated in this case, sarcoidosis may be presented with non specific features such as right leg pain and dyspnea due to DVT and PE, and subsequent suspected cardiac involvement. Additional tests such as chest CT with contrast and other consistent findings with thromboembolism as well as the presence of lymph nodes, which biopsy revealed granulomatous lymphadenitis without infectious causes, led to the diagnosis of pulmonary sarcoidosis stage I of Scadding score.⁹

The Oxford Record Linkage Study, which studied 1,002 patients admitted with the diagnosis of sarcoidosis revealed that those patients have ele-

Figure 2: Histology of Lymph Node Showing Substitution of the Cellular Architecture by non Caseating Granulomas Surrounded by Lymphoid Tissues. H.E; 100X



vated risk of PE (OR- 2, CI- 95%= 1.1 increased to 3.4 when the age was limited to 65 years).¹⁰ In a different study, which evaluated 23,679 death certificates of US decedents, an independent and positive relationship between sarcoidosis and PE was confirmed, regardless the gender, ethnicity and age.¹¹ The relationship between PE and sarcoidosis is not yet confirmed, speculating the possibility of the involved mechanisms could be due to the presence of antiphospholipidic antibodies, suggested by an isolated study, in 21 out of 55 patients with sarcoidosis.¹² In this case the PE and DVT could be secondary to sarcoidosis, but the presence of local vascular abnormalities such as intrinsic venous disease could not be ruled out.

The first cardiac manifestation of the disease in the described case is unusual due to the presence of AF, without atrial enlargement secondary to the left ventricular dysfunction and/or pulmonary hypertension with cor pulmonale. Some patients may also present granulomatous infiltration of the atria. The abnormalities observed in other tests as ECG and ECHO helped us to suspect the presence of cardiac involvement. The analysis of our case revealed some limitations as relying on a PET scan, an important tool, otherwise being evaluated by MRI and scintigraphy, that it was not able to show abnormalities compatible with CS, probably as the exam was performed under prednisone treatment with 40mg daily which could show a false-negative result. Also, the detection of small foci of sarcoid atrial infiltration could be beyond the limited spatial resolution of both SPECT and MRI. The presence of atrial fibrillation seemed to be not

related to the PE due to the low hemodynamic repercussion and its late appearance, recorded about 20 days after the acute phase during a Holter monitoring, and spontaneous conversion to sinus rhythm after the corticosteroid therapy, without recurrence. The same can be interpreted with the right bundle branch disturbance, because this defect remained until the last ambulatory visit, two years later. Then, the diagnosis of CS was inferred by the association of clinical and laboratory data like palpitation, ECG abnormalities (at rest and by Holter) and ECHO.¹³

Clinical presentation

Clinical diagnosis of CS has been a challenge, because 40-50% of those patients with evidence of CS at the necropsy had no clinical suspicions of cardiac involvement. In Japan, CS is more common than in Europe and in the USA, occurs in about 70% of the necropsied cases,¹⁴ with higher mortality rate of, up to 85% of the cases of sarcoidosis,¹⁵ with a preference in women aged 40 or above. Such behavior was not found elsewhere. In general, sarcoidosis affects people in the 4th and 5th decades of life, but can be seen in young, adolescents and children. The isolated cardiac damage, reported by several investigators, is considered extremely infrequent, generally depending on the future systemic involvement of the disease. In spite of the fact that all cardiac structures can be affected, the damage of the myocardium is the most common finding – with decreasing order of involvement –, the left ventricular free wall, papillary muscles and the atria.¹⁶ CS may be diagnosed by chance in an asymptomatic individual or present with a range of symptoms such as palpitations, chest pain, heart failure, syncope and SD. The symptoms depend on the location and the extension of the cardiac damage or any associated disease. Symptoms can be secondary not only to by the formation and development of the noncaseous granuloma in several locations of the cardiac structures, but also to the healing process which leads to the substitution by fibrosis.

Three main consequences can be found in the heart anatomy: cardiac conducting system abnormalities, arrhythmias and heart failure. Atrial arrhythmias, such as premature ectopic beats, AF, atrial flutter, and ectopic atrial tachycardias are less frequent than ventricular arrhythmias.^{16,17}

They are generally due to the atrial enlargement secondary to the ventricular dysfunction and/or cor pulmonale, being uncommon due to the atrial infiltration of the sarcoid granuloma. Left ventricular aneurysms can be found as well as mitral regurgitation, heart failure, pericarditis, pericardial effusion, cardiac tamponade, conducting system disturbances [atrioventricular (AV) block of different degrees, bundle branch block] and atrial and ventricular arrhythmias which can lead to SD. Right ventricle is rarely affected as an unique lesion, and when this occurs, can simulate arrhythmogenic right ventricular dysplasia, with poor clinical outcome.^{18,19}

The cardiac involvement is the second cause of SD in patients with sarcoidosis,^{20,21} generally due to heart failure and arrhythmic death, with strong impact in the outcome of these patients because this event may be the first manifestation of the disease.²²

SD is the most feared manifestation of the sarcoidosis. Its incidence varies widely, from 24 to 67% of cases,^{16,23} and may be caused by complete AV block and ventricular arrhythmias.²⁴ AV block is thought to be caused by granulomatous infiltration of the conducting system of the heart, and less commonly due to lesion of the AV nodal artery and consequent ischemia.²⁵ Ventricular arrhythmias, as sustained form, and rarely fibrillation, occur secondarily to reentry, because the granulomas cause sites of slow conduction facilitating the reentry, or the enhance of the focal automaticity.²⁶ Another rare cause of SD secondary to CS is due to sinus nodal arrest.²⁴ Functional class III (NYHA) heart failure, left ventricular diastolic diameter and prior documented sustained ventricular tachycardia are reported as independent risk factors for mortality.²⁷

Diagnosis

Diagnosis of CS remains a challenge to the specialists mainly due to its unknown pathophysiology, absence of classic clinical pictures and confusion with other diseases. CS is usually a diagnosis of exclusion, because the available diagnostic tests have limited sensitivity and specificity, and the absence of a true biological marker. It is difficult diagnosis of exclusion because it has different clinical manifestations such as atrial and ventricular arrhythmias, conducting system defects,

heart failure and even SD. In the United States, the ACCESS Study showed that the symptomatic cardiac involvement occurred in about 5% of the cases of systemic disease,²⁸ though in Japan – where the mild ECG abnormalities were included in the diagnostic protocol as cardiac involvement – the prevalence of CS was 23%.²⁹ In post-mortem studies, the incidence of CS ranged between 20 to 70%.³⁰ Even myocardial biopsy, which is considered a gold-standard method, can be negative if regions of the myocardium that contains no granuloma are biopsied. The etiology is still not completely understood. Currently there is evidence of an exaggerated autoimmune response to a variety of antigens or self-antigens resulting in CD4 accumulation, activation or release of inflammatory cytokines leading to granuloma formation.² Infectious, inflammatory, genetic, and environmental causes or combinations, have been reported but not yet fully proven.²⁰

This is a disease with complex etiology in a heterogeneous group of disorders mediated by a final common pathway, which is a granulomatous inflammation in susceptible individuals with a polygenic inheritance.²³

There are several diagnostic classifications for sarcoidosis like the Guidelines of the Japanese Ministry of Health and Welfare,³¹ revised in 2006,³² the ACCESS,³³ the STAI³⁴ and the American Thoracic Society and World Association for Sarcoidosis and Other Granulomatous Disorders.³⁵ However, they are still inadequate because more accurate diagnosis and assessment of the disease's activity and the degree of involvement in each organ is not included in those classifications. This appears to be due to the fact that only patients with advanced stage of the disease were selected, resulting in underestimation of the true incidence of the type of cardiac involvement. All classifications were based on a series of tests such as ECG, Holter, ECHO and myocardial scintigraphy with gallium, thallium or technetium. More recently, technological advances such as PET and MRI have been showed very useful in the diagnosis at the earliest stages of the disease, as well as in the follow-up, but large clinical studies need to show its role in the follow-up of those patients.^{36,37} A high degree of a clinical suspicion associated with laboratory and image tests are crucial for diagnosis of CS. CS should always be considered in patients with newly diagnosed complete AV block, heart

failure and/or ventricular tachycardia without apparent cause, as differential diagnosis. Because CS is a life-threatening condition and there is potential benefit of an early treatment, all patients diagnosed with extracardiac sarcoidosis should be thoroughly investigated for cardiac involvement. Detailed clinical history and physical examination can provide evidence of the cardiac involvement. Changes in diagnostic tests such as ECG, ECHO and Holter possibly indicates the necessity for more complex tests such as thallium scintigraphy, technetium, gallium, MRI and PET, and even, endomyocardial biopsy. Although myocardial biopsy has high specificity, it has low sensitivity.

Laboratory Approaches

The most used tests are ECG, ambulatory Holter monitoring and ECHO. ECG may show abnormal conduction disturbances as abnormal left axis deviation, bundle branch block, commonly right bundle, and AV block, atrial and ventricular arrhythmias, pathological Q waves, and abnormalities in the ST-T segment. These findings are not specific, but are highly suspicious of the cardiac involvement in patients with extra-cardiac sarcoidosis.

Ambulatory Holter monitoring plays a similar role despite of the low sensitivity and specificity. Beyond the changes observed in the ECG, the density of ventricular premature beats is an important finding and, when greater than 100/24h, highly suggests CS.³⁸

The ECHO has a low to moderate sensitivity and low specificity. The alterations often found are regional abnormal contractility, ventricular aneurysm, pericardial effusion, systolic and diastolic left ventricular dysfunction, abnormal septal thickness (thinning or thickening), and valve dysfunction, but such abnormalities are nonspecific and are not present in early stages. The use of tissue Doppler and transesophageal ECHO appears to increase the sensitivity, but more studies are needed to confirm the importance of these methods in the assessment of patients with sarcoidosis.

Scintigraphy with either thallium-201 or technetium-99m has moderate sensitivity and specificity. The absence of radionuclide uptake at rest – due to granuloma in the myocardium, micro-

vascular vasoconstriction, and metabolic disorders – disappear during exercise and after the infusion of vasodilators (reverse distribution). These findings are not specific, but highly suggestive of CS. Besides the diagnosis, this technique may evaluate the response to treatment, by observing improvement or disappearance of failures of radiotracer uptake.

Scintigraphy with gallium-67 has low sensitivity and high specificity, and may detect the active inflammatory phase of the disease. Despite of the new techniques of signal acquisition there is still a limitation on the differentiation between cardiac and pulmonary uptake. However, in both imaging features, gallium scintigraphy is useful for monitoring response to the treatment, although the areas of fibrosis are not properly detected. The combination with other radionuclide techniques increases the sensitivity for consistent diagnosis.

PET scan with fluorodeoxyglucose-18 has high sensitivity and moderate to high specificity, and it is considered to be the test with the best sensitivity, even in early stages of the disease. It has also the advantage of using lower dosage of radiation. However, when used in combination with ⁸²Rb reliable images of perfusion can be obtained. Furthermore, it can obtain perfusion images which allow measuring the degree of the activity of the disease, to detect the extension of fibrosis in the myocardium, and it is also useful to assess the effectiveness of the treatment.

MRI with gadolinium shows moderate to high sensitivity and high specificity. It can show abnormalities in the contractility and the wall thickness, with the advantage of having a better spatial resolution and it is used to guide endomyocardial biopsy. The enhancement of the image identifies areas of inflammation associated with edema, since the delayed enhancement shows combination of fibrosis and inflammation. It can also be used as a follow-up guide of the treatment. As cardiac MRI does not carry risk of radiation exposure, it can be done multiple times, although it can be employed with caution in patients with cardiac implantable devices.

Myocardial biopsy is the gold-standard exam for the diagnostic of CS, and is the only test that confirms the true cardiac involvement. This is demon-

strated by the finding of noncaseating granuloma, which is not identified by any of the already mentioned tests. However, it has low sensitivity because CS does not affect the myocardium homogeneously and it is possible that non affected myocardium is biopsied. Because it is an invasive procedure, and has potential risks, there are guidelines for its indication to avoid.³⁹ A patient with extracardiac sarcoidosis and negative biopsy does not exclude the diagnosis of CS and should be treated if there is high suspicion of cardiac involvement.

Another matter in diagnosis is that CS is too difficult to be identified, because myocardial fibrosis is commonly unapparent, or conducting system abnormalities are not evident before the cardiac damage could be detected. In a recent report, the conducting system of patients with diagnosis of sarcoidosis, with and without cardiac involvement, was analyzed by electrophysiological study (EPS).⁴⁰ High incidence of conducting disturbances and arrhythmias in the studied population (68.2 %) with emphasis on ventricular arrhythmias in 24-hour Holter monitoring was demonstrated. Also, it was observed prolongation of the HV interval and atrial electrical instability, besides the induction of AF in 31.8% of patients. These EPS abnormalities were found in a significant percentage of sarcoidosis patients without evidence of cardiac symptoms corroborate with the existence of latent or minimal myocardial involvement even before the diagnosis of CS. It is also observed that the occurrence of changes in some parameters (signal averaged ECG, QT dispersion, increased heart rate during exercise and heart rate variability) in the group of patients with pulmonary sarcoidosis but with no evidence of cardiac involvement was statistically significant when compared with the control group.⁴¹⁻⁴⁴

Therapeutic Options

Steroids compounds are the cornerstone of the therapy and they are used in high doses for longer time. In this reported case, prednisone 40 mg daily controlled atrial fibrillation, but regression of left ventricular and hypertrophy were not documented. The optimal dose and treatment duration are still a matter of debate. Yazaki et al²⁷ did not show significant differences in prognosis in patients treated with doses >40 mg compared to <30

mg daily. Actually, the tendency is to use higher doses for longer periods (6 to 12 months), when evaluating patients for clinical response and the possibility of recurrence in case of reduction or discontinuation of the drug. Treatment initiation with corticosteroids in asymptomatic patients is advocated by several authors, but still needs confirmation with prospective studies.⁴⁵ If a patient is intolerant to steroids, other immunosuppressive drugs, such as methotrexate, azathioprine, infliximab, cloroquine, cyclophosphamide, thalidomide and pentoxifylline, can be used as a single agent or in combination with corticosteroids, but these strategies still need further studies to validate their efficacy.⁴⁶⁻⁴⁸

If heart failure is present, the optimized therapy with beta-blockers, spironolactone and angiotensin converting enzyme inhibitors or angiotensin receptor blockers should be used similarly to heart failure from other etiologies. Although for atrial and ventricular arrhythmias, antiarrhythmic drugs may be used, usually with little effect mainly in patients with major cardiac involvement⁴⁹ and its action may precipitate or worsen the conducting system disorders. The indication and use of pacemakers, implantable cardiac defibrillators and resynchronization are already addressed in recent guidelines.⁵⁰ Radiofrequency ablation in patients with ventricular arrhythmias or frequent appropriated ICD therapy has limited value, especially because the extent and heterogeneity of myocardial injury and its degree of evolution.⁵¹⁻⁵² The use of electroanatomic mapping system seems to help in these cases.

In some patients, heart transplantation may be indicated with satisfactory results, but this approach still must be reviewed by the lack of donors and cases of recurrence in transplanted hearts.⁵³⁻⁵⁵

Risk stratification is essential for SD because of its unpredictable prognosis. There are a multitude of methods such as ambulatory Holter monitoring, heart rate variability, high resolution ECG, QT dispersion, micro-T wave alternans, EPS, which indicate the risk of SD. Such tests have little value when used alone, but when used in association they are more useful, although less evaluated in CS than in ischemic heart disease.

The importance of EPS in the CS, although still not well defined, is to evaluate the conducting

system, because the high prevalence of granulomatous infiltration in this tissue with rates of SD due to complete AV block up to 40% .¹¹ However, this aspect has been little explored. As a guide for therapeutic drugs, the results were disappointing.^{21,49} On the other hand, it is used as a guide in support of defibrillator implantation⁵⁰ and on international guidelines for risk stratification of SD, especially in patients with a history of syncope and with a wide QRS tachycardia, corresponding to advanced stages of the disease, but not having the same demonstrated efficacy as in patients with ischemic heart disease. For asymptomatic and mildly symptomatic patients their use is recommended by some groups, but more studies are needed to validate it. As the CS is a progressive disease, a non-inducibility of arrhythmia in a given period may not be a guarantee of good outcome in the future.

In summary, this report has a great interest represented by an atypical case of cardiac involvement in sarcoidosis, initially manifested by PE and atrial fibrillation. Either atrial fibrillation or PE is an atypical manifestation of a potentially fatal disease, often not permitting early diagnosis and treatment which are essentials in the prognosis of the patient.

Disclosures

No disclosures relevant to this article were made by the authors.

References

- Iannuzzi MC, Rybicki BA, Teirstein AS. Sarcoidosis. *N. Engl. J. Med.* 2007; 357: 2153-2165.
- Thomas PD, Hunninghake GW. Current concepts of the pathogenesis of sarcoidosis. *Am. Rev. Respir. Dis.* 1987; 135: 747-760.
- Hutchinson J. Cases of Mortimer's Malady. *Arch. Surg.* 1898; 9: 307.
- Boeck C. Multiple benign sarcoid of the skin. *J. Cutan. Genitourin. Dis.* 1899; 17: 543-550.
- Bernstein M, Konzlemann FW, Sidlick DM. Boeck's sarcoid: report of a case with visceral involvement. *Arch. Intern. Med.* 1929; 44: 721-734.
- Loncope WT, Freiman DG. A study of sarcoidosis: based on a combined investigation of 160 cases including 30 autopsies from The Johns Hopkins Hospital and Massachusetts General Hospital. *Medicine (Baltimore)* 1952; 31: 1-132.
- Silverman KJ, Hutchins GM, Bulkley BH. Cardiac sarcoid: a clinicopathologic study of 84 unselected patients with systemic sarcoidosis. *Circulation* 1978; 58: 1204-1211.
- Sharma OP, Maheshwari A, Thaker K. Myocardial sarcoidosis. *Chest* 1993; 103: 252-259.
- Scadding JG. Prognosis of intrathoracic sarcoidosis in England. A review of 136 cases after five years observation. *Br. Med. J.* 1961; 2: 1165-1172.
- Crawshaw AP, Wotton CJ, Yeates DGR, Goldacre MJ, Ho L-P. Evidence for association between sarcoidosis and pulmonary embolism from 35-year record linkage study (letter). *Thorax* 2011; 66: 447-448.
- Swigris JJ, Olson AL, Huie TJ, Fernandez-Perez ER, Solomon JJ, Sprunger D, Brown KK. Increased risk of pulmonary embolism among US decedents with sarcoidosis from 1988 to 2007. *Chest* 2011; 140: 1261-1266.
- Ina Y, Takada K, Yamamoto M, Sato T, Ito S, Sato S. Antiphospholipid antibodies. A prognostic factor in sarcoidosis? *Chest* 1994; 105: 1179-1183.
- Mehta D, Lubitz SA, Frankel Z, Wisnivesky JP, Einstein AJ, Goldman M, Machac J, Teirstein A. Cardiac involvement in patients with sarcoidosis. Diagnostic and prognostic value of outpatient testing. *Chest* 2008; 133: 1426-1435.
- Iwai K, Takemura T, Kitaichi M, Kawabata Y, Matsui Y. Pathological studies on sarcoidosis autopsy. II. Early change, mode of progression and death pattern. *Acta Pathol. Jpn.* 1993; 43: 377-385.
- Doughan AR, Williams BR. Cardiac sarcoidosis. *Heart* 2006; 92: 282-288.
- Roberts WC, McAllister HA Jr, Ferrans VJ. Sarcoidosis of the heart: A clinicopathologic study of 35 necropsy patients (group I) and review of the 78 previously described necropsy patients (group II). *Am. J. Med.* 1977; 63: 86-108.
- Shammas RL, Movahed A. Sarcoidosis of the heart. *Clin. Cardiol.* 1993; 16: 462-472.
- Shiraishi J, Tatsumi T, Shimoo K, Katsume K, Mani H, Kobara M, Shirayama T, Azuma A, Nakagawa A. Cardiac sarcoidosis mimicking right ventricular dysplasia. *Circ. J.* 2003; 67: 169-171.
- Corrado D, Thiene G. Cardiac sarcoidosis mimicking arrhythmogenic right ventricular cardiomyopathy/dysplasia: the renaissance of endomyocardial biopsy? *J. Cardiovasc. Electrophysiol.* 2009; 20: 477-479.
- Baughman RP, Lower EE, du Bois RM. Sarcoidosis. *Lancet* 2003; 361:1111-1118.
- Baughman RP, Winget DB, Bowen EH, Lower EE. Predicting respiratory failure in sarcoidosis patients. *Sarcoidosis Vasc. Diffuse Lung Dis.* 1997; 14: 154-158.
- Hageman GJ, Wurm L. The clinical, electrocardiographic and pathological features of cardiac sarcoidosis. In: Willians WJ, Davies BH, eds. *Sarcoidosis and other granulomatous disease.* 8th Ed., London, Alphas Omega. 1980; 601-606.
- Kim JS, Judson MA, Donnino R, Gold M, Cooper Jr LT, Prystowsky EN, Prystowsky S. Cardiac sarcoidosis. *Am. Heart J.* 2009; 157: 9-21.
- Abeler V. Sarcoidosis of the cardiac conducting system. *Am. Heart J.* 1979; 97: 701-707.
- Desai MY, Fallert MA. Rapidly progressing congestive heart

- failure due to cardiac sarcoidosis involving papillary muscles: a case report and brief review of the literature. *Cardiol. Rev.* 2003; 11: 163-168.
26. Furushima H, Chinushi M, Sugiura H, Kasai H, Washizuka T, Aizawa Y. Ventricular tachyarrhythmia associated with cardiac sarcoidosis: its mechanisms and outcome. *Clin. Cardiol.* 2004; 27: 217-222.
27. Yazaki Y, Isobe M, Hiroe M, Morimoto S, Hiramitsu S, Nakano T, Izumi T, Sekiguchi M, for the Central Japan Heart Study Group. Prognostic determinants of long-term survival in Japanese patients with cardiac sarcoidosis treated with prednisone. *Am. J. Cardiol.* 2001; 88: 1006-1010.
28. Baughman RP and ACCESS Research Group. Clinical characteristics of patients in a case control study of sarcoidosis. *Am. J. Resp. Crit. Care. Med.* 2001; 164: 1885-1889.
29. Morimoto T, Azuma A, Abe S, Usuki J, Kudoh S, Sugisaki K, Loritsu M, Nukiwa T. Epidemiology of sarcoidosis in Japan. *Eur. Respir. J.* 2008; 31: 372-379.
30. Lynch JP, 3rd, Sharma OP, Baughman RP. Extrapulmonary sarcoidosis. *Semin. Respir. Infect.* 1998; 13:229-254.
31. Hiraga H, Yuwai K, Hiroe M. Guideline for diagnosis of cardiac sarcoidosis: study report on diffuse pulmonary diseases from Japanese Ministry of Health and Welfare. Tokyo: Japanese Ministry of Health and Welfare; 1993; 23-24.
32. Hiraga H, Yuwai K, Hiroe M. Diagnostic standard and guidelines for sarcoidosis. *Jpn. J. Sarcoidosis and Granulomatous Disorders* 2007; 27: 89-102.
33. Judson MA, Baughman RP, Teirstein AS, Terrin ML, Yeager H, Jr., by the ACCESS Research Group. Defining organ involvement in sarcoidosis: the ACCESS proposed instrument. ACCESS Research Group. A case control etiologic study of sarcoidosis. *Sarcoidosis Vasc. Diffuse Lung Dis.* 1999; 16: 75-86.
34. Judson MA. A proposed solution to the clinical assessment of sarcoidosis: The sarcoidosis three-dimensional assessment instrument (STAI). *Med. Hypotheses* 2007; 68: 1080-1087.
35. Statement on sarcoidosis. Joint of the American Thoracic Society (ATS), the European Respiratory Society (ERS) and World Association of Sarcoidosis and other Granulomatous Disorders (WASOG) adopted by the ATS Board of Directors and by the ERS Executive Committee, February 1999. *Am. J. Respir. Crit. Care Med.* 1999; 160: 736-755.
36. Teirstein AS, Machac J, Almeida O, Lu P, Padilla ML, Iannuzzi MC. Results of 188 whole-body fluorodeoxyglucose positron emission tomography scans in 137 patients with sarcoidosis. *Chest* 2007; 132: 1949-1953.
37. Vignaux O, Dhote R, Duboc D, Blanche P, Dusser D, Weber S, Legmann P. Clinical significance of myocardial magnetic resonance abnormalities in patients with sarcoidosis: a 1-year follow-up study. *Chest* 2002; 122: 1895-1901.
38. Suzuki T, Kanda T, Kubota S, Imai S, Murata K. Holter monitoring as a noninvasive indicator of cardiac involvement of sarcoidosis. *Chest* 1994; 106: 1021-1024.
39. Cooper LT, Baughman KL, Feldman AM, Frustci A, Jessup M, Kuhl U, Levine GN, Narula J, Starling RC, Towbin J, Virmani R. The role of endomyocardial biopsy in the management of cardiovascular disease: a scientific statement from the American College of Cardiology and the European Society of Cardiology Endorsed by the Heart Failure Society of America and Heart Failure Association of the European Society of Cardiology. *J. Am. Coll. Cardiol.* 2007; 50: 1914-1931.
40. Curimbaba J, Rodrigues SCS, Moreira JM, Silva LAA, Pereira CAC, Pimenta J. Avaliação eletrofisiológica cardíaca em pacientes com sarcoidose. *Arq. Bras. Cardiol.* 2011; 96: 266-271.
41. Yodogawa K, Seino Y, Ohara T, Takayama H, Kobayashi Y, Katoh T, Takano T. Non-invasive detection of latent cardiac conduction abnormalities in patients with pulmonary sarcoidosis. Application of signal averaged electrocardiogram. *Circ. Jap.* 2007; 71: 540-545.
42. Uyarel H, Uslu N, Okmen E, Tartan Z, Kasikcioglu H, Dayi SU, Cam N. QT dispersion in sarcoidosis. *Chest* 2005; 128: 2619-2625.
43. Gibbons WJ, Levy RD, Nava S, Malcolm I, Marin JM, Tardif C, Magder S, Lisbona R, Cosio MG. Subclinical cardiac dysfunction in sarcoidosis. *Chest* 1991; 100: 44-50.
44. Uslu N, Akyol A, Gorgulu S, Eren M, Ocakli B, Celik S, Yildirim A, Aksu H, Nurkalem Z. Heart rate variability in patients with systemic sarcoidosis. *Ann. Noninvas. Electrocardiol.* 2006; 11: 38-42.
45. Chapelon-Abric C, de Zuttere D, Duhaut P, Veysier P, Wechsler B, Huong DT, Gennes C, Papo T, Ble'try O, Godeau P, Piette JC. Cardiac sarcoidosis: a retrospective study of 41 cases. *Medicine (Baltimore)* 2004; 83: 315-334.
46. Baughman RP, Ohmichi M, Lower EE. Combination therapy for sarcoidosis. *Sarcoidosis Vasc. Diffuse Lung Dis.* 2001; 18: 133-137.
47. Baughman RP, Costabel U, du Bois RM. Treatment of sarcoidosis. *Clin. Chest Med.* 2008; 29: 533-548.
48. Baughman RP, on behalf of the Sarcoidosis Investigators. Infliximab therapy in patients with chronic sarcoidosis and pulmonary involvement. *Am. J. Respir. Crit. Care Med.* 2006; 174: 795-802.
49. Winters SL, Cohen M, Greenberg S, Stein B, Curwin J, Pe E, Gomes JA. Sustained ventricular tachycardia associated with sarcoidosis: assessment of the underlying cardiac anatomy and the prospective utility of programmed ventricular stimulation, drug therapy and an implantable antitachycardia device. *J. Am. Coll. Cardiol.* 1991; 18: 937-943.
50. Epstein AE, DiMarco JP, Ellenbogen KA, Estes NAM III, Freedman RA, Gettes LS, Gillinov AM, Gregoratos G, Hammill SC, Hayes DL, Hlatky MA, Newby LK, Page RL, Schoenfeld MH, Silka MJ, Stevenson LW, Sweeney MO. ACC/AHA/HRS 2008 guidelines for device-based therapy of cardiac rhythm abnormalities: executive summary: a report of the American College of Cardiology/American Heart Association Task Force on Practice Guidelines (Writing Committee to Revise the ACC/AHA/NASPE 2002 Guideline Update for Implantation of Cardiac Pacemakers and Antiarrhythmia Devices). *Circulation* 2008; 117: 2820-2840.
51. Koplán BA, Soejima K, Baughman K, Epstein LM, Stevenson WG. Refractory ventricular tachycardia secondary to cardiac sarcoid: electrophysiologic characteristics, mapping, and ablation. *Heart Rhythm* 2006; 3: 924-929.
52. Stees CS, Khoo MSC, Lowery CM, Sauer WH. Ventricular tachycardia storm successfully treated with immunosuppression and catheter ablation in a patient with cardiac sarcoidosis. *J. Cardiovasc. Electrophysiol.* 2011; 22: 210-213.

53. Yager JEE, Hernandez AF, Steenbergen C, Persing B, Russel SD, Milano C. Recurrence of cardiac sarcoidosis in a heart transplant recipient. *J. Heart Lung Transplant.* 2005; 24: 1988-1990.

54. Zaidi AR, Zaidi A, Vaitkus PT. Outcome of heart transplantation in patients with sarcoid cardiomyopathy. *J. Heart Lung*

Transplant. 2007; 26: 714-717.

55. Oni AA, Hershberger RE, Norman DJ, Hovaguimian H, Cobanoglu AM, Hosenpud JD. Recurrence of sarcoidosis in a cardiac allograft: control with augmented corticosteroids. *J. Heart Lung Transplant.* 1992; 11: 367-369.