JAFIB
Featured Review
Journal of Atrial Fibrillation


www. jafib.com

# Treating Atrial Fibrillation With Cryoballoon Technology

**David R. Altmann, MD, Sven Knecht, PhD, Christian Sticherling, MD, Peter Ammann, MD, Beat Schaer, MD, Stefan Osswald, MD, Michael Kühne, MD.**

Division of Cardiology, University of Basel Hospital, Switzerland

## Abstract

Cryoballoon ablation has emerged as a novel tool to perform pulmonary vein isolation. The aim of this paper is to review the advantages, drawbacks as well as possible complications and clinical outcomes of this technology and to discuss some important technical issues.

## Introduction

Catheter ablation for atrial fibrillation (AF) has become the mainstay of interventional treatment of AF and primarily aims at the elimination of AF triggers, which are myocardial muscle extensions ("sleeves") covering the outside of the pulmonary veins (PV).[1-3] AF ablation has been mainly performed with the use of radiofrequency (RF) energy creating continuous circumferential lesions by point-by-point ablation. Given the difficulties associated with creating contiguous curvilinear lesions with focal ablation, this technique is challenging and highly dependent on operator dexterity. Therefore, efforts have been directed towards the development of balloon-based systems potentially offering a simpler and less operator dependent means of achieving PV isolation (PVI) by creating a continuous circumferential lesion set with a limited number of energy applications. While such a balloon-based system using cryothermal energy – the cryoballoon (Arctic Front, Medtronic, Minneapolis, MN) – has been commercially used in Europe since 2005, it has only recently received Food and Drug Administration (FDA) approval for the treatment of paroxysmal AF in the United States based on the STOP-AF trial (Sustained Treatment of Paroxysmal Atrial Fibrillation).[4]

Apart from the efficacy of a novel treatment modality, it is of importance to determine its safety in order to determine the risk-to-benefit profile of a specific procedure. "New" intervention related complications were identified since the beginning of AF ablation using RF energy, such as development of PV stenosis or atrio-esophageal fistula. Although complication rates of cryoballoon ablation of AF have been reported to be similar when compared to radiofrequency ablation (RFA), specific energy and device related complications are probable.[5,6]

The aim of this article is to review the role of cryoballoon ablation in patients with paroxysmal AF with an emphasis on practical technical aspects, but also limitations and pitfalls based on our clinical experience.

### Theoretical Considerations

The basics of cryotherapy on the cellular level have been described in detail.[7] Briefly, cell in-

**Corresponding Address** : Michael Kühne, MD, University Hospital Basel, Division of Cardiology, Petersgraben 4, 4031 Basel, Switzerland.

jury due to cryoenergy application is determined by direct cell injury and vascular stasis. The key for irreversible tissue injury is the tissue temperature. At a tissue temperature of -20 °C, ice crystals grow, cells shrink, and membranes and cell constitutions are damaged. Intracellular ice formation occurs at temperatures of -40 °C. With the current cryoballoon system, tissue temperature cannot be measured directly. The cryoconsole monitors the inner balloon temperature from a sensor located in the proximal part of the balloon. Temperature is determined by the overall heat transferred from the myocardium and the surrounding blood. The heat transfer from blood is highly dependent on the blood flow around the balloon. The higher the blood flow, the higher is the amount of heat transferred and consequently the higher the measured inner cryoballoon temperature. Since the surface area of the balloon surrounded by blood is much bigger than the surface area in contact with the tissue, the inner balloon temperature is mainly determined by this convective heating. The influence of the balloon surface area on its temperature can easily be seen when comparing the superior with the inferior PVs or the big and small cryoballoon. Since the small balloon with a diameter of 23-mm has only approximately two thirds of the surface area of a 28-mm balloon, the measured inner cryoballoon temperatures are much lower than for the big balloon.[8,9]

Dependent on how the cryoballoon fits into the PV antrum and consequently on the ratio of the cryoballoon surface in contact with the myocardial tissue compared to the area surrounded by blood, the measured temperature is higher or lower. Therefore, temperature measurements during cryoballoon ablation can be used as a surrogate of the contact area with tissue, but should not be used as a measure of the balloon surface temperature or even tissue temperature.

Due to the design of the nitrous oxide injection into the cryoballoon, the temperature is not homogeneous at the balloon surface. As seen in figure 1, there are 4 cold spots with ice formation on the cryoballoon surface where the jets of nitrous oxide hit the surface. For maximal cooling of the myocardium, the ideal contact with the tissue is at this distal one third of the cryoballoon surface area. Based on these theoretical considerations, central alignment of the cryoballoon with the PV prior to freezing and a 45 degree rotation of the cryoballoon for the second freezing cycle may play a key role to achieve maximal heat transfer from the tissue and consequently create permanent lesions.

## Technical Aspects

"Single-shot" techniques for PVI are generally thought to be less dependent on operator dexterity. The cryoballoon produces a large circular ablation zone and is potentially less direction dependent and more stable, as the balloon freezes to the tissue compared to other balloon based ablation technologies. Studies reporting on operator learning curves describe rapidly decreasing procedure- and fluoroscopy times, as well as numbers of energy applications needed to achieve PVI.[5,10] Electrophysiologists performing cryoballoon ablations often have ample experience with left atrial ablations and therefore might have a steep learning curve. However, this might be different if cryoballoon ablation is performed by cardiologists with no or limited experience with left atrial procedures.

The cryoballoon is a relatively stiff device requiring a 15 Fr outer diameter deflectable sheath (FlexCath, Medtronic), and even though the problem of creating a continuous lesion with focal RFA may be overcome with the cryoballoon, operator skills in addition to knowledge of the left atrial anatomy are certainly needed to safely maneuver the device.

Because of the large caliber sheath required for the cryoballoon, proper vascular access is important. At our institution, cryoballoon ablation is usually performed with a three-catheter approach via the right femoral vein using the 28-mm cryoballoon only. In addition to the cryoballoon, a coronary sinus catheter is used as a reference and for pacing a long with a circumferential mapping catheter. While ablating the right PVs one needs to be cautious not to damage the right phrenic nerve. As discussed later in this paper, the latter can be monitored by phrenic nerve pacing from the superior vena cava during cryoballoon ablation. In order to enhance catheter stability in the superior vena cava, we commonly use the coronary sinus catheter for phrenic nerve stimulation instead of an additional non-deflectable catheter.

**Figure 1:** Cooled cryoballoon

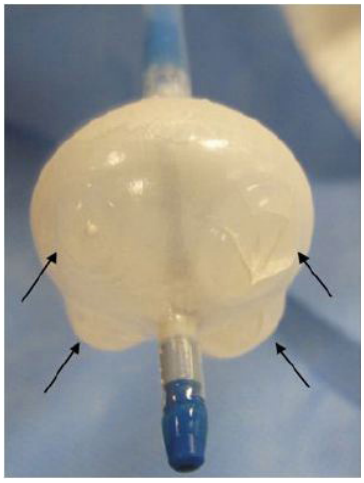

**Legend:** Inflated and cooled cryoballoon. The circular ice-formation can be seen at the anterior one third of the surface (arrows).

Access to the left atrium (LA) is gained by performing transseptal puncture. We usually perform two separate transseptal punctures for the cryoballoon and the circumferential mapping catheter because of concerns of persistence of iatrogenic atrial septal defect with passage of two catheters through a single puncture, especially when using a large sheath as required for the cryoballoon.[11] A novel spiral catheter designed for the insertion through the cryoballoon serving as a guidewire and allowing real-time monitoring of PV potentials during cryoablation has been proposed recently and has the potential to overcome the need for a double transseptal puncture. The possibilities and pitfalls of this "through-the-balloon" circumferential mapping catheter will be discussed below. Anticoagulation is initiated with unfractionated heparin with administration of a loading dose directly after transseptal puncture. Measurement of the activated clotting time is repeated every 30 minutes with more frequent initial measurements and the heparin dose is adjusted in order to achieve a target activated clotting time of 350 seconds.

The cryoballoon catheter should be advanced over the wire into the LA in order to prevent inadvertent collateral damage from the relatively stiff tip of the catheter. However, the stiff J-tipped guidewire also needs to be placed with caution since a guidewire-associated dissection of the right inferior pulmonary vein has been described.[12] Once the guidewire is in the targeted vein, the balloon is inflated and positioned against the wall. Central alignment of the sheath should be attained. Contrast injection through the lumen of the catheter into the PV is then performed. In case of good tissue contact along the whole periphery of the balloon, the injected contrast is entrapped in the vein and no para-balloon leaking can be visualized. The catheter is then flushed with saline injection through the balloon catheter and the freezing cycle may be initiated with a standard duration of 5 minutes. We commonly perform two applications (10 minutes of cryoenergy) per PV before inserting the spiral catheter to check for PVI. If PVI cannot be achieved using the cryoballoon alone, we switch to a conventional focal RF catheter. The number of freezing cycles after which a switch to RF is made varies between published studies.[13-15] We used to perform up to six applications (30 minutes of cryoenergy) if a PV could not be isolated before switching to RF. We now commonly switch to RF after 3 failed isolation attempts.

If PV occlusion is not achieved, special techniques can be applied. Placing the guidewire in different PV branches by deflecting the sheath and the catheter may result in better occlusion and may also correct the central alignment. An inferior gap can frequently be closed with the "pull-down" technique. Freezing is started at the superior PV circumference followed by a gentle pull-down maneuver resulting in better central alignment of the sheath and thus better tissue contact at the

**Figure 2:** "Modified hockey-stick" method resulting in central alignment of the cryoballoon during ablation at the left inferior PV (LAO projection)

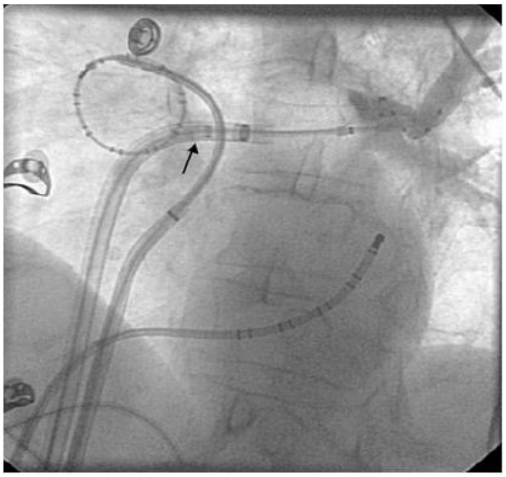

**Legend:** The cryoballoon sheath (arrow) is low in the left atrium and the balloon catheter advanced in the direction of the PV with a slight upward deflection. The cryoballoon is inflated and contrast dye injection through the cryoballoon catheter into the left inferior PV demonstrates complete PV occlusion. A circumferential spiral mapping as well as the "through-the-balloon" circumferential mapping catheter and the coronary sinus catheter are shown.

inferior circumference.[15] This is especially helpful with ablation at the right inferior PV. The "hockey-stick" technique is a further strategy that has been described for early branching inferior PV to allow balloon-tissue contact at the inferior PV circumference. After placement of the guidewire in the early branching inferior PV the sheath is advanced with maximal bend to the superior-posterior LA. This technique was reported to allow the balloon to be pushed onto the inferior circumference of the PV ostium.[15] However, we experienced incomplete PV occlusion in a relevant number of cases with this technique and commonly use a "modified hockey-stick" technique for the left inferior PV. We keep the sheath low in the LA and the balloon catheter is advanced in the direction of the PV with a slight upward deflection (Figure 2). The ipsilateral PVs may share common fascicles and thus cryoenergy application at the inferior PV may result in isolation of the superior PV, or vice versa, a phenomenon named "cross-talk". Thus an isolation attempt at the inferior PV is advisable even if complete isolation of the superior PV has not been achieved after two freezing cycles, especially when remaining PV potentials are visible at the inferior circumference of the superior PV.[15,16]

The lack of real-time monitoring of PV potentials during cryoballoon ablation is a limitation of this technique. A novel spiral mapping catheter (Achieve, Medtronic) that can be inserted through the lumen of the cryoballoon catheter has recently received FDA approval. In addition, it may obviate the need for the separate circular mapping catheter and thus the second transseptal puncture. This "through-the-balloon" circumferential mapping catheter is available in two fixed diameters (15mm and 20mm). To date, no study investigated whether PVs can be isolated using the novel spiral catheter alone and how reliable it is in confirming complete PVI. With the current design of the cryoballoon, it is our experience that the spiral mapping catheter is frequently positioned too deep in the PV resulting in inadequate signal quality. However, if real-time monitoring of PV potentials can be performed, the time needed to isolate the vein has been demonstrated to predict sustained PVI using the Promap catheter (Prorhythm Inc., Ronkonkoma, NY). This makes monitoring of PV signals during the freezing cycle an attractive tool because unsuccessful freezes can be aborted early.[17] Figure 3 shows real-time PVI of the left inferior PV during cryoablation with the 28-mm balloon using the "through-the-balloon" circumferential mapping catheter.

## Acute Pulmonary Vein Isolation

Andrade et al. systematically reviewed 23 articles

**Figure 3:** Real-time pulmonary vein potential during cryoballoon ablation recorded by the "through-the-balloon" circumferential mapping catheter

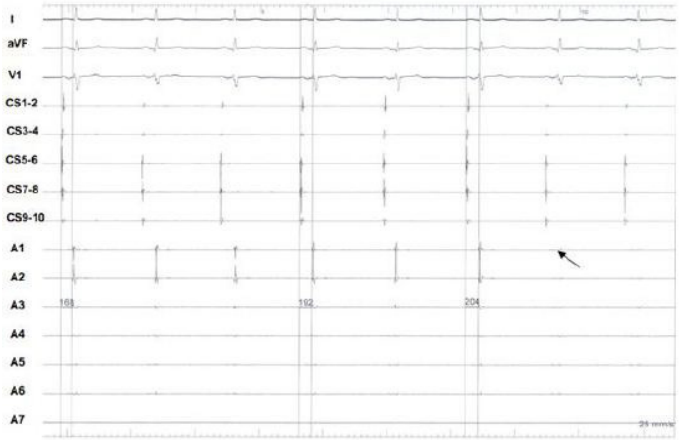


**Legend:** Legend: Progressive delay of the PV potential seen on the "through-the-balloon" circumferential mapping catheter measured from on the onset of the atrial signal on the coronary sinus (CS) catheter to the PV potential onset in milliseconds and subsequent PVI (arrow) after 42 seconds of cryoballoon ablation (-43 °C). Surface ECG (I, aVF, V1) is shown on the top.

using cryoballoon for AF ablation to define its efficacy and safety.[5] Acute PVI was achieved in 98.81% of patients (n = 924) and in 98.47% of targeted veins (n = 3,803). Complete PVI in studies using the cryoballoon alone was achieved in 77.81% of patients and in 92.64% of targeted veins compared to concomitant use of focal ablation, either with cryo- or RF energy. Procedure- and fluoroscopy times are significantly longer if a catheter switch is necessary.[10,16,18] In our comparative study treating paroxysmal AF patients using the 28-mm cryoballoon, a switch to a focal ablation catheter was required in 28% of cases to achieve complete PVI.[13] Similar acute PVI rates are reported by Van Belle et al. (84%) using both the 23-mm, and 28-mm cryoballoon,[10] while others report a significantly lower success rate of only 40%.[14] Chun et al. and Klein et al. were able to isolate 98% and 95% of all PVs, respectively.[15,19] However, in order to achieve an acute PVI rate of 98%, up to 45 minutes of cryoenergy on a single PV, and up to 65 minutes in case of the presence of a left common PV was necessary.[15] We commonly use an irrigated tip RF catheter for "touch-up" ablations but a focal cryoablation catheter is available (Freezor Cardiac CryoAblation Catheter, Medtronic).

To achieve complete PVI using the cryoballoon solely, continuous balloon-tissue contact is necessary. Due to individual anatomy this may be challenging and special techniques may be required, especially at regions of enhanced muscular thickness, such as the left atrial appendage-left PV ridge or inferior segments of the PV, where PV reconduction occurs more frequently.[13,20] Excessive force in order to achieve complete PV occlusion should probably be avoided for safety reasons, but distortion of the non-compliant balloon may still be seen occasionally. Figure 4 demonstrates a distorted cryoballoon due to push towards the left inferior PV in order to achieve complete PV occlusion. In some patients, PV anatomy may preclude optimal balloon positioning, such as an oval shape of the PV, a common ostium or angulated vein insertions.[21] Therefore studies defining anatomical variations not suitable for cryoballoon ablation are warranted. Exchanging catheters in the LA is associated with longer procedure times and carries the potential risk of embolic complications, especially with the large diameter sheaths used with cryoballoon ablation. Therefore, very careful handling of sheaths and catheters is required.

Cryoballoon temperature is monitored continuously during cryoballoon ablation by a thermocouple in the proximal inner balloon and is affected by balloon occlusion of the treated PV because remaining blood flow has a rewarming effect. This can be seen during cryoablation when performing a pull-down maneuver to close a remaining gap at the inferior PV circumference.[15] In case of complete PV oc-

**Figure 4:** Distorted cryoballoon in order to achieve complete PV occlusion (LAO projection)

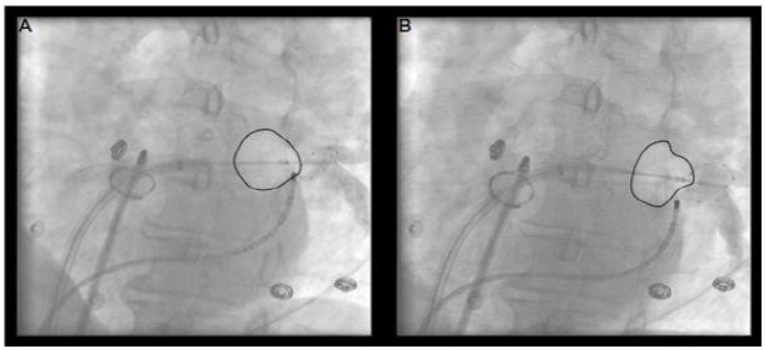


**Legend:** Panel A demonstrates the inflated cryoballoon (continuous line) placed at the left inferior PV with incomplete PV occlusion. Panel B: Complete PV occlusion was achieved after advancing the cryoballoon further. Due to anatomical reasons the cryoballoon was distorted but PVI was achieved after one freezing cycle.The circular mapping catheter, the coronary sinus catheter and the "through-the-balloon" spiral mapping catheter inside the PV are shown.

clusion following this maneuver a further temperature drop is frequently observed. Although temperature measurement by the thermocouple does not reflect true tissue temperature achieved during cryoablation ablation, several data suggest a relationship between balloon temperature and acute PVI. In an animal model, the success rate for chronic PVI was higher in the absence of peri-balloon flow leak as evaluated by intracardiac echocardiography and with lower balloon temperatures.[22] However, effective balloon temperatures were below -80 °C, which is not seen in human cryoballoon ablation procedures. In the study by Klein et al. using both the 23-mm and 28-mm balloon, minimal temperatures were similar in the superior or inferior and right or left PVs with a trend for higher minimal temperature in the right inferior PV.[19] The authors report high acute PVI success rate of 95% with a mean minimal temperature below -50 °C during cryoablation, except for the right inferior PV (-49 °C) but the authors provide no data on temperature association with acute PVI success. In the study by Linhart et al. acute success rate was 81% of targeted PVs and the temperature achieved during cryoballoon ablation with either the 23-mm or 28-mm balloon, was not as low as compared to the study by Klein et. al. (-44.6 °C).[18] Acute PVI has been demonstrated to be associated with lower balloon temperature achieved during cryoballoon ablation.[14] A balloon temperature below -51 °C has been shown to be associated with successful acute PVI and balloon temperatures ≥ -36 °C for superior or ≥ -33 °C for inferior PVs 120 seconds after initiating the freezing cycle predicted failed PVI. Thus, balloon temperature may be used to discriminate between successful and failed PVI at various time points during the freezing cycle.[8] However, the same authors report PV conduction recovery during a redo procedure and retrospectively analyzed the minimal balloon temperature achieved during cryoballoon ablation using the 28-mm balloon. The differences in minimal temperatures in those with successful long-term PVI compared to those with recovery of conduction were small and statistically significant for the right superior PV only.[20]

## Long-term Outcome

Reported success rates 12 months after cryoballoon ablation of paroxysmal AF, defined as freedom from AF without antiarrhythmic drug therapy vary between 59% and 89%.[12,14-16,19,21,23,24] Patient selection and follow-up differ significantly between studies and may, at least in part, explain the variable success rates.

In the systematic literature review by Andrade et al. 1-year freedom from AF recurrence after 3 months blanking period was 72.83% (95% CI 68.79-76.62%), including studies that included patients with persistent AF. To date, no randomized trial compared AF ablation with RF energy and cryoballoon. Non-randomized studies comparing cryoballoon with RFA of paroxysmal AF have reported on similar success rates between the groups.[13,14,18]

The only randomized study, the STOP-AF trial

performed in patients with paroxysmal AF and previously failed antiarrhythmic drug treatment, compared cryoballoon ablation with antiarrhythmic drug therapy and demonstrated a significantly greater treatment success (69.9% vs. 7.3% freedom of AF) and an improvement of quality of life at 12 months in the cryoballoon ablation group.[4] It has to be mentioned, that the STOP-AF trial defined acute procedural success rate as an isolation of ≥3 PVs, a definition not previously used in AF ablation trials. In addition, 19% of patients in the interventional arm underwent a redo procedure with the cryoballoon during the 3-months blanking period.

Pulmonary vein reconnections in patients with recurrent AF following cryoablation undergoing a redo procedure were found in 2.7±0.4 veins per patients.[5] Although the right inferior PV is generally thought to be challenging in terms of complete acute PVI because of anatomical reasons, electrical reconnection for left-sided PVs was demonstrated more frequently.

Reconduction has been demonstrated to occur most often at inferior locations and the anterior aspect of the left atrial appendage (LAA)-PV junction ("ridge") after cryoballoon ablation with the 28-mm cryoballoon.[13,20] The PV reconnection site at the inferior circumference seems to be associated with cryoballoon ablation, while following RFA no specific PV reconnection pattern is found, with the exception of the ridge between the LAA and the left superior PV.[13] The reason for the inferior location of PV reconnection may be due to the cranial sheath orientation, resulting in good tissue contact at the superior aspect of the PVs. In contrast to superior PVs where the sheath and the cryoballoon are relatively easily aligned with the PV and the catheter can be pushed towards the PV ostium, complete PV occlusion with inferior PVs are more difficult to achieve. Cryolesions achieved with poor balloon-tissue contact may acutely lead to PVI while being prone to later conduction recovery. Due to the orientation of the refrigerant jets, the deepest temperature at the balloon surface is achieved just in front of the equator. Therefore, despite good occlusion and low temperatures lesions may be inadequate due to a lack of central alignment of the balloon.[20]

PV reconnection is regarded as the most common reason for recurrence in patients with paroxysmal AF after catheter ablation. At our institute, we use RF for repeat procedures in patients with recurrent AF after cryoballoon ablation. The rationale for this approach is that the predilection sites for conduction gaps are likely to apply for the second procedure as well because they are likely due to anatomical factors. This might explain the observation of RFA being more efficient compared to cryoballoon for repeat procedures.[20,24] In addition, PV reisolation with RF energy in conjunction with electroanatomical mapping systems can be achieved with low radiation exposure.

## Complications Associated with Cryoablation

Complication rates in patients undergoing RFA have been extensively investigated and were reported in 3.5% to 6% of patients.[6,25] These include vascular access complications (1.1-1.9%), cardiac tamponade (1.2-1.3%), thromboembolic event (0.2-0.4%), and very rarely atrio-esophageal fistula (0.2%), PV stenosis (<0.01%) or death (0.2%). Complication rates with cryoballoon have been less intensively investigated, but have been reported to be similar compared to RFA.[5] Importantly, the cryoballoon trials included patients during the early learning curve of some operators and therefore there may be potential for complication rates to decrease with increasing operator experience.[10,12,19]

## Vascular Access Complications

Complication rates related to the vascular access site including haemorrhage, iatrogenic arterial pseudoaneurysm or arteriovenous fistula formation during cryoablation seem to be slightly higher compared to RFA of AF with an incidence of 1.79% vs. 1.2%.[2,25,26] The cryoballoon sheath has a larger outer diameter compared to sheaths used during RFA and therefore special attention has to be paid on the adequate puncture technique.

## Phrenic Nerve Palsy

With a reported incidence of 2.8% to 13.5% phrenic nerve palsy (PNP) is the most frequent complication of cryoballoon ablation.[5,23,24] Owing to the proximity of the right-sided PVs to the right phrenic nerve. PNP occurs during cryo-

ablation of the right-sided PVs, in particular the right superior PV but PNP during ablation of the right inferior PV has been reported.[14] The use of a 23-mm balloon is significantly more often associated with PNP compared to the 28-mm balloon (12.4% vs. 3.5%, p=0.0001).[5] Presumably, although not investigated systematically, the explanation is the more distal ablation site within the PV with the smaller balloon that minimizes the distance between the balloon and the phrenic nerve. In addition, cryoablation deep within the PV might enhance cold transfer due to less convective heating of the balloon by atrial blood flow.[22] Luckily, most PNPs are transient and resolve within 14 months[14,23,24] with an incidence of PNP of only 0.37% persisting beyond 1 year.[5] However, the morbidity of PNP is considerable.

Different measures to avoid PNP have been proposed. Because of the higher incidence of PNP with the 23-mm diameter balloon, caution has to be advised with the smaller balloon size. Phrenic nerve stimulation at a cycle length of 1000 ms during cryoablation of both the right superior and inferior PVs is performed at our institution. Phrenic nerve capture is confirmed by fluoroscopy and manual confirmation before initiation of the freezing cycle and capture should then be assured throughout the freezing cycle by continuous palpation of the abdomen. One member of the electrophysiology laboratory personnel is standing next to the refrigeration console (CryoConsole, Medtronic) and immediate discontinuation of the freezing cycle in case of loss of phrenic nerve capture or decrease of diaphragmatic contraction is mandatory. Importantly, phrenic nerve damage may be missed if stimulation is performed distal to the potential site of injury. We therefore aim to achieve a stable catheter position in the superior vena cava superior, and demonstration of consistent phrenic nerve capture before initiating the freezing cycle may help to avoid over-diagnosing PNP. To enhance catheter stability, we commonly use the deflectable coronary sinus catheter instead of an additional catheter placed in the superior vena cava (Figure 5). At our institution, AF ablation procedures are performed in conscious sedation and adapting the level of sedation may improve the tolerability of phrenic nerve pacing. PNP has been reported to occur with the larger balloon also. In addition, early termination of cryoenergy application with loss of phrenic nerve capture did not prevent the subsequent occurrence of PNP, including cases of persistent PNP.[10,15,21,23] However, it may be that recovery of phrenic nerve function is due to early termination of the freezing cycle in case of loss of phrenic nerve capture. A small series of cryoballoon ablation using only the 28-mm balloon reported unintentional cryothermal energy application inside the PV with subsequent PNP in patients with large right sided PV ostia. The authors propose calculating the ratio between PV diameter and balloon size and do not advise cryoballoon ablation in patients with a ratio of ≥0.93. In the same series, the balloon pressure decreased during freezing in 1/27 patient with subsequent more distal balloon position inside the right superior PV and transient PNP.[15]

From a practical standpoint, it may be advisable to perform ablation of the RIPV first because PNP appears to be exceedingly rare during ablation of the inferior vein. The rationale behind this approach is that if PNP occurs during cryoballoon ablation at the RSPV and the RIPV is not isolated yet, cryoballoon ablation at the RIPV cannot be performed safely because phrenic nerve function cannot be monitored unless recovery of phrenic nerve function is immediate.

## Pulmonary Vein Stenosis

PV stenosis is a complication, associated with catheter ablation of AF using RF energy as a result of energy application inside PVs. Due to differences in the definition of PV stenosis and the rate of screening for this complication reported incidences vary widely from 0% to 38% and the true incidence might be underestimated, as screening for asymptomatic PV stenosis is not performed routinely.[27-29] Although the precise pathophysiological mechanism is unclear, a progressive vascular reaction leading to replacement of necrotic myocardium by collagen is the most plausible mechanism.[30] In contrast to the beginning of AF ablation in the late 1990´s when investigators were not aware of this potential complication, consensus exists today, that avoiding RF energy delivery within a PV can prevent PV stenosis.[25,31]

PV stenosis has been considered very rare following cryoballoon ablation but concerns rose after presentation of the STOP-AF trial and the first re-

**Figure 5:** Catheter setting and phrenic nerve stimulation during cryoballoon ablation of the right superior pulmonary vein (LAO projection)

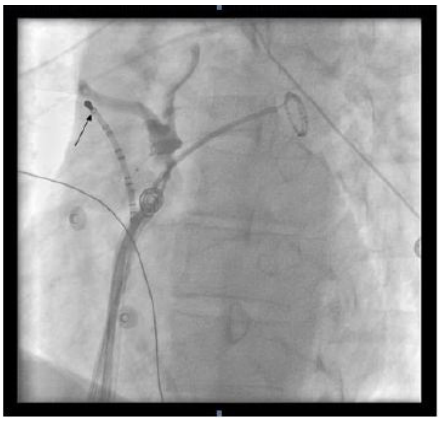

**Legend:** The inflated cryoballoon is advanced to the PV ostium of the right superior PV. Contrast injection through the cryoballoon catheter distally to the cryoballoon confirms complete PV occlusion. The coronary sinus catheter (arrow) is placed at the postero-lateral superior vena cava where phrenic nerve stimulation is performed during the freezing cycle. The proximity of the right superior PV branch and the phrenic nerve is shown. The circular mapping catheter is placed in the left superior PV.

ported PV stenosis.[4] In 9 studies using systematic non-invasive imaging screening for PV stenosis between 1 and 12 months following cryoballoon ablation (773 procedures) the incidence of PV stenosis was 0.90% (7/773).[5] Of note, all cases were observed in the STOP-AF trial, which observed 7 PV stenoses in 228 patients (10/927 PV), resulting in an incidence of 3%. However, STOP-AF used a >75% reduction in cross-sectional area from baseline to define PV stenosis, which corresponds to a 50% reduction of PV diameter. In studies using standard definition based on reduction of the PV diameter >75%, the incidence of PV stenosis was 0%. Thus the reported incidence by the STOP-AF trial may overestimate the real incidence of relevant PV stenosis following cryoballoon ablation due to a more "cautious" definition of PV stenosis.

Reassuringly, the incidence of significant PV stenosis resulting in symptoms or requiring intervention seems to be lower (0.17%) compared to AF ablation with RF energy.[5] However, underestimation of the PV diameter and thus energy application within the PV makes PV stenosis using cryoballoon conceivable.

## Left Atrial Tachychardia and Flutter

Left atrial tachycardia following RFA of AF is relatively common.[32] This is especially true for patients with persistent AF, who are likely to receive additional linear lesions in the LA, which enhance the likelihood of gaps and thus drive the probability for the occurrence of left atrial tachycardia.[33] The problem of left atrial tachycardia has been described in 0.8% to 1.7% of patients after cryoballoon ablation.[10,23] This low rate of left atrial tachycardia may be due to the fact that the lesion sets with cryoballoon ablation are circumferential and relatively close to PVs.

## Injury of Adjacent Structures

No cases of atrio-esophageal fistula have been reported in AF ablation procedures with the cryoballoon. Three studies comprising 116 participants systematically performed upper endoscopy following cryoballoon.[34-36] In one study, esophageal ulceration was reported in 6/35 patients,[34] whereas two other studies demonstrated no esophageal lesion in 38 and 43 patients, respectively.[35,36] Luminal esophageal temperature has been showed to decrease during cryoablation, even to subzero temperatures, especially when applying cryothermal energy in the inferior PVs.[36] However, given the relatively small number of patients treated so far in published trials or case series, it may be too early to conclude whether atrio-esophageal fistula formation is of concern following cryoballoon ablation.

Recently, bronchial erosion following cryoballoon ablation with a 23-mm balloon deep inside the left inferior PV and a maximal temperature of -64°C was reported. The patient presented with haemoptysis 4 days after the procedure and thoracic computer tomography imaging revealed no abnormalities. Bronchoscopy showed erosion with blood effusion on the ventral side at the division of the left superior and inferior bronchus, which was located close to the left inferior PV on a computer tomography scan.[37] Van Belle et al. report on 2/57 (3.5%) patients, who presented with haemoptysis that occurred within the first month following the procedure. The authors ruled out PV stenosis with a multislice computer tomography scan but bronchoscopy to exclude bronchial lesion formation was not performed and symptoms did not recur after temporary cessation of anticoagulant therapy.[10]

Consequently, following cryoballoon ablation of AF, a high level of vigilance must be maintained because of potential injury of surrounding anatomical structures if patients present with haemoptysis or unspecific symptoms, such as swallowing discomfort, recurrent neurological events, fever and chills, suggestive for bronchial or esophageal injury, respectively.

## Thromboembolic Events

Cerebrovascular events associated with the ablation procedure are the most serious complications of RFA of AF with an incidence of 1 to 5% at the beginning of the AF ablation era.[2,32] Ischemic brain injury was the third most frequent cause of death in a large worldwide retrospective case series of AF ablation with RF over a broad spectrum of electrophysiology laboratories from 1995 to 2005.[38]

Improvements of the RF ablation technique, including the use of irrigated tip catheters and a more aggressive procedural anticoagulation regimen have decreased the incidence of stroke to ≤0.5% as demonstrated in recent prospective studies.[25,26,39] Comparing the incidence of cerebral microembolic signals in 30 patients during AF ablation using RF 4-mm conventional non-irrigated, 4-mm irrigated tip catheter and the cryoballoon, Sauren et al. found significantly less microembolic signals in the middle cerebral arteries in procedures performed with the cryoballoon and irrigated tip catheter (non-irrigated vs. irrigated-tip vs. cryoballoon: 3,908 ± 2816 vs. 935 ± 463 and 1,404 ± 981).[40] Gaita et al. comparing AF ablation with the cryoballoon, irrigated tip and a multielectrode RF catheter report similarly favorable findings for irrigated tip RF catheters and the cryoballoon regarding silent thromboembolic lesions documented on post-procedural magnetic resonance imaging.[41] A recently published multicenter study prospectively compared the post-procedural incidence of new embolic lesion seen in a magnetic resonance imaging study after AF ablation using conventional irrigated-tip, cryoballoon or a novel multielectrode duty-cycled RF catheter.[42] In the group treated with the multielectrode RF catheter ablation there was a notably higher incidence of subclinical cerebral embolic events (37.5%), while the event rate was lower but not statistically different in the conventional irrigated-tip and cryoballoon catheter group (irrigated-tip vs. cryoballoon: 7.4% vs. 4.3%; p=0.4).

In animal models ablation with the cryoballoon has been shown to reduce thrombus formation compared to RF energy, probably by producing a more homogenous lesion and by keeping the endothelium intact.[43-45] A systematic review of cryoballoon ablation by Andrade et al. reported a similar incidence of thromboembolic complications of 0.57%, including periprocedural stroke, transient ischemic attack, or myocardial infarction.[5] Of note, the reported myocardial infarctions were related to air embolism because of bubbles inside the sheath. All of the reported periprocedural myocardial infarctions resolved during the procedure without long-term sequelae.[23] The larger outer diameter of the sheath used for cryoballoon ablation compared to sheaths routinely used during RFA might be more prone to air embolism, and thus flushing of the sheath before transseptal puncture and continuous flushing during the procedure is recommended.

Based on the currently available evidence, cryoballoon ablation compares favourably to RF ablation with regards to the risk of systemic embolism associated with AF ablation procedures.

## Limitations of Cryoballoon

Balloon based ablation systems are of limited

flexibility. In patients with additional arrhythmias, such as typical isthmus-dependent atrial flutter or persistent AF, who may require linear or focal lesions, we do not use the cryoballoon. Because of this, a relevant number of patients are not considered for cryoballoon ablation at our institution.[16] Of note, the cryoballoon is only approved for ablation of paroxysmal AF in the United States.

Complete PVI depends on adequate tissue contact and individual anatomical variants, for example the presence of a common trunk can make cryoballoon ablation challenging in some patients. A typical PV branching pattern based on the Venice Chart definition[32] (2 left and 2 right PVs) was found to be present in 40% of AF patients only.[46] 31% of patients presented with a common left trunk with an average value of maximal diameter of 33 mm in those with paroxysmal AF. Cryoballoon ablation with the large balloon would inevitably result in energy application deep in the PV in such cases, which should be avoided. An alternative approach would be to ablate at different arcs of the periphery at an antral level of a common trunk. However, this technique is not successful in our experience. Thus, although pre-procedural imaging of the LA and PVs is not required for cryoballoon ablation, we routinely perform magnetic resonance imaging or computer tomography in order to obtain anatomical information before the procedure and have recently started not to consider patients for cryoballoon ablation if relevant anatomical variants are found on pre-procedural imaging. In addition, if PVI cannot be achieved with the cryoballoon, additional costs are generated with the inevitable use of an additional catheter. We use an irrigated tip RF catheter for creating such "touch-up" lesions.

Another limitation is that circumferential tissue contact is demonstrated by contrast injection into the PV, which may result in the use of a considerable amount of contrast medium, making this technique problematic in patients with decreased renal function. Alternative modalities to demonstrate adequate tissue contact, such as assessment of the pressure curve obtained at the tip of the catheter or colour Doppler during transoesophageal echocardiography to document PV occlusion have not been widely adopted.[47,48]

## Conclusions

To achieve acute PVI during cryoballoon ablation, complete occlusion of the PV with the balloon and thus good balloon-tissue contact is important. This can be confirmed by contrast injection into the PV. Although the position of the temperature probe in the back of the balloon provides only a rough estimate of tissue temperatures, a rapid temperature decrease and minimal temperatures ≤ -50 °C are indicative for a good tissue contact. In case of PV occlusion failure, special techniques, such as the pull-down maneuver may help to achieve complete PV occlusion during the freezing cycle. If the temperature decrease is insufficient, abortion of the freezing cycle should be considered.

Modifications of the current balloon cooling and of temperature measurement technology in order to lower balloon temperature and to obtain real tissue temperature during the freezing cycle might improve the acute success rate of this technique.
In conclusion, the cryoballoon is a novel technology for PVI and is mainly suitable for patients with paroxysmal AF. However, randomized comparisons to radiofrequency catheter ablation are lacking.

## References

1. Haissaguerre M, Jais P, Shah DC, Takahashi A, Hocini M, Quiniou G, Garrigue S, Le Mouroux A, Le Metayer P, Clementy J. Spontaneous initiation of atrial fibrillation by ectopic beats originating in the pulmonary veins. N Engl J Med 1998; 339: 659-666.
2. Cappato R, Calkins H, Chen SA, Davies W, Iesaka Y, Kalman J, Kim YH, Klein G, Packer D, Skanes A. Worldwide survey on the methods, efficacy, and safety of catheter ablation for human atrial fibrillation. Circulation 2005; 111: 1100-1105.
3. Calkins H, Brugada J, Packer DL, Cappato R, Chen SA, Crijns HJ, Damiano RJJ, Davies DW, Haines DE, Haissaguerre M, Iesaka Y, Jackman W, Jais P, Kottkamp H, Kuck KH, Lindsay BD, Marchlinski FE, McCarthy PM, Mont JL, Morady F, Nademanee K, Natale A, Pappone C, Prystowsky E, Raviele A, Ruskin JN, Shemin RJ. HRS/EHRA/

ECAS expert Consensus Statement on catheter and surgical ablation of atrial fibrillation: recommendations for personnel, policy, procedures and follow-up. A report of the Heart Rhythm Society (HRS) Task Force on catheter and surgical ablation of atrial fibrillation. Heart Rhythm 2007; 4: 816-861.
4. Packer D, Irwin JM, J C. Cryoballoon ablation of pulmonary veins for paroxysmal atrial fibrillation: first results of the North American Arctic Front STOP-AF pivotal trial. J Am Coll Cardiol 2010; 55: E3015-3016.
5. Andrade JG, Khairy P, Guerra PG, Deyell MW, Rivard L, Macle L, Thibault B, Talajic M, Roy D, Dubuc M. Efficacy and safety of cryoballoon ablation for atrial fibrillation: a systematic review of published studies. Heart Rhythm 2011; 8: 1444-1451.
6. Baman TS, Jongnarangsin K, Chugh A, Suwanagool A, Guiot A, Madenci A, Walsh S, Ilg KJ, Gupta SK, Latchamsetty R, Bagwe S, Myles JD, Crawford T, Good E, Bogun F, Pelosi FJ, Morady F, Oral H. Prevalence and predictors of complications of radiofrequency catheter ablation for atrial fibrillation. J Cardiovasc Electrophysiol 2011; 22: 626-631.
7. Gage AA, Baust J. Mechanisms of tissue injury in cryosurgery. Cryobiology 1998; 37: 171-186.
8. Furnkranz A, Koster I, Chun KR, Metzner A, Mathew S, Konstantinidou M, Ouyang F, Kuck KH. Cryoballoon temperature predicts acute pulmonary vein isolation. Heart Rhythm 2011; 8: 821-825.
9. Nadji G, Hermida JS, Kubala M, Quenum S, Mouquet V, Traulle S, Leborgne L, Jarry G. Dual balloon size strategy for cryoisolation of the pulmonary veins in patients with atrial fibrillation: comparison of 23 and 28mm diameter cryoballoons. Arch Cardiovasc Dis 2011; 104: 70-76.
10. Van Belle Y, Janse P, Rivero-Ayerza MJ, Thornton AS, Jessurun ER, Theuns D, Jordaens L. Pulmonary vein isolation using an occluding cryoballoon for circumferential ablation: feasibility, complications, and short-term outcome. Eur Heart J 2007; 28: 2231-2237.
11. Hammerstingl C, Lickfett L, Jeong KM, Troatz C, Wedekind JA, Tiemann K, Luderitz B, Lewalter T. Persistence of iatrogenic atrial septal defect after pulmonary vein isolation--an underestimated risk? Am Heart J 2006; 152: 362.e1-362.e5.
12. Chan NY, Choy CC, Lau CL, Lo YK, Chu PS, Yuen HC, Mok NS, Tsui PT, Lau ST. Initial experience of cryoballoon catheter ablation for atrial fibrillation in Hong Kong. Hong Kong Med J 2011; 17: 386-390.
13. Kuhne M, Suter Y, Altmann D, Ammann P, Schaer B, Osswald S, Sticherling C. Cryoballoon versus radiofrequency catheter ablation of paroxysmal atrial fibrillation: biomarkers of myocardial injury, recurrence rates, and pulmonary vein reconnection patterns. Heart Rhythm 2010; 7: 1770-1776.
14. Kojodjojo P, O'Neill MD, Lim PB, Malcolm-Lawes L, Whinnett ZI, Salukhe TV, Linton NW, Lefroy D, Mason A, Wright I, Peters NS, Kanagaratnam P, Davies DW. Pulmonary venous isolation by antral ablation with a large cryoballoon for treatment of paroxysmal and persistent atrial fibrillation: medium-term outcomes and non-randomised comparison with pulmonary venous isolation by radiofrequency ablation. Heart 2010; 96: 1379-1384.
15. Chun KR, Schmidt B, Metzner A, Tilz R, Zerm T, Koster I, Furnkranz A, Koektuerk B, Konstantinidou M, Antz M, Ouyang F, Kuck KH. The 'single big cryoballoon' technique for acute pulmonary vein isolation in patients with paroxysmal atrial fibrillation: a prospective observational single centre study. Eur Heart J 2009; 30: 699-709.
16. Kuhne M, Schaer B, Ammann P, Suter Y, Osswald S, Sticherling C. Cryoballoon ablation for pulmonary vein isolation in patients with paroxysmal atrial fibrillation. Swiss Med Wkly 2010; 140: 214-221.
17. Chun KR, Furnkranz A, Metzner A, Schmidt B, Tilz R, Zerm T, Koster I, Nuyens D, Wissner E, Ouyang F, Kuck KH. Cryoballoon pulmonary vein isolation with real-time recordings from the pulmonary veins. J Cardiovasc Electrophysiol 2009; 20: 1203-1210.
18. Linhart M, Bellmann B, Mittmann-Braun E, Schrickel JW, Bitzen A, Andrie R, Yang A, Nickenig G, Lickfett L, Lewalter T. Comparison of cryoballoon and radiofrequency ablation of pulmonary veins in 40 patients with paroxysmal atrial fibrillation: a case-control study. J Cardiovasc Electrophysiol 2009; 20: 1343-1348.
19. Klein G, Oswald H, Gardiwal A, Lusebrink U, Lissel C, Yu H, Drexler H. Efficacy of pulmonary vein isolation by cryoballoon ablation in patients with paroxysmal atrial fibrillation. Heart Rhythm 2008; 5: 802-806.

20. Furnkranz A, Chun KR, Nuyens D, Metzner A, Koster I, Schmidt B, Ouyang F, Kuck KH. Characterization of conduction recovery after pulmonary vein isolation using the "single big cryoballoon" technique. Heart Rhythm 2010; 7: 184-190.
21. Namdar M, Chierchia GB, Westra S, Sorgente A, Meir ML, Bayrak F, Rao JY, Ricciardi D, de Asmundis C, Sarkozy A, Smeets J, Brugada P. Isolating the pulmonary veins as first-line therapy in patients with lone paroxysmal atrial fibrillation using the Cryoballoon. Europace 2011;
22. Sarabanda AV, Bunch TJ, Johnson SB, Mahapatra S, Milton MA, Leite LR, Bruce GK, Packer DL. Efficacy and safety of circumferential pulmonary vein isolation using a novel cryothermal balloon ablation system. J Am Coll Cardiol 2005; 46: 1902-1912.
23. Neumann T, Vogt J, Schumacher B, Dorszewski A, Kuniss M, Neuser H, Kurzidim K, Berkowitsch A, Koller M, Heintze J, Scholz U, Wetzel U, Schneider MA, Horstkotte D, Hamm CW, Pitschner HF. Circumferential pulmonary vein isolation with the cryoballoon technique results from a prospective 3-center study. J Am Coll Cardiol 2008; 52: 273-278.
24. Van Belle Y, Janse P, Theuns D, Szili-Torok T, Jordaens L. One year follow-up after cryoballoon isolation of the pulmonary veins in patients with paroxysmal atrial fibrillation. Europace 2008; 10: 1271-1276.
25. Dagres N, Hindricks G, Kottkamp H, Sommer P, Gaspar T, Bode K, Arya A, Husser D, Rallidis LS, Kremastinos DT, Piorkowski C. Complications of atrial fibrillation ablation in a high-volume center in 1,000 procedures: still cause for concern? J Cardiovasc Electrophysiol 2009; 20: 1014-1019.
26. Bertaglia E, Zoppo F, Tondo C, Colella A, Mantovan R, Senatore G, Bottoni N, Carreras G, Coro L, Turco P, Mantica M, Stabile G. Early complications of pulmonary vein catheter ablation for atrial fibrillation: a multicenter prospective registry on procedural safety. Heart Rhythm 2007; 4: 1265-1271.
27. Lee G, Sparks PB, Morton JB, Kistler PM, Vohra JK, Medi C, Rosso R, Teh A, Halloran K, Kalman JM. Low Risk of Major Complications Associated With Pulmonary Vein Antral Isolation for Atrial Fibrillation: Results of 500 Consecutive Ablation Procedures in Patients With Low Prevalence of Structural Heart Disease From a Single Center. J Cardiovasc Electrophysiol 2010;
28. Dong J, Vasamreddy CR, Jayam V, Dalal D, Dickfeld T, Eldadah Z, Meininger G, Halperin HR, Berger R, Bluemke DA, Calkins H. Incidence and predictors of pulmonary vein stenosis following catheter ablation of atrial fibrillation using the anatomic pulmonary vein ablation approach: results from paired magnetic resonance imaging. J Cardiovasc Electrophysiol 2005; 16: 845-852.
29. Ernst S, Ouyang F, Goya M, Lober F, Schneider C, Hoffmann-Riem M, Schwarz S, Hornig K, Muller KM, Antz M, Kaukel E, Kugler C, Kuck KH. Total pulmonary vein occlusion as a consequence of catheter ablation for atrial fibrillation mimicking primary lung disease. J Cardiovasc Electrophysiol 2003; 14: 366-370.
30. Taylor GW, Kay GN, Zheng X, Bishop S, Ideker RE. Pathological effects of extensive radiofrequency energy applications in the pulmonary veins in dogs. Circulation 2000; 101: 1736-1742.
31. Altmann D, Hindricks G, Arya A, Piorkowski C, Gaspar T, Eitel C, Sommer P. Management of patients pre-, per- and postcatheter ablation procedures: how to minimize complications? Minerva Cardioangiol 2011; 59: 171-186.
32. Natale A, Raviele A, Arentz T, Calkins H, Chen SA, Haissaguerre M, Hindricks G, Ho Y, Kuck KH, Marchlinski F, Napolitano C, Packer D, Pappone C, Prystowsky EN, Schilling R, Shah D, Themistoclakis S, Verma A. Venice Chart international consensus document on atrial fibrillation ablation. J Cardiovasc Electrophysiol 2007; 18: 560-580.
33. Willems S, Klemm H, Rostock T, Brandstrup B, Ventura R, Steven D, Risius T, Lutomsky B, Meinertz T. Substrate modification combined with pulmonary vein isolation improves outcome of catheter ablation in patients with persistent atrial fibrillation: a prospective randomized comparison. Eur Heart J 2006; 27: 2871-2878.
34. Ahmed H, Neuzil P, d'Avila A, Cha YM, Laragy M, Mares K, Brugge WR, Forcione DG, Ruskin JN, Packer DL, Reddy VY. The esophageal effects of cryoenergy during cryoablation for atrial fibrillation. Heart Rhythm 2009; 6: 962-969.
35. Schmidt M, Daccarett M, Marschang H, Ritscher G, Turschner O, Brachmann J, Rittger H. Intracardiac echocardiography improves procedural efficiency during cryoballoon ablation for atrial fibrillation: a pilot study. J Cardiovasc Electrophysiol 2010; 21: 1202-1207.

36. Furnkranz A, Chun KR, Metzner A, Nuyens D, Schmidt B, Burchard A, Tilz R, Ouyang F, Kuck KH. Esophageal endoscopy results after pulmonary vein isolation using the single big cryoballoon technique. J Cardiovasc Electrophysiol 2010; 21: 869-874.
37. van Opstal JM, Timmermans C, Blaauw Y, Pison L. Bronchial erosion and hemoptysis after pulmonary vein isolation by cryoballoon ablation. Heart Rhythm 2011; 8: 1459.
38. Cappato R, Calkins H, Chen SA, Davies W, Iesaka Y, Kalman J, Kim YH, Klein G, Natale A, Packer D, Skanes A. Prevalence and causes of fatal outcome in catheter ablation of atrial fibrillation. J Am Coll Cardiol 2009; 53: 1798-1803.
39. Ren JF, Marchlinski FE, Callans DJ, Gerstenfeld EP, Dixit S, Lin D, Nayak HM, Hsia HH. Increased intensity of anticoagulation may reduce risk of thrombus during atrial fibrillation ablation procedures in patients with spontaneous echo contrast. J Cardiovasc Electrophysiol 2005; 16: 474-477.
40. Sauren LD, VAN Belle Y, DE Roy L, Pison L, LA Meir M, VAN DERVFH, Crijns HJ, Jordaens L, Mess WH, Maessen JG. Transcranial measurement of cerebral microembolic signals during endocardial pulmonary vein isolation: comparison of three different ablation techniques. J Cardiovasc Electrophysiol 2009; 20: 1102-1107.
41. Gaita F, Leclercq JF, Schumacher B, Scaglione M, Toso E, Halimi F, Schade A, Froehner S, Ziegler V, Sergi D, Cesarani F, Blandino A. Incidence of silent cerebral thromboembolic lesions after atrial fibrillation ablation may change according to technology used: comparison of irrigated radiofrequency, multipolar nonirrigated catheter and cryoballoon. J Cardiovasc Electrophysiol 2011; 22: 961-968.
42. Herrera Siklody C, Deneke T, Hocini M, Lehrmann H, Shin DI, Miyazaki S, Henschke S, Fluegel P, Schiebeling-Romer J, Bansmann PM, Bourdias T, Dousset V, Haissaguerre M, Arentz T. Incidence of asymptomatic intracranial embolic events after pulmonary vein isolation: comparison of different atrial fibrillation ablation technologies in a multicenter study. J Am Coll Cardiol 2011; 58: 681-688.
43. Rodriguez LM, Leunissen J, Hoekstra A, Korteling BJ, Smeets JL, Timmermans C, Vos M, Daemen M, Wellens HJ. Transvenous cold mapping and cryoablation of the AV node in dogs: observations of chronic lesions and comparison to those obtained using radiofrequency ablation. J Cardiovasc Electrophysiol 1998; 9: 1055-1061.
44. Wetstein L, Mark R, Kaplan A, Mitamura H, Sauermelch C, Michelson EL. Nonarrhythmogenicity of therapeutic cryothermic lesions of the myocardium. J Surg Res 1985; 39: 543-554.
45. Khairy P, Chauvet P, Lehmann J, Lambert J, Macle L, Tanguay JF, Sirois MG, Santoianni D, Dubuc M. Lower incidence of thrombus formation with cryoenergy versus radiofrequency catheter ablation. Circulation 2003; 107: 2045-2050.
46. Anselmino M, Blandino A, Beninati S, Rovera C, Boffano C, Belletti M, Caponi D, Scaglione M, Cesarani F, Gaita F. Morphologic analysis of left atrial anatomy by magnetic resonance angiography in patients with atrial fibrillation: a large single center experience. J Cardiovasc Electrophysiol 2011; 22: 1-7.
47. Siklody CH, Minners J, Allgeier M, Allgeier HJ, Jander N, Weber R, Schiebeling-Romer J, Neumann FJ, Kalusche D, Arentz T. Cryoballoon pulmonary vein isolation guided by transesophageal echocardiography: novel aspects on an emerging ablation technique. J Cardiovasc Electrophysiol 2009; 20: 1197-1202.
48. Siklody CH, Minners J, Allgeier M, Allgeier HJ, Jander N, Keyl C, Weber R, Schiebeling-Romer J, Kalusche D, Arentz T. Pressure-guided cryoballoon isolation of the pulmonary veins for the treatment of paroxysmal atrial fibrillation. J Cardiovasc Electrophysiol 2010; 21: 120-125.