

## Determining esophageal anatomy with a new electroanatomical mapping system

Diego Chemello MD, Imad Hameedullah BSc RCVT, Anandaraja Subramanian MD, Eugene Downar MD FRCPC.

Division of Cardiology, University Health Network, Toronto, Canada.

### Case description

A 53-year-old woman with symptomatic paroxysmal atrial fibrillation was referred for pulmonary vein isolation (PVI). After obtaining access to left atrium (LA) and placement of catheters by standard technique, a high-resolution electroanatomical map of the LA and the pulmonary veins (PVs) was constructed using a map catheter (EZ Steer® Bi-directional catheter, Biosense Webster, Inc. Diamond Bar, USA) and the Carto® 3 System (Biosense-Webster Inc. Diamond Bar, USA) in the Fast Anatomical Mapping (FAM) mode.

Before ablation was begun, the patient swallowed 20 mL of barium sulphate cream (E-Z-Paste, E-ZEM Canada Inc., Westbury, New York). While the cream defined the anatomical location of the esophagus during anteroposterior fluoroscopy [Figure 1A], a series of points were added to the electroanatomical map, corresponding to the esophageal margins. This technique allowed us to define the position of the esophagus relative to the posterior LA and PVs. Pulmonary vein isolation was then performed with application of radiofrequency energy (RF) around the PV ostia [Figure 1B]. In the posterior aspect of the LA, RF energy application was not delivered in areas where esophageal margins were previously defined [Figure 1C]. All the four pulmonary veins were successfully isolated and patient did not experience any short or long term complications

during follow up.

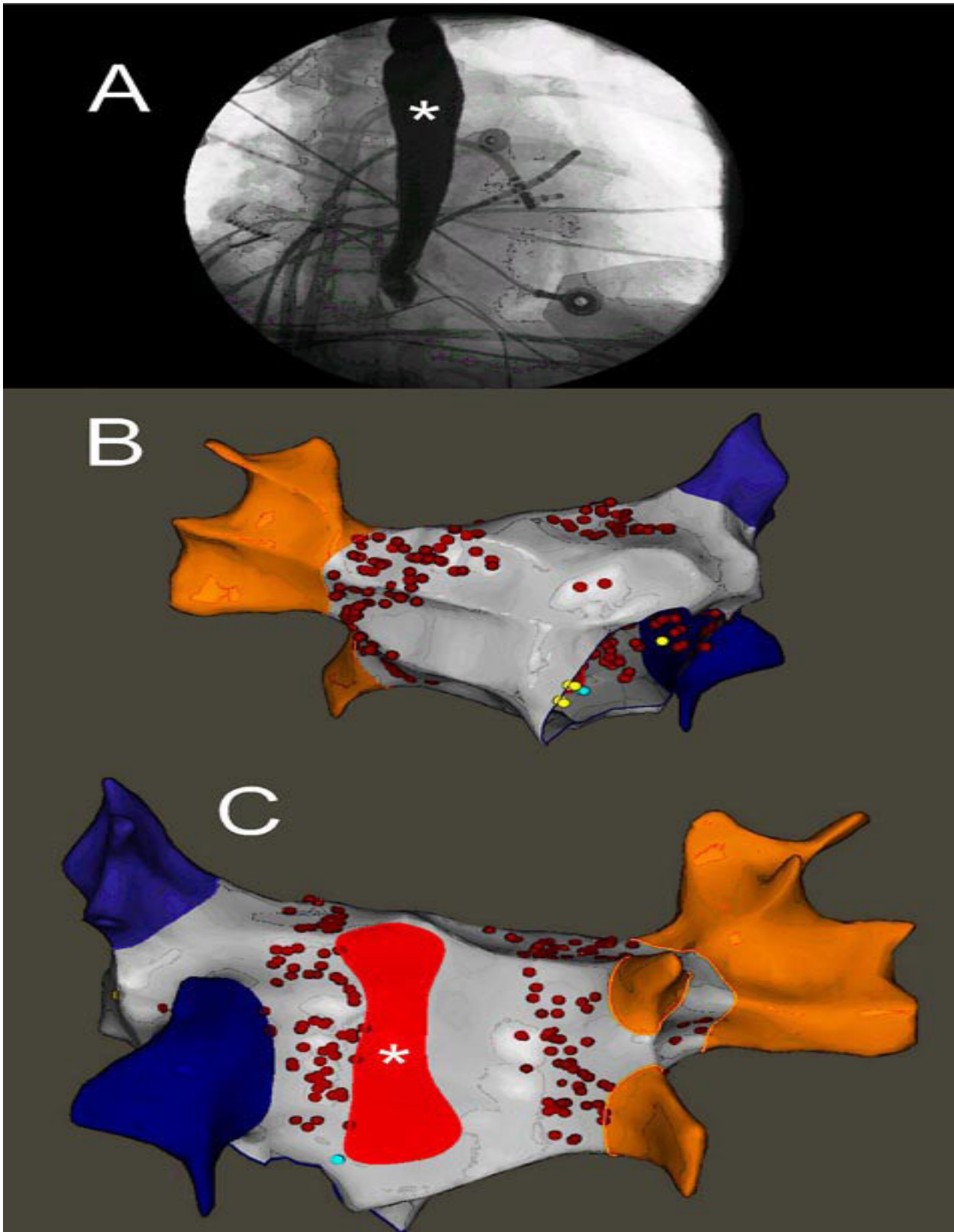
### Discussion

Atrial-esophageal fistula is a rare (0.03% to 0.5%), but serious complication of pulmonary vein isolation and it carries a very high mortality rate.<sup>1</sup> It is thought to occur due to conductive heat transfer to the esophagus that causes transmural tissue necrosis, mediastinitis and fistulous connection between the esophageal lumen and the left atrium. This can lead to sepsis and stroke.<sup>2</sup>

Strategies to limit or avoid RF energy application closer to the esophagus require an accurate location of this structure relative to the LA. Over the past decades several techniques have been developed in order to better understand the anatomic relationship between the posterior LA and the esophagus. Methods to localize the esophagus during RF energy delivery (real-time imaging techniques) are the preferred method, since some studies have shown the esophageal position is dynamic during ablation procedures. Contrast-enhanced computed tomography and magnetic resonance imaging have been used.<sup>3, 4</sup> However, these procedures are expensive, time consuming and do not allow real-time image acquisition during RF ablation. The use of intracardiac ultrasound or the insertion of a multipolar catheter in the esophagus are good options. However, these techniques are expensive and sometimes necessi-

**Corresponding Address** : Eugene Downar, 150 Gerrard Street West. Gerrard Wing, 3-552 , Toronto General Hospital, Toronto, ON. M5G 2C4.

**Figure 1 :** (A) Fluoroscopic image in of the esophagus (\*) in anteroposterior projection after barium swallowing. (B) Electro-anatomical map in anteroposterior view showing the right (orange) and left (blue) pulmonary veins; the gray area represents the left atial chamber; the red dots mark areas where radiofrequency ablation was applied. (C) Electroanatomical map in posteroanterior view showing the esophagus projection as determined by fluoroscopy and its relation with the posterior left atrial wall. The other colors represent the same as in B.



tate the use of general anesthesia.<sup>2</sup> Contrary to the other techniques, barium swallow is inexpensive and practical. Dynamic changes in the esophageal position during ablation can be easily verified and integrated into the electroanatomical map because most patients have residual barium staining in the esophagus. Otherwise, additional swallows of barium cream during the procedure can be performed, since patient is under conscious sedation. The main concern of barium swallow is its aspiration to respiratory tract leading to pneumonitis. However, this risk is very small and can be readily identified by fluoroscopy.<sup>5</sup>

The present case demonstrates the integration of barium swallowing with the Carto 3 electroanatomical map as a promising technique to minimize esophageal damage during atrial fibrillation catheter ablation.

## References

1. Cappato R, Calkins H, Chen SA, Davies W, Iesaka Y, Kalman J, Kim YH, Klein G, Natale A, Packer D, Skanes A. Prevalence and causes of fatal outcome in catheter ablation of atrial fibrillation. *J Am Coll Cardiol* 2009;53:1798-1803.
2. Bahnson TD. Strategies to minimize the risk of esophageal injury during catheter ablation for atrial fibrillation. *Pacing Clin Electrophysiol* 2009;32:248-260.
3. Sra J, Narayan G, Krum D, Akhtar M. Registration of 3d computed tomographic images with interventional systems: Implications for catheter ablation of atrial fibrillation. *J Interv Card Electrophysiol* 2006;16:141-148.
4. Bertaglia E, Brandolino G, Zoppo F, Zerbo F, Pascotto P. Integration of three-dimensional left atrial magnetic resonance images into a real-time electroanatomic mapping system: Validation of a registration method. *Pacing Clin Electrophysiol* 2008;31:273-282.
5. Good E, Oral H, Lemola K, Han J, Tamirisa K, Iqbal P, Elmouchi D, Tschopp D, Reich S, Chugh A, Bogun F, Pelosi F, Jr., Morady F. Movement of the esophagus during left atrial catheter ablation for atrial fibrillation. *J Am Coll Cardiol* 2005;46:2107-2110.