JAFIB®

Case Report

Journal of Atrial Fibrillation

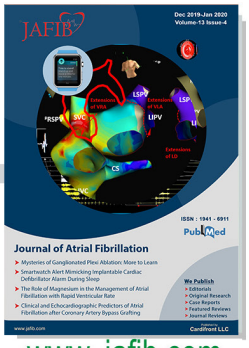

www. jafib.com

Comparison of Fragmented Electrogram Based Strategy and High Frequency Stimulation for Detection of Ganglionated Plexi

Tolga Aksu[1], Erkan Baysal[2], DhanunjayaLakkireddy[3], KivancYalin[4], Rakesh Gopinathannair[3]

[1]University of Health Sciences, KocaeliDerince Training and Research Hospital, Department of Cardiology, Kocaeli, Turkey

[2]University of Health Sciences, Gazi Yaşargil Training and Research Hospital, Department of Cardiology, Diyarbakır, Turkey

[3]Kansas City Heart Rhythm Institute and Research Foundation, Overland Park, KS

[4]Istanbul University-Cerrahpasa, Faculty of Medicine, Department of Cardiology, Istanbul, Turkey

Abstract

Ganglionated plexus (GP) ablation is an emerging technique in patients with cardioinhibitory vasovagal syncope and vagally mediated atrial fibrillation. Localization of GPs can be impacted by the technique used. A reproduciblemethodology for GP detectionis needed to account for individual variations during electrophysiologic study.In this article, we aim to compare and contrast high-frequency stimulation vs. a fragmented electrogram guided strategy for GP localization.

Introduction

As the most common form of syncope, vasovagal syncope (VVS) is caused by intermittent impairment of cardiovascular reflexes eliciting sympathetic withdrawal-mediated hypotension and/or parasympathetic hyperactivity-based bradycardia.1Those who have recurrent VVS with a predominant cardioinhibitory response can benefit from cardiac pacing. However, alternative therapies that avoid pacing is desirable in this predominantly young population.[1,2] Similarly, the autonomicnervoussystem (ANS) plays an important role in both initiation and maintainance of atrial fibrillation (AF).[3] Structurally, the ANS of any visceral organ is represented by a complex neural plexus formed by extrinsic and intrinsic parts.[4] According to previous reports, large numbers of neurons of the intrinsic cardiac ANS are associated with ganglionated plexuses (GPs) in human atrial tissue.5In recent years, catheter based GP ablation has emerged as a promising therapy, when compared with pharmacological therapies, for VVS and vagallymediated AF.[6] Because the full extent of the distribution of GPs in the human heart remain insufficiently known, reasonable GP detection methods are needed to account individual variation during electrophysiologic study. Herein, we aimed to discuss potential role of 2 previously used GP localization techniques.

Key Words

Ablation, Bradycardia, Syncope, Atrial Fibrillation

Corresponding Author

Tolga Aksu, MD, Associate Professor of Cardiology

University of Health Sciences, KocaeliDerince Education and Research Hospital, Department of Cardiology, Kocaeli, Turkey, Zip code: 41500

Case report

A 27-year-old female was referred for recurrent cardioinhibitory type vasovagal syncope and paroxysmal AF episodes. The frequency of syncope episodes was about three per month since the age of 16. The patient reported several AF episodes with vagal triggers such as sleeping and resting. One of those episodes was documented by 12-lead electrocardiography.

We decided to perform ganglionated plexus (GP) ablation. GP sites were detected by using our fractionated electrograms (FEG) based strategy and compared with high-frequency stimulation (HFS) data.[7,8] During HFS (continuous 2-5s at 10V, 20Hz), the sites showing positive vagal response (VR) and inducing AF were indicated with blue and orange dots in the 3D electroanatomic map, respectively (Figure 1).A positive VR was defined as transient ventricular asystole, atrioventricular block, orR-R interval increased by 50%. The response to HFS was reproducible at each site. During baseline electrophysiological study, AA interval was calculated as 976 msec (Figure 2A). Ablation points were selected based on our previously defined FEG based strategy. [4,9] According to FEG based strategy, bipolar electrograms demonstrating greater or equal to four deflections in both atria were tagged and ablated (Figure 2B).[4,9] Fragmented electrograms demonstrated a high consistency with HFS regardless of the response characteristics except on the posterior wall. All fragmented electrograms were ablated. After ablation of GPs, final AA interval decreased to 648 msec (Figure 2B). All positive vagal response sites using HFS were retested. No vagal response was seen with repeat HFSs. There was no further spontaneous AF which had occurred frequently prior to ablation during mapping.

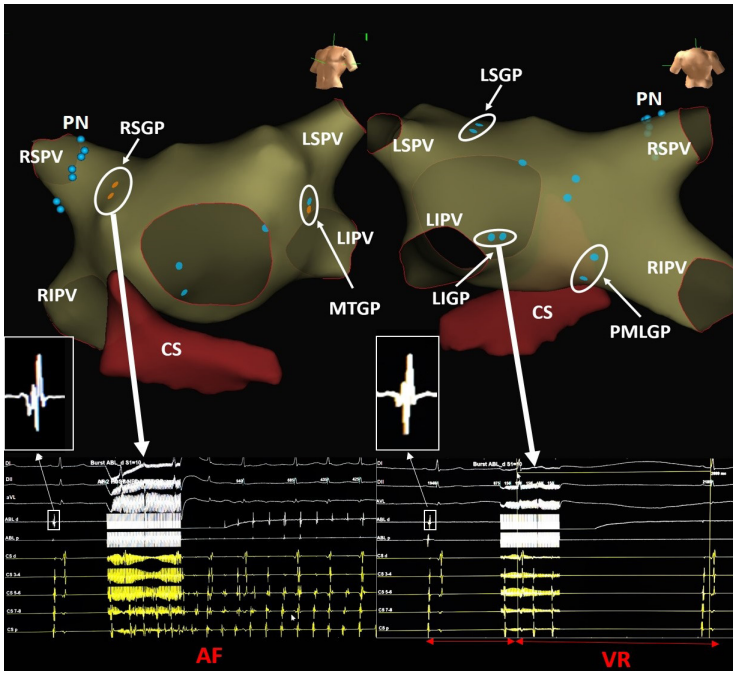

Figure 1: **The schematic view of ganglionated plexuses according to high-frequency stimulation-evoked response characteristics. According to Armour's anatomical definition (ref 4), following 5 major and 1 minor atrial location are consistently identified and called ganglionated plexuses(GPs)**

1) The superior right atrial GP (RSGP) located on the posterior superior surface of the right atrium adjacent to the junction of the superior vena cava (SVC) and right atrium; 2) the superior left atrial GP(LSGP)isidentified on the posteriorsurface of the left atrium between the pulmonary veins; 3) theposterior right atrial GPor the right inferior GP(RIGP)located on the posterior surface ofthe right atrium adjacent to the interatrial groove; 4) theposteromedial left atrial GP(PMLGP) settled on the posterior medial surface of the left atrium; and 5) theinteratrial septal GPconsists of fusion and extensions of theRIGPand theposteromedial left atrial GP (PMLGP).The posterolateral left atrial GP or the left inferior GP (LIGP) isa relatively small atrial GPwhich is identified on the posterior lateralsurface of the left atrial base on the atrial side of theatrioventricular groove. Except for these atrial GPs, theobtuse marginal GP or the Marshall tract GP(MTGP),which is a ventricular GP,located adjacent to the origin of the left obtusemarginal coronary artery. Panels in below demonstrate intracardiac electrograms during high frequency stimulation (HFS). While orange dots demonstrate GPs causing induction of atrial fibrillation (AF), blue dots reveal (+) vagal response sites during HFS. Blue spheres demonstrate the course of the phrenic nerve.

Considering clear vagal nature of AF and younger age of the patient, pulmonary vein isolation was not performed. All pulmonary veins remained electrically connected at the end of the procedure.

Follow-up 72-hour Holter recordings at months 1 and 6 showed no AF recurrence. No syncope was noted.

Discussion

As a definition, a ganglion is a cluster of neuron cell bodies in the peripheral nervous system.The distribution, size, and anatomic relationships of intrinsic cardiac ganglia were studied by Armour et al.[4] They proposed a terminology that identifies cardiac sites with the aim to locate these neural structures for functional studies. Following 5 major and 1 minor atrial locations were consistently identified and called GPs:1) The right superior GP located on the posterior superior surface of the right atrium adjacent to the junction of the superior vena cava and right atrium; 2) the left superior GP is identified on the supero-posterior surface of the left atrium; 3) the right posterior (inferior) GP located on the posterior surface of the right atrium adjacent to the interatrial groove; 4) the posteromedial left atrial GP ison the posterior medial surface of the left atrium; and 5) the interatrial septal GP consists of fusion and extensions of the right inferior GP and the posteromedial left atrial GP. A relatively small atrial GP that was identified on the posterior lateral surface of the left atrial base on the atrial side of the atrioventricular groove has been named the posterolateral left atrial GP (the left inferior GP). However, these ganglia may be very densely packed one over another, their sizes may vary extremely and range from those that are just observable with a microscope to those that are easily discernible with the naked eye.[10] In these ganglia areas, there is a close relation between the atrial myocytes and the cardiac innervation interface due to the incursion of the nervous fibres into the myocardium. This cellular blend causes an electrical heterogeneity resulting in a fragmented electrograms.

Theoretically, HFS application detects GP sites by checking existence of (+) VR which is defined as a significant prolongation of the PR or RR intervals. Thus, in the previous protocols, the places only demonstrating (+) VR during HFS were targeted.[3] However, induction of AF during HFS should also be accepted as a clue for GP because HFS induces AF by causing a shortening of action potential duration, an early afterdepolarization formation, and a triggered firing in the adjacent

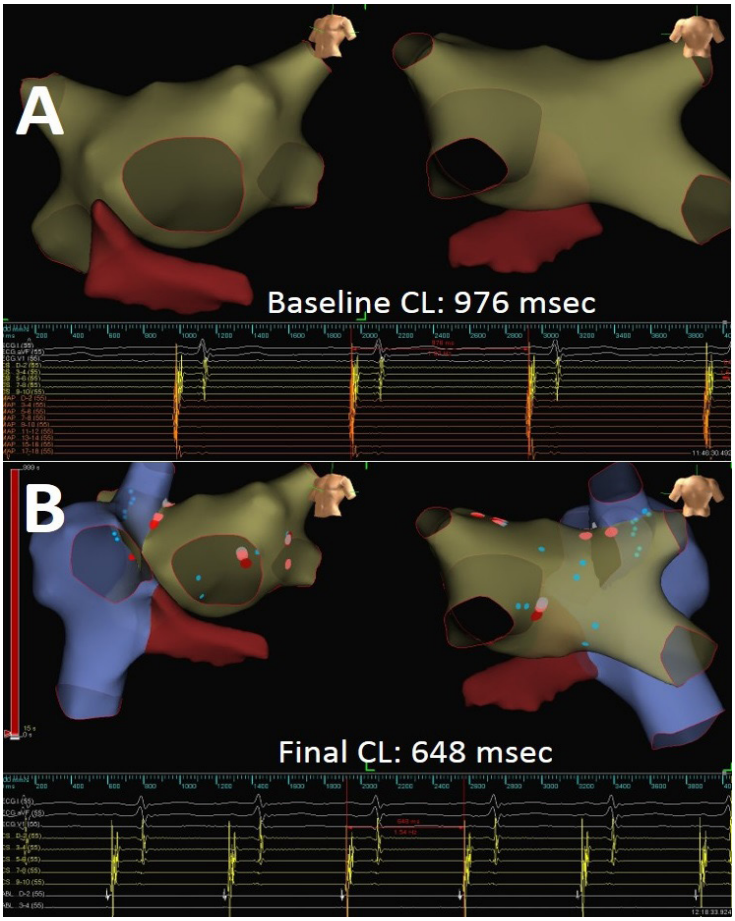

Figure 2: **A. Baseline cycle length of 976 msec is seen at the baseline situation before HFS application and ablation.B. Correlation between locationsof fractionated atrial electrograms andHFS-evoked response sites regardless of the response characteristics is seen except the posterior wall of the left atrium.Pink and red dots demonstrate ablation points based on fragmented electrogram characteristics. Blue dots demonstrate the phrenic nerve.**

CS, coronary sinus; LIPV, the left inferior pulmonary vein; LSPV, the left superior pulmonary vein; RIPV, the right inferior pulmonary vein; RSPV, the right superior pulmonary vein.

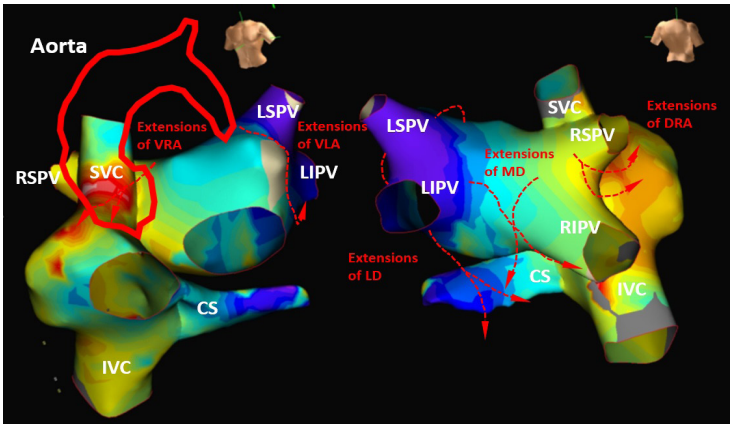

Figure 3: **The schematic view of distribution of ganglionated subplexuses According to Pauza's anatomical definition (ref 10), following 5 atrial location are consistently identified and called ganglionated subplexuses.**

1) The ventral right atrial ganglionated subplexus occupies the following regions: ventral superior right atrial region, ventral side of the root of the superior vena cava, and ventral inferior right atrial region. The postganglionated nerves of this ganglionated subplexus extended mostly into the ventral atrial regions and some of these nerves may innervate the sinoatrial node, as well as penetrate the lower part of the interatrial septum.
2) The ventral left atrial ganglionated subplexus occupies essentially the ventral superior left atrial region. Postganglionated nerves of this ganglionated subplexus may be observed to extend to the ventral inferior left atrial region, where they merged with the postganglionated nerves of the ventral right atrial ganglionated subplexus.
3) The left dorsal ganglionated subplexus distributes across the left coronary sulcus, region of dorsal left coronary sulcus, and middle left atrial region and contains abundant ganglia. The greatest portion of the postganglionated nerves of this ganglionated subplexus passes through the left dorsal coronary sulcus and spread onto the dorsal surface of the left ventricle.
4) The middle dorsal ganglionated subplexus occupies the dorsal superior left atrial region and around the crux cordis. While a part of the postganglionated nerves traverses the coronary sulcus and spreads onto the dorsal surface of both ventricles, part of the nerves passes superficially to the zone of the crux cordis along the coronary sulcus and approaches the postganglionated nerves of the dorsal right atrial ganglionated subplexus.
5) The dorsal right atrial ganglionated subplexus occupies mainly the dorsal superior right atrial region, dorsal side of the root of the superior vena cava, and region over the interatrial septum. The postganglionated nerves of this ganglionated subplexus spread widely into the dorsal and lateral right atrium, including the sinoatrial nodal region and superior surface of the right atrial appendage.

pulmonary vein.[3] This unique phenomenon might be an explanation for conflicting results of previous studies investigating potential role of GP ablation in addition to pulmonary vein isolationusing HFS-evoked VR to define location of GPs.[3]

Duration of HFS may affect the response type because each GP contains both parasympathetic and sympathetic neural fibers; stimulation of the former typically causes an immediate response (within 2–4 seconds), while stimulation of the latter may produce a delayed response (8–10 seconds).[11] Therefore, HFS should be applied at each site for only 2–5 seconds to avoid provoking a sympathetic response that may also induce AF due to sympathetic over-activity or mitigate the parasympathetic response.[9]

In the present case, fractionated potentials were used as primary ablation target. Lellouche et al 9 defined three different endocardial electrograms during sinus rhythm in the patients with paroxysmal AF: normal, low-amplitude fractionated electrograms, and high-amplitude fractionated electrograms. They found that the fractionated pattern was associated with a higher VR during ablation. Then, we retrospectively analyzed our radiofrequency ablation points for electrogram characteristics which were detected by using a combination ofspectral analysis and HFS.[12] All the electrograms on the ablation sites demonstrated either a high or low-amplitude fractionated pattern. Therefore, in our next work, we only targeted fractionated sites to detect GPs.[7] Compared with the previous combined approach strategy, this new FEG based strategy demonstrated shorter procedure and fluoroscopy times and achieved an identical success rate in preventing prodromal symptoms.

What was the cause of positive VR to HFS without fragmented potentials in posterior wall of the left atrium?

Although the terminology of Armour[4] is suggested to provide an overview of the distribution, and the sizes of intrinsic cardiac ganglia, the real number of these ganglia was identified a bit later by Pauza et al 13counting these ganglia on the whole heart preparations. It has been disclosed that the number of ganglia in the human heart varies from heart to heart and ranges from 706 up to 1,560. According to Pauza, staining of intrinsic cardiac neural plexus on the whole (non-sectioned) human heart demonstrated that the heart is under neuronal control through one intrinsic epicardiac neural plexus, nerves of which extend to distinct cardiac regions by five atrial and 2 ventricular pathways (routes) that were named as epicardiac sub plexuses.Since epicardial ganglia are persistently distributed along those subplexal nerves they were termed as ganglionated subplexuses. All five atrial ganglionated subplexuses are densely interconnected by nerves but their ganglionated areas (Figure 3). Despite use of different terminology, the superior and posterolateral left atrial GPs indicated by Armour et al 4 are properly ganglia from the same left dorsal subplexus, as well as that the posteromedial left atrial and posterior descending GPs in Armour et al 4 are only a part of the wide ganglionated field of the middle dorsal subplexus.

We believe that positive VR to HFS demonstrates not only ganglia cluster areas but also demontratesthe postganglionated neural fibers ofganglionated subplexuses. This is why we see (+) VR to HFS in some irrelevant left atrial sites. In contrary, fragmented electrograms may demonstrate cluster of neuron cell bodies. To understand this unique phenomenon, electrophysiologists should keep in mind routes of nerve fibers relatedganglionated subplexuses and potential location of GPs.

In younger patients without structural heart disease, a spectrum of vagal triggers such as VVS, after ingestion of a meal, at night, or during the recovery phase of exercise, can bring about a paroxysm of AF.[13] Further studies are needed to determine whether FEG based GP ablation without pulmonary vein isolation is enough to prevent vagally mediated AF episodes.

References

1. Shen WK, Sheldon RS, Benditt DG, Cohen MI, Forman DE, Goldberger ZD, Grubb BP, Hamdan MH, Krahn AD, Link MS, Olshansky B, Raj SR, Sandhu RK, Sorajja D, Sun BC, Yancy CW. 2017 ACC/AHA/HRS Guidelineforthe Evaluation and Management of PatientsWithSyncope: A Report of theAmericanCollege of Cardiology/AmericanHeartAssociationTask Force on linicalPracticeGuidelinesandtheHeartRhythmSocietyCirculation2017;136:60-122.
2. Varosy PD, Chen LY, Miller AL, Noseworthy PA, Slotwiner DJ, Thiruganasambandamoorthy V. Pacing as a treatmentforReflexmediated (vasovagal, situational, orcarotidsinushypersensitivity) syncope: a systematicreviewforthe 2017 ACC/AHA/HRS Guidelineforthe

Evaluation and Management of PatientsWithSyncope: A Report of theAmericanCollege of Cardiology/ AmericanHeartAssociationTask Force on ClinicalPracticeGuidelinesandtheHeartRhythmSociety. Circulation 2017;136: 123–135.

3. Nakagawa H, Scherlag BJ, Patterson E, Ikeda A, Lockwood D, Jackman WM. Pathophysiologicbasis of autonomicganglionatedplexusablation in patientswithatrialfibrillation. HeartRhythm 2009;6(12 Suppl):S26-S34.
4. Armour JA, Murphy DA, Yuan BX, Macdonald S, Hopkins DA. Gross and microscopic anatomy of the human intrinsic cardiac nervous system. Anat Rec 1997; 247: 289–298.
5. Hanna P, Rajendran PS, Ajijola OA, Vaseghi M, Andrew Armour J, Ardell JL, Shivkumar K.Cardiac neuroanatomy-Imaging nerves to define functional control. AutonNeurosci 2017; 207: 48-58.
6. Aksu T, Güler TE, Mutluer FO, Oto MA. Vagal denervation in atrial fibrillation ablation: A comprehensive review. Anatol J Cardiol2017;18:142-148.
7. Aksu T, Guler TE, Mutluer FO, Bozyel S, Golcuk SE, Yalin K.Electroanatomic-mapping-guided cardioneuroablation versus combined approach for vasovagal syncope: a cross-sectional observational study. J Interv Card Electrophysiol 2019; 54: 177-188.
8. Hu F, Zheng L, Liang E, Ding L, Wu L, Chen G, Fan X, Yao Y. Right anteriorganglionatedplexus: Theprimarytarget of cardioneuroablation?. HeartRhythm 2019; 16: 1545-1551.
9. Lellouche N, Buch E, Celigoj A, Siegerman C, Cesario D, De Diego C,Mahajan A, Boyle NG, Wiener I, Garfinkel A, Shivkumar K. Functional characterization of atrial electrogramsin sinus rhythm delineates sites of parasympathetic innervation inpatients with paroxysmal atrial fibrillation. J Am Coll Cardiol 2007;50:1324–1331.
10. Pauza DH, Pauziene N, Pakeltyte G, Stropus R. Comparative Quantitative Study of the Intrinsic Cardiac Ganglia and Neurons in the Rat, Guinea Pig, Dog and Human as Revealed by Histochemical Staining for Acetylcholinesterase. Ann Anat 2002; 184: 125-36.
11. Po SS, Nakagawa H, Jackman WM. Localization of leftatrialganglionatedplexi in patientswithatrialfibrillation. J CardiovascElectrophysiol 2009;20(10):1186-1189.
12. Aksu T, Golcuk E, Yalin K, Guler TE, Erden I.Simplified Cardioneuroablation in the Treatment of Reflex Syncope, Functional AV Block, and Sinus Node Dysfunction. Pacing Clin Electrophysiol 2016; 39: 42-53.
13. Groh CA, Faulkner M, Getabecha S, Taffe V, Nah G, Sigona K, McCall D, Hills MT, Sciarappa K, Pletcher MJ, Olgin JE, Marcus GM. Patient-reportedtriggers of paroxysmalatrialfibrillation. HeartRhythm 2019;16(7):996-1002.