JAFIB®

Case Report

Journal of Atrial Fibrillation

www. jafib.com

Prolonged Ventricular Dyssynchrony Due to Atrial Fibrillation and Pre-Excitation Syndrome Induced Cardiomyopathy

Mohammad Iqbal[1,2], Oddy Litanto[1], Muhammad Munawar[2], Chaerul Achmad[1], Giky Karwiky[1]

[1]*Department of Cardiology and Vascular Medicine, Universitas Padjadjaran, Jalan Eyckman 38, Bandung 40161, Indonesia .*
[2]*Binawaluya Cardiac Center, Jalan TB Simatupang 71, Jakarta 13750, Indonesia .*

Abstract

Various degree of ventricular activation by accessory pathway (AP) and normal conduction system in a patient with pre-excited atrial fibrillation (AF) may lead to ventricle dyssynchrony and cardiomyopathy.

Introduction

Left ventricular (LV) dysfunction due to accessory pathways (AP) is rare. Recognizing pre-excitation as a cause for LV dysfunction is important as it is reversible. Recovery of cardiac function after radiofrequency ablation occurs over a variable period of time. Previous study suggest septal or paraseptal accessory pathway has been documented in patients with overt ventricular pre-excitation who developed LV dysfunction.[1] We report a patient with pre-excited AF from left lateral AP and severe LV dysfunction who underwent ablation of accessory pathway and showed significant improvement of LV function thereafter.

Case Report

A 76 years old male with recurrent palpitation and shortness of breath for 1 year was referred for ablation. The patient was diagnosed with Wolff-Parkinson-White syndrome (WPW) in 2016 [Figure 1]and QRS duration showed less than 130 ms, indicated lesser degree of pre-excitation. There is no history of angina or myocardial infarction.ECG on admission showed pre-excited AF [Figure 2] Transthoracal echocardiography (TTE) on admission showed dilation of all chambers, reduced LV ejection fraction (LVEF 29%) with global hypokinesis, compared to previous TTE (in 2016) that showed normal cardiac chamber size and function (LVEF > 50% and normokinetic).

Two quadripolar catheters were inserted into RV and His position. A Duo-decapolar catheter was inserted along right atrial crista to distal coronary sinus (CS). Baseline rhythm showed pre-excited AF. Sinus rhythm was achieved after electrical cardioversion. During sinus rhythm, AV fusion was seen in distal CS (D1-2/left lateral) [Figure 3]. Right ventricular pacing showed eccentric VA conduction with earliest retrograde atrial activation via the left lateral AP. Ablation procedure on left lateral AP was done by transeptal approach. There was VA dissociate during RV pacing after AP ablation. Ablation procedure on left lateral AP was done by transeptal approach. VA's dissociate during RV pacing were seen after AP ablation.

The patient was discharged on amiodarone 200 mg daily for rhythm control. There were no symptoms of heart failure and palpitations after three months of follow up. Serial ECGs during follow up showed sinus rhythm with no sign of an AP. After 3 months of follow up, TTE showed significant improvement of LV systolic function (LVEF 65%) and no evidence of hypokinesis.

Discussion

This patient had prior episodes of recurrent palpitations especially in the last one year. We assumed that intermittent pre-excited AF frequently occur during that time. Previous studies suggests that LV dyssynchrony may be more pronounced in patients with septal and paraseptal AP.[1] To the best of our knowledge, this is the first case of left lateral AP induced LV dyssynchrony leading to cardiomyopathy.

Cardiomyopathy in this case might occur in several mechanism. First, different various degree of ventricular activation by both AP and His-purkinje system lead to ventricle dyssynchrony [Figure 3]. Second, tachyarrhythmia (pre-existing paroxsysmal AF) itself may play an important role for worsening cardiomyopathy.[2,3] Third, even in sinus rhythm with pre-excited, LV dyssynchrony may occur.[4,5] Thus, the combination of them may lead to cardiomyopathy.

In a retrospective way, this case prove that elimination of pre-excitation in AF can result in mechanical resynchronization which lead to reverse remodeling and improvement in LV synchrony. Preventing tachyarrhythmia by maintaining sinus rhythm and slowing down the ventricular rate also may play important role for LV reversed remodelling.

Key Words

Ventricular Dyssynchrony, Reversed remodelling, Pre-excited AF.

Corresponding Author

Mohammad Iqbal Department of Cardiology and Vascular Medicine, Universitas Padjadjaran, Jalan Eyckman 38, Bandung 40161, Indonesia

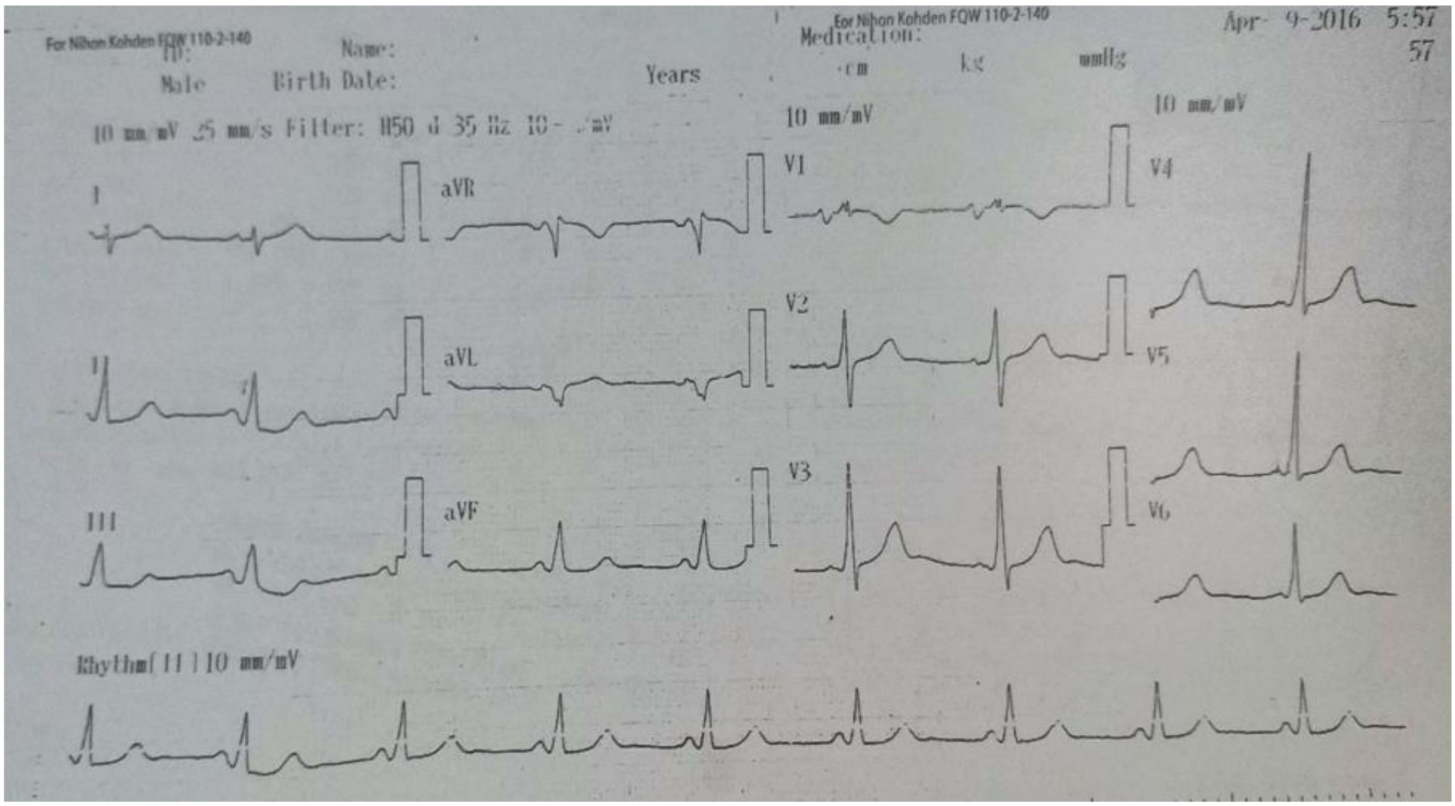

Figure 1: **Baseline ECG in 2016 showed sinus rhythm with preexcited. The QRS duration is less than 130 ms. Indicated of the lesser degree of preexcitation.**

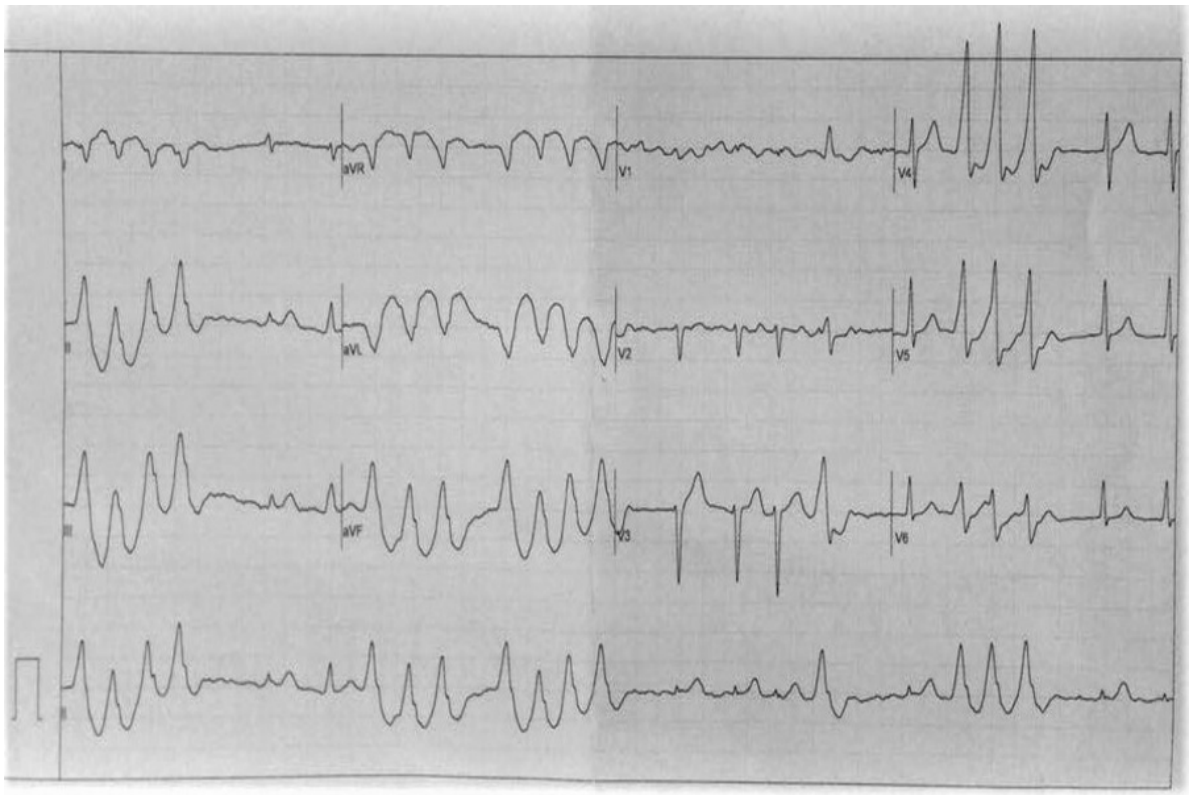

Figure 2: **12 lead ECG during admission. ECG showed pre-excited AF with various degree of preexcitation. The shortest R-R interval showed up to 200 ms and the widest QRS was about 150 ms.**

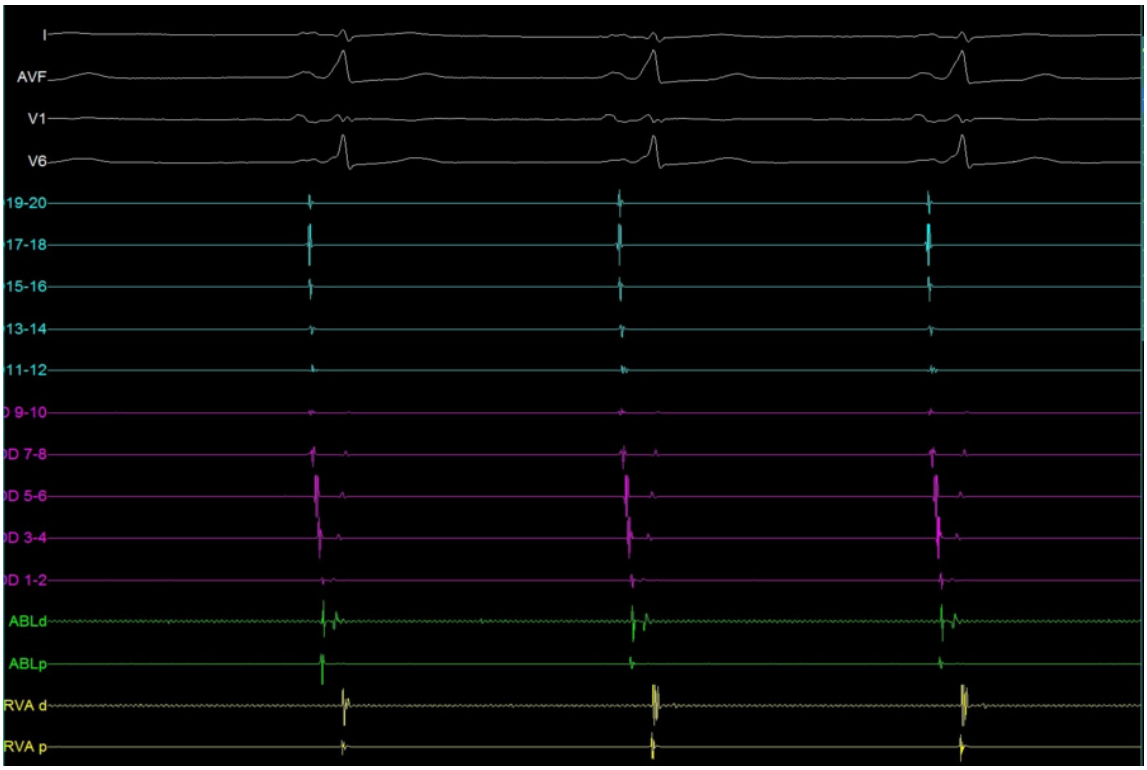

Figure 3: **D1-2 was duo-decapolar which inserted along low crista right atrial to distal CS. Electrogram during sinus rhythm showed AV fusion on distal CS (D1-2). Ablation (ABL) catheter was positioned near D1-2**

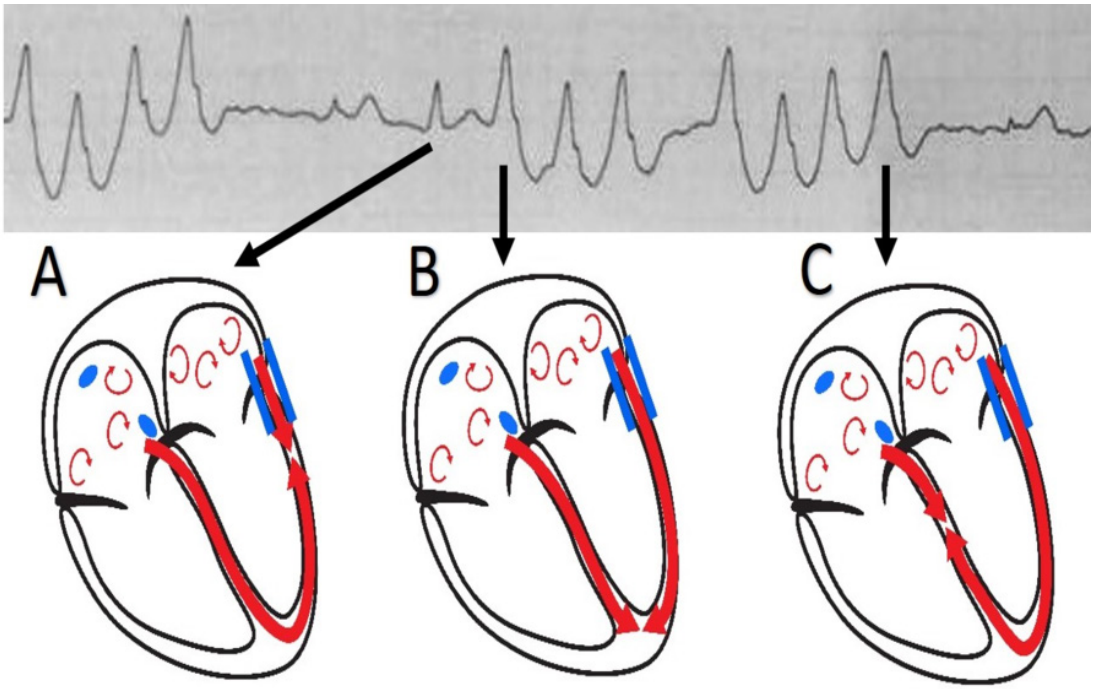

Figure 4: **Illustration of mechanical dyssynchrony due to varying degrees of ventricular activation by the AP and normal conduction system. (A) The narrowest QRS duration showed ventricle activation mostly was done by impulse from normal conduction system, (B) The "modest" QRS duration showed ventricle activation was done by impulse from AP and normal conduction system equally, (C)The widest QRS duration with maximal preexcitation, with the majority of ventricular activation over the AP**

There are several limitations of this paper. First, we lack of data of how long the patient remained in sinus rhythm (with or without pre-excited) in the last 1 year. But we believed that the symptomatic recurrent palpitation in the last 1 year indicated how much the pre-excited AF occur. Furthermore, 'silent' pre-excited AF may occur and underrecognized by the patient. Second, we did not perform AF ablation. Based on previous studies, the mechanism of AF is related to AP and almost AF burden will resolve spontaneously after AP ablation.[6,7] However, the recurrence rate of atrial fibrillation following successful ablation in patients with paroxysmal atrial fibrillation prior to ablation shows an age-related increase (high reccurence rate in patients older than 50 years of age).[8] Therefore, we decided to give amiodarone as a rhythm control for this patient. The duration of amiodarone to maintain sinus rhythm in such a case remains to be determined. Third, LV dysfunction due to ischemia could not be entirely excluded, because we did not performed coronary angiography (CAG). Our reasons were : (1) there is no indication of CAG for this patient considered no symptoms of chest pain or angina, (2) reverse remodeling and rapid improvement of LV function after catheter ablation also prove that low EF in this patient is due to LV dyssynchrony (reversible cause). Thus, made the cause of LV dysfunction due the ischemia "less likely". Fourth, this is a single case report. Therefore, this findings need to be confirmed by serial case or larger studies.

Acknowledgement

None

Disclosure

The authors declare no conflicts of interest.

Conclusion

Prolonged LV dyssynchrony due to pre-excited AF will lead to reversible cardiomyopathy. Elimination of AP by ablation and maintaining of sinus rhythm may play important role in improving LV synchrony and function.

References

1. Tomaske M, Janousek J, Rázek V, Gebauer RA, Tomek V, Hindricks G, Knirsch W, Bauersfeld U. Adverse effects of Wolff-Parkinson-White syndrome with right septal or posteroseptal accessory pathways on cardiac function. Europace. 2008;10 (2):181–9.
2. Umana E, Solares CA, Alpert MA. Tachycardia-induced cardiomyopathy. Am. J. Med. 2003;114 (1):51–5.
3. Gopinathannair R, Etheridge SP, Marchlinski FE, Spinale FG, Lakkireddy D, Olshansky B. Arrhythmia-Induced Cardiomyopathies: Mechanisms, Recognition, and Management. J. Am. Coll. Cardiol. 2015;66 (15):1714–28.
4. Haraguchi M, Kondo H, Ishii Y, Kobukata M, Imamura T, Otsubo T, Ayabe R, Saito S, Nagano Y, Akioka H, Shinohara T, Teshima Y, Yufu K, Nakagawa M, Takahashi N. A case of Type-C Wolff-Parkinson-White syndrome with severe left ventricular dysfunction: Efficacy of catheter ablation. J Cardiol Cases. 2017;15 (1):32–35.
5. Uhm JS, Nam JH, Yu HT, Yang PS, Kim TH, Cho IJ, Shim C Y, Joung B, Hong GR, Pak HN, Lee MH. Accessory pathway-related left ventricular wall motion abnormality and the effects of radiofrequency catheter ablation in patients with Wolff-Parkinson-White syndrome. J. Cardiovasc. Electrophysiol. 2019;30 (1):102–108.
6. Haissaguerre M, Fischer B, Labbé T, Lemétayer P, Montserrat P, d'Ivernois C, Dartigues JF, Warin JF. Frequency of recurrent atrial fibrillation after catheter ablation of overt accessory pathways. Am. J. Cardiol. 1992;69 (5):493–7.
7. Hamada T, Hiraki T, Ikeda H, Kubara I, Yoshida T, Ohga M, Imaizumi T. Mechanisms for atrial fibrillation in patients with Wolff-Parkinson-White syndrome. J. Cardiovasc. Electrophysiol. 2002;13 (3):223–9.
8. Dagres N, Clague JR, Lottkamp H, Hindricks G, Breithardt G, Borggrefe M. Impact of radiofrequency catheter ablation of accessory pathways on the frequency of atrial fibrillation during long-term follow-up; high recurrence rate of atrial fibrillation in patients older than 50 years of age. Eur. Heart J. 2001;22 (5):423–7.