

Biatrial, 3-Dimensional Mapping of Human Atrial Fibrillation: Methodology and Clinical Observations

Nicholas D. Skadsberg, PhD^a, Rangadham Nagarakanti, MD^b, Sanjeev Saksena, MD, FHRS, FACC, FESC^{c,d}

^a.Therapy Delivery, Cardiac Rhythm Disease Management, Medtronic, Inc., Minneapolis, Minnesota,

^b.Lankenau Institute for Medical Research, Wynnewood, Pennsylvania,

^c.Electrophysiology Research Foundation, Warren, New Jersey, and

^d.Department of Medicine Robert Wood Johnson Medical School, New Brunswick, New Jersey,

Introduction

Atrial fibrillation (AF), the most common arrhythmia in clinical practice, accounts for nearly one third of all hospitalizations for cardiac rhythm disturbances. Consequently, this has stimulated intense investigative interest in the development of effective therapeutic options. However, the electrophysiologic (EP) mechanisms of this arrhythmia have been long debated and remain unclear. This has limited the development of effective management strategies. Previous studies have shown the progressive remodeling associated with AF, initially believed to be functional and electrical in nature, now has structural and contractile impact.¹ It is increasingly clear that the latter two processes play an increasingly important role in the recurrence and persistence of AF.²⁻⁴ In an effort to clarify AF mechanisms, numerous experimental models have been developed. Their relationship to human mechanisms remains poorly defined. Direct mapping of human AF has been attempted but is still in its evolution. It is the purpose of this commentary to review existing mapping techniques and propose a new approach for mapping of human AF.

In the last few years, there have been several suc-

cessful techniques reported for the regional catheter mapping of discrete focal sources of AF in specific atrial regions.⁵⁻⁷ These methods generally consist of placing multipolar catheters in these regions, characterization of AF using activation maps, and assessing tachycardia responses to pacing and other maneuvers. These methods have proven most suitable in specific atrial regions (e.g., pulmonary veins, lateral right atrium (RA), or superior vena cava (SVC)), but are less suitable for global biatrial mapping due to multiple activation patterns and electrogram variations. Obtaining global mapping data to characterize a complex rhythm often dictates the placement of multiple catheters at numerous locations within the chamber of interest, which in turn requires a considerable amount of time. As a result, the patient and medical staff are exposed to extensive use of fluoroscopy for catheter placement and navigation. Most of these mapping techniques have to record from multiple sites, therefore performing a complete map requires sequential mapping over several cardiac cycles to allow for the recording of the complete EP substrate. This approach cannot account for the variability observed in electrocardiographic (ECG) patterns of human AF and as a result, may provide an incomplete explanation of mechanisms (Figure 1).

Corresponding Address: Sanjeev Saksena, MD, Medical Director, Electrophysiology Research Foundation, 161 Washington Valley Rd, Suite 201, Warren, New Jersey, 07059, USA.

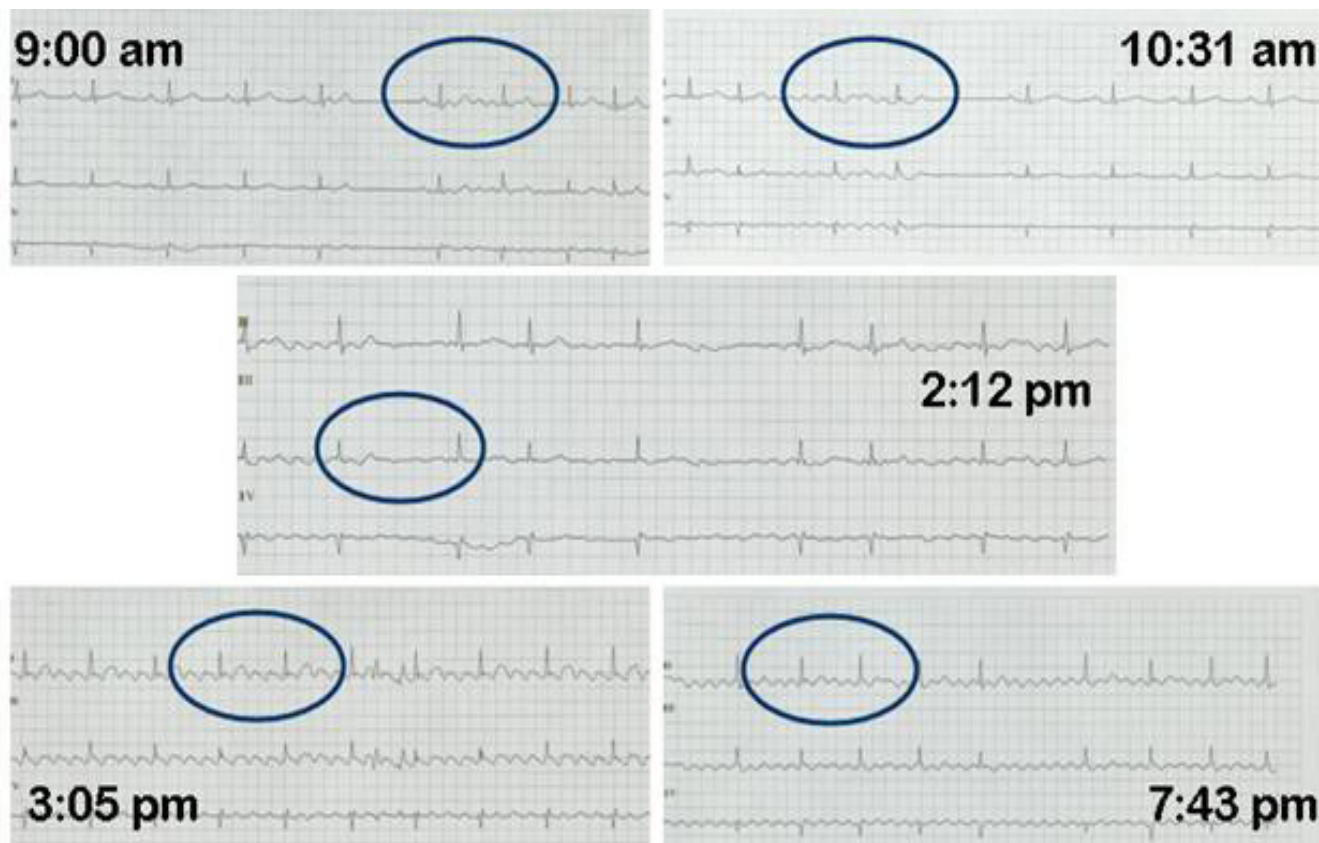
In an effort to overcome the limitations associated with conventional contact catheter mapping techniques, considerable advances have been made to achieve 3-dimensional (3D) electroanatomic mapping methodologies. Several mapping systems have been developed that can be used independently or in a complementary role to conventional electrode catheter mapping techniques. As a result, all of these approaches have potential to reduce fluoroscopic imaging required to perform the procedure. These techniques can broadly be categorized into two primary technology categories, each possessing their own unique advantages and disadvantages.

Two distinct technologies comprise the first category, termed “sequential” mapping systems, and include: (a) Electroanatomical map-

ping, commonly performed using the CARTOTM system (Biosense Webster, USA), and (b) the LocaLisa® system (Medtronic, Inc., USA). Common to each system in this category is the capability to collect 3D images as well as their respective electrograms in the target cardiac chamber and collate them in a virtual 3D reconstruction of the chamber’s endocardial anatomy.

“Continuous” mapping systems that permit single beat global chamber activation mapping represent another approach. This can be performed by either basket contact catheter or non-contact catheter array mapping (NCM). In this category, the systems allow for the recording of global electrogram data from a cardiac chamber so that the activation map can be characterized in a single beat. Basket or mesh contact catheter

Figure 1: Electrocardiographic recordings in a patient with paroxysmal atrial fibrillation showing variable ECG patterns in a single patient over the course of 1 day. Note the onset of the first episode (top left panel labeled 9:00 am) shows organized flutter or coarse fibrillation waves consistent with an organized tachycardia. These are also seen at termination on the top right panel (labeled 10:31 am). The second episode (middle panel, labeled 2:12 pm) shows fine fibrillatory waves, with a distinct pattern from the first event. The third event (bottom left panel, labeled 3:05 pm) shows typical saw toothed flutter waves consistent with type 1 flutter. The final event (bottom right panel, labeled 7:43 pm) shows flutter waves with a different morphology and rate from the previous event, consistent with another flutter morphology.



mapping necessitates electrode contact with the chamber's walls in order to obtain electrograms.

The HD Mesh Ablation System (Bard Electrophysiology, Lowell, MA, USA) comprises a 36 pole high density mapping and ablation catheter which has a braided, expandable mesh electrode configuration mounted onto a non-steerable 8 French (Fr) shaft. The HD Mesh Ablator catheter is introduced via the 9 Fr Channel steerable transseptal sheath into the LA and directed to the desired cardiac chamber. The expandable mesh electrode is deployed and un-deployed by using a sliding mechanism on the catheter handle. Pulsed radio frequency (RF) energy is delivered to the HD Mesh catheter electrodes to create the desired lesion geometry. A surface ECG and endocardial electrograms (EGM) are used for monitoring. Currently, this technique is being used for pulmonary vein isolation. After selective venography to identify the location and orientation of the pulmonary vein ostium, lesions are created circumferentially by delivering pulsed RF energy via the HD Mesh ablator catheter using EGM guidance until electrical isolation of the veins is observed. If the vein cannot be isolated with the catheter alone, EGM guided adjunctive ablation

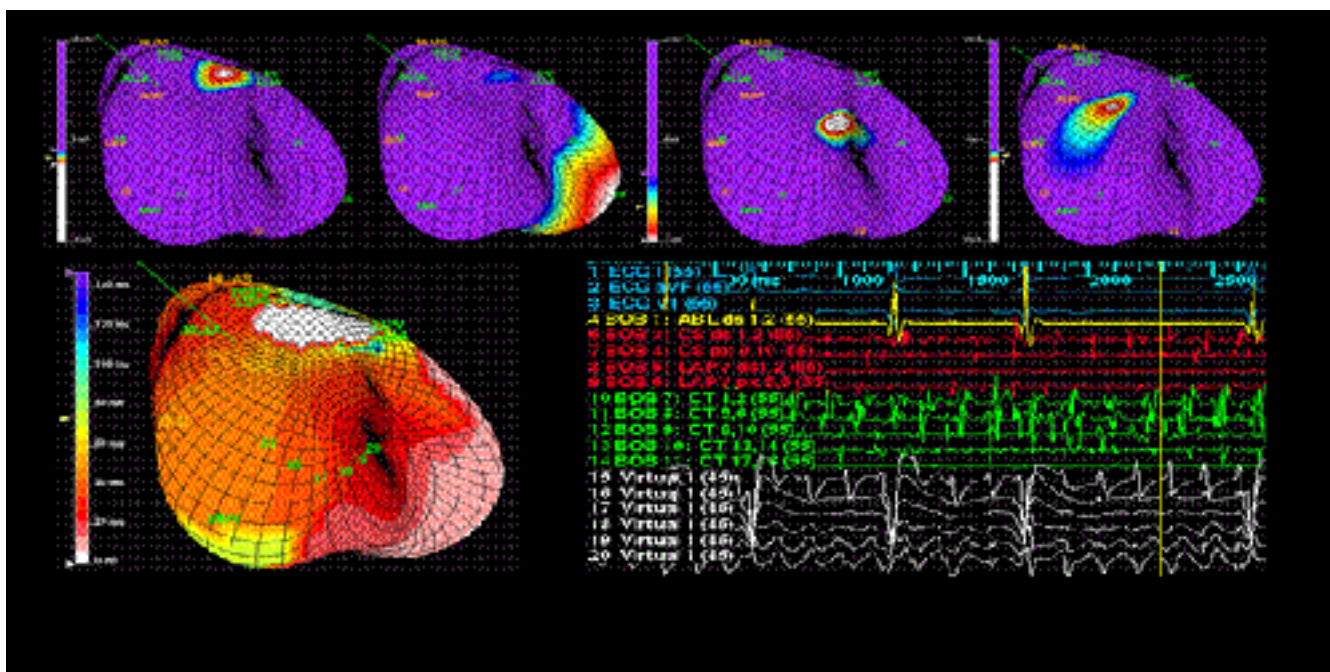
with a distal tip ablation catheter can be performed.⁸

NCM mapping employs a 64 electrode balloon catheter array in the blood pool of the chamber of interest, constructs a virtual contour geometry of the heart using catheter navigation and obtains over 3,000 virtual electrograms derived using the Laplace equation. These are then amalgamated to reconstruct the anatomy and EP wavefronts in the chamber of interest. These approaches can place the activation and anatomic constructs of the cardiac chamber in a single electrophysiologic 3D map, permit real-time wavefront propagation analysis, and allow for beat-to-beat activation mapping.

Clinical Experience

In 1995, we initiated the use of simultaneous biatrial catheter mapping for study of human AF.^{9,10} The methodology provided important insights suggesting organization and diversity in mechanisms of AF initiation. More recently, 3D NCM has provided the opportunity for high-resolution mapping on a beat-to-beat basis. We have integrated these two approaches to develop a novel practical, rapid and reliable method to map human AF. This report describes our methodology and sum-

Figure 2: Integrated recording of right and left atrial electrograms obtained using biatrial catheter electrode array with three dimensional non contact map of left atrium which permits beat to beat biatrial and high resolution left atrial mapping. Organized electrogram activity is noted at AF onset from the left atrium.



marizes some of our recent findings with respect to biatrial and 3D NCM in spontaneous AF patients.

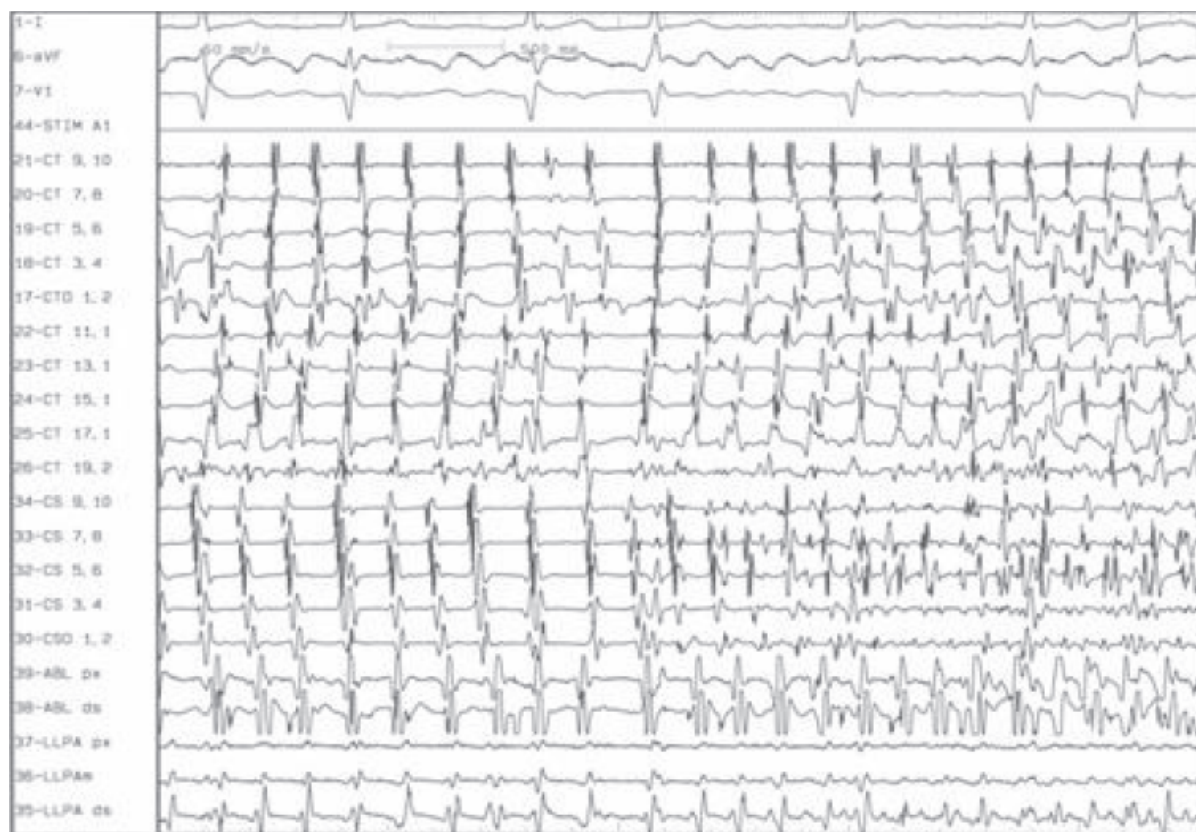Biatrial Three-dimensional Mapping Technique

A. Biatrial Catheter Mapping

A duodecapolar catheter is placed along the RA at the lateral RA free wall (Crista Terminalis; CT), and interatrial septum (IAS). Decapolar catheters are placed in the coronary sinus (CS), and in the left atrium (LA) via a patent foramen ovale or in the left pulmonary artery (LPA) under local anesthesia. The His bundle electrogram location serves as an anatomic landmark. The spacing between successive pairs of bipoles of the decapolar or duodecapolar (halo) catheter located at the IAS or CT is usually 5 mm and each electrode pair has an inter-electrode distance of 2 mm. A decapolar catheter with a 2-mm interelectrode distance and electrode spacing at 8 mm is used in the CS endocardially in the LA, or epicardially via the LPA. Bipolar record-

ing sites include high, mid and low lateral RA, high, mid and low IAS, proximal and distal His bundle, proximal to distal CS ostium, proximal, and mid and distal LPA for superior LA recordings. Additional recordings are obtained from the superior LA at the septal, mid-superior and lateral appendageal regions via a patent foramen ovale if present or via the LPA. The LPA recordings used have been previously validated with endocardial LA recordings. Bipolar electrograms are amplified and filtered between 30 and 100 Hz. Throughout the analysis, local intervals are measured between the onset of high frequency deflections of the successive EGMs. All intracardiac recordings and 12 surface ECG leads are simultaneously recorded on hard copy at paper speeds of 100 to 200 mm/s. Figure 2 demonstrates the onset of spontaneous AF which is analyzable on a beat-to-beat basis. We have previously demonstrated the stability and reliability of multiple catheters for biatrial mapping.⁹ The reproducibility of triggering beats sites with this mapping methodology has also been previously reported.^{9,10} Figure 3 shows an organized, single activation wavefront in the left

Figure 3: Demonstration of an organized single activation wavefront on the left side of the panel which then changes cycle length, activation pattern and with appearance of fragmented electrograms on the right side.



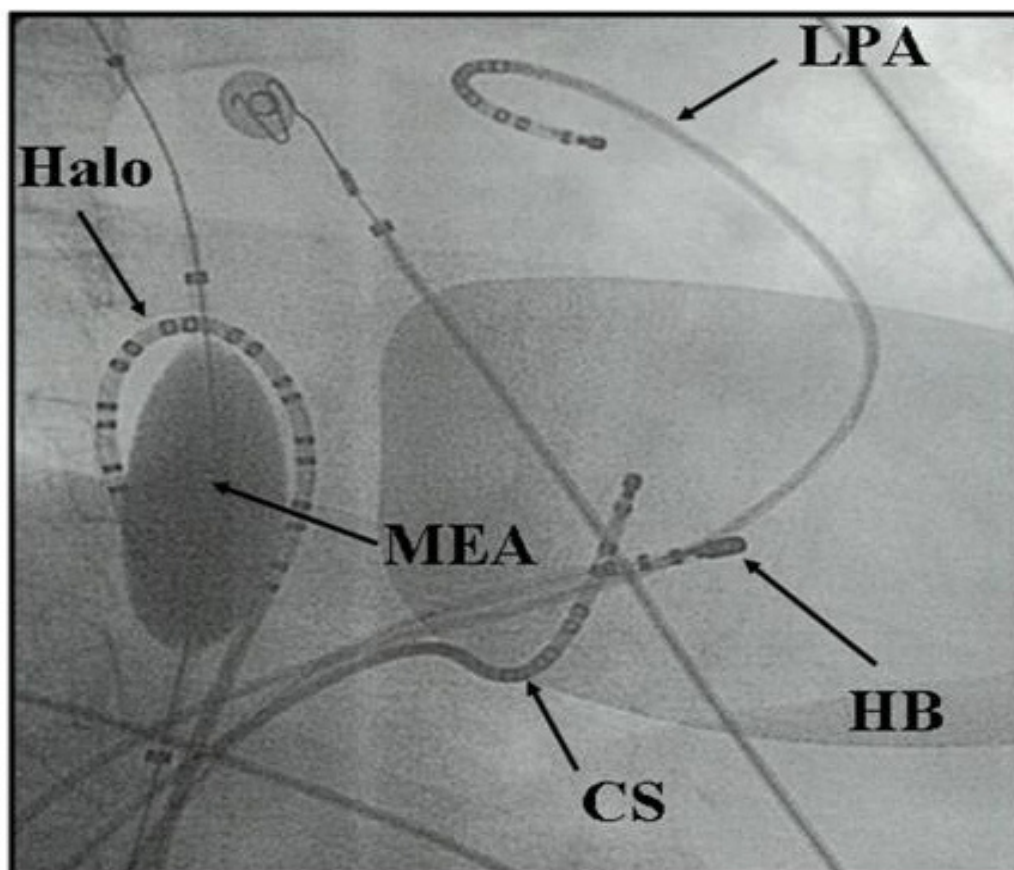
atrium which then changes cycle length, activation pattern, and appearance of fragmented electrograms on the right atrium.

B. Three-Dimensional Non-Contact Balloon Catheter Mapping

An endocardial balloon electrode (EnSite®, St. Jude Medical, St. Paul, MN) is advanced through a special sheath into the RA via the right femoral vein. A typical RA placement can be seen in Figure 4. In patients with a patent foramen ovale, it was placed first in the LA and later relocated to the RA for biatrial mapping. 3D mapping of AF in the RA or LA or both was performed. The 7.5 mL balloon is deployed by injection of a 50/50 mixture of saline and contrast media fully expanding the multi electrode array (MEA) containing the 64 electrodes. Under fluoroscopic guidance, a 3D contour in the RA is developed using EGMs and anatomically identifiable land-

marks in the lateral RA, such as the orifices of the great veins, the entire ring of the tricuspid annulus, CS ostium, tricuspid valve - inferior vena cava isthmus sites, the lateral RA from superior to inferior locations and the IAS at multiple sites along a cranio-caudal axis. Similarly, in the LA, we identified mitral valve annulus and its posterior and anterior aspects from the free wall to the septal aspects, orifices of the four pulmonary veins, superior to inferior lateral LA, the LA appendage and the foramen ovale. Virtual electrogram recordings from over 3,300 endocardial sites and digitized biatrial catheter electrograms were simultaneously recorded for beat-to-beat analysis of spontaneous atrial premature beats (APBs) (regional origin) and atrial tachyarrhythmias (ATs). Figure 5 demonstrates an example of an upper loop RA flutter recorded during a spontaneous AF episode in a patient with a mitral valve prosthesis and persistent AF.

Figure 4: Position of the multi electrode array balloon catheter in the right atrium and biatrial contract catheters in a right anterior oblique fluoroscopic view. Abbreviations: CS = Coronary Sinus, HB = His bundle, LPA = Left Pulmonary Artery, MEA = Multielectrode Array



C. Mapping of Spontaneous and Induced AF

This mapping approach has been employed in our studies to map both induced and spontaneous AF.^{9,10} In both types of AF, organized electrogram activation patterns have been documented. However, induced AF is most often initiated by local intra-atrial reentry near the pacing site. In contrast, spontaneous AF can be initiated by different premature beats that may be significantly distant from the onset tachycardia. These premature beats may differ spatially in location but this may appreciate only the 3D NCM rather than the surface ECG or EGM configuration (Figure 6).

Mapping of spontaneous AF is clearly the clinically relevant event. However, the spontaneous event may not occur during the course of an EP study and has to be stimulated. Administration of large doses of isoproterenol is often used for this purpose, but we have observed that induced AF events can promote spontaneous AF events either by evolving into that rhythm, after spontaneous termination of the induced AF, or after cardioversion of the induced AF. In the event that the patient arrives in persistent AF, EGM recordings may show simultaneous tachycardias and NCM is employed to delineate the substrate involved.

It is our experience that this extent of rotor mapping is rarely feasible with regional atrial mapping with a single or even two multipolar electrode catheters. Cardioversion of the persistent AF event often results in unmasking triggers and early AF recurrences after cardioversion identify the mechanisms of AF onset and contributing rotors. Evolution of AF over the next few minutes in the study may often clarify additional tachycardia rotors that develop and maintain persistent AF.

It is from these data obtained in such procedures that we have proposed multiple triggers exist in human AF and that multiple ATs are present in both paroxysmal and persistent AF and these constitute rotors that initiate or maintain AF episodes. AF progression is most likely related to the development of a biatrial substrate for the arrhythmia and proliferation of these rotors that result in persistence of an individual event. In the following section, we describe some of our findings in different AF presentations and disease states.

D. Clinical Observations with Biatrial NCM

In this section, we summarize some of our novel observations from this novel approach to AF mapping. For our initial studies, we selected consecutive pts meeting the following study inclusion

Characteristics	All	Group 1	Group 2
Number of patients	76	20	56
Males/Females (no.)	52/24	14/6	40/16
Age (years, mean±SD)	63 ± 11	62 ± 12	63 ± 11
Ejection Fraction (% , mean±SD)	47 ± 8.9	52 ± 10	47 ± 9
LA Diameter (cm, mean±SD)	4.4 ± 0.9	4.1 ± 0.9	4.6 ± 0.9
No. Pts with Cardiovascular Disease	60 (79%)	12 (60%)	52 (87%)
Distribution of Cardiovascular Disease	No. (%)	No. (%)	No. (%)
HTN	35 (46)	7 (35)	28 (50)
CAD	20 (26)	6 (30)	14 (25)
DCM	8 (11)	1 (5)	7 (13)
VHD	1 (2)	0 (0)	1 (2)
ASD	1 (2)	0 (0)	1 (2)
Other	11 (14)	3 (15)	8 (14)

criteria: (1) Presence of symptomatic, recurrent AF, failed at least 2 antiarrhythmic drug trials, and were undergoing a clinically indicated EP study for definition of mechanisms, atrioventricular conduction and the treatment of associated tachyarrhythmias, and (2) In all patients a written informed consent was obtained for the EP testing and mapping procedure.

In these patients, we systematically performed the following analyses:

- 1) Identified spontaneous APBs over a period of observation for regional origin and coupling intervals regardless of their involvement in initiating an episode of AF,
- (2) Examined spontaneous AF onset, for tachyarrhythmia mechanism, regional origin, cycle length and termination modes,
- (3) Compared activation, evolution and termination patterns of AF in individual patients whether arising from the RA or LA, and
- (4) Compared these patterns and their relationship to the presence of structural heart disease.

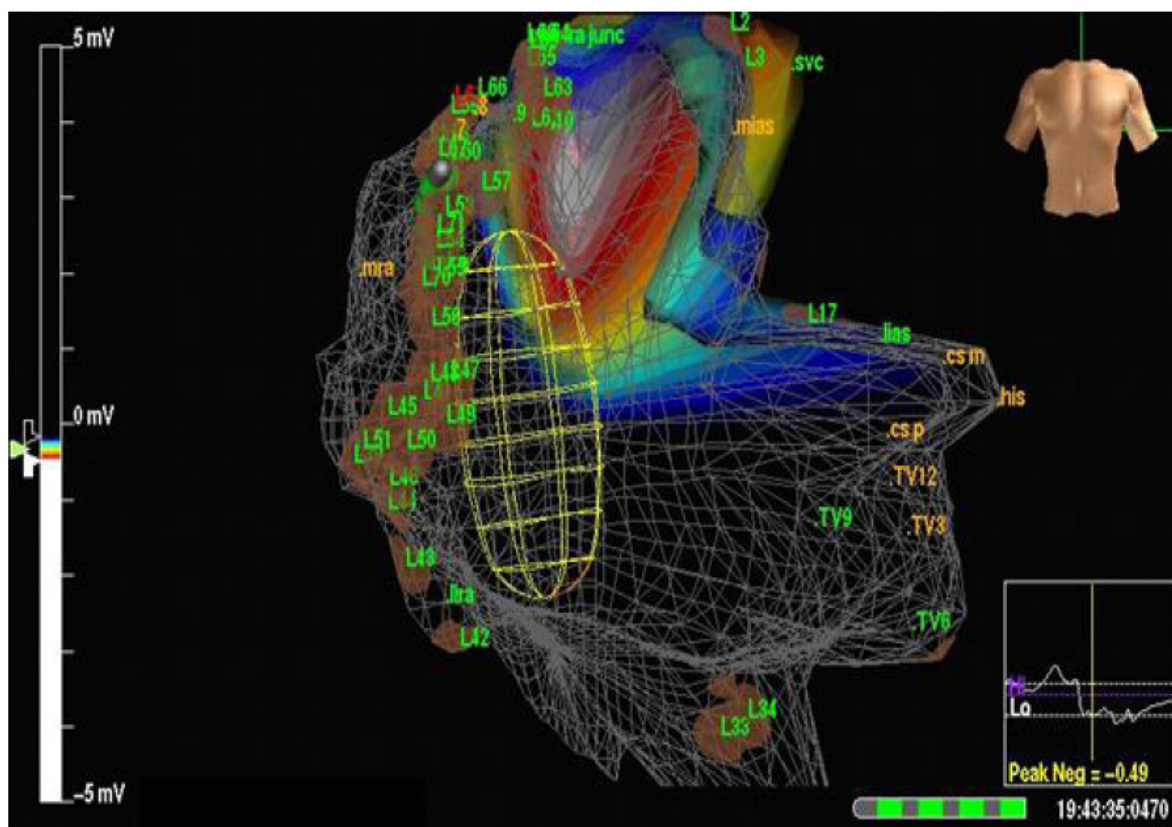
Study Population

A total of 76 patients, mean age 63 + 11 years (68%Male) were included in this analysis (Table 1). The study population had structural heart disease in the majority of patients (79%) and was mostly in New York Heart Association Class I or II. Further analyses were conducted to permit study of different AF populations, specifically paroxysmal AF patients (Gp.1, n=20) compared to persistent AF patients (Gp.2, n=56).

Mapping of Spontaneous APBs and Spontaneous AF

66 patients demonstrated spontaneous APBs in the RA (n=90) and LA (n=41) with similar regional distributions regardless of structural heart disease status. 42 pts (64%) had > 2 disparate regional origins and biatrial regional foci demonstrated equal frequency in Gp.1 and 2 pts (41% and 43%, respectively; see Figure 7 (a)). The regional distribution by patients showed the predominant region of ori-

Figure 5: Non Contact Map example of an upper loop RA flutter recorded during a spontaneous AF episode in a patient with a mitral valve prosthesis and persistent AF. The head of the wavefront is shown with a white zone and the development of linear lesions (labeled L) to form a right atrial compartmentalization lesion set for interruption of the flutter.



gin as being the IAS in the overall population (40 pts or 61%) and Gp.2 patients (30 pts or 65%). In Gp.1 patients, the predominant regions of origin was equally observed both in the IAS and the superior LA (10 pts or 59%, respectively). Figure 8 demonstrates the ability of simultaneous biatrial and NCM to identify differing sites of origin of five APBs recorded in a single patient in rapid sequence in a single procedure.

56 patients (74%) demonstrated 93 spontaneous episodes of AF as documented by simultaneous ECG recordings during the mapping procedure. 61% of patients had a right-sided origin and 39% has a left-sided origin of the AT. It was observed that the regional distribution was more extensive

in Gp.2 pts compared with Gp.1 patients (see Figure 7 (b)). Isthmus dependent RA counterclockwise flutters were most common in the overall population and Gp.1 patients (48% and 58%, respectively), while nonisthmus dependent RA flutter was most common in Gp.2 patients (47%). Overall, focal or macroreentrant left sided ATs were seen in 10 patients (18%), and macroreentrant LA flutter in 14 patients (25%).

In pts with triggers localized to the superior LA or superior pulmonary veins and in those localized to the inferior LA or pulmonary veins, there was a single centrifugal wavefront, as discerned from both contact and NCM recordings. RA or septal triggers resulted in focal origin with centrifugal

Figure 6: Simultaneous biatrial and NCM offers the ability to immediately identify differing sites of origin of APBs recorded in a single procedure in a high resolution three dimensional location. The RA three dimensional NCM contour is shown with the body torso orientation on the top right of each panel and selected ECG recordings and electrograms from the biatrial contact catheter map and virtual recordings from the non contact map are shown at the bottom. Note that the catheter electrograms show the differing atrial activation patterns while the P-wave morphology may show modest or very subtle changes. Abbreviations: APB = atrial premature beat, Inf = inferior, Lat = lateral, RA = right atrium, SLA = superior left atrium.

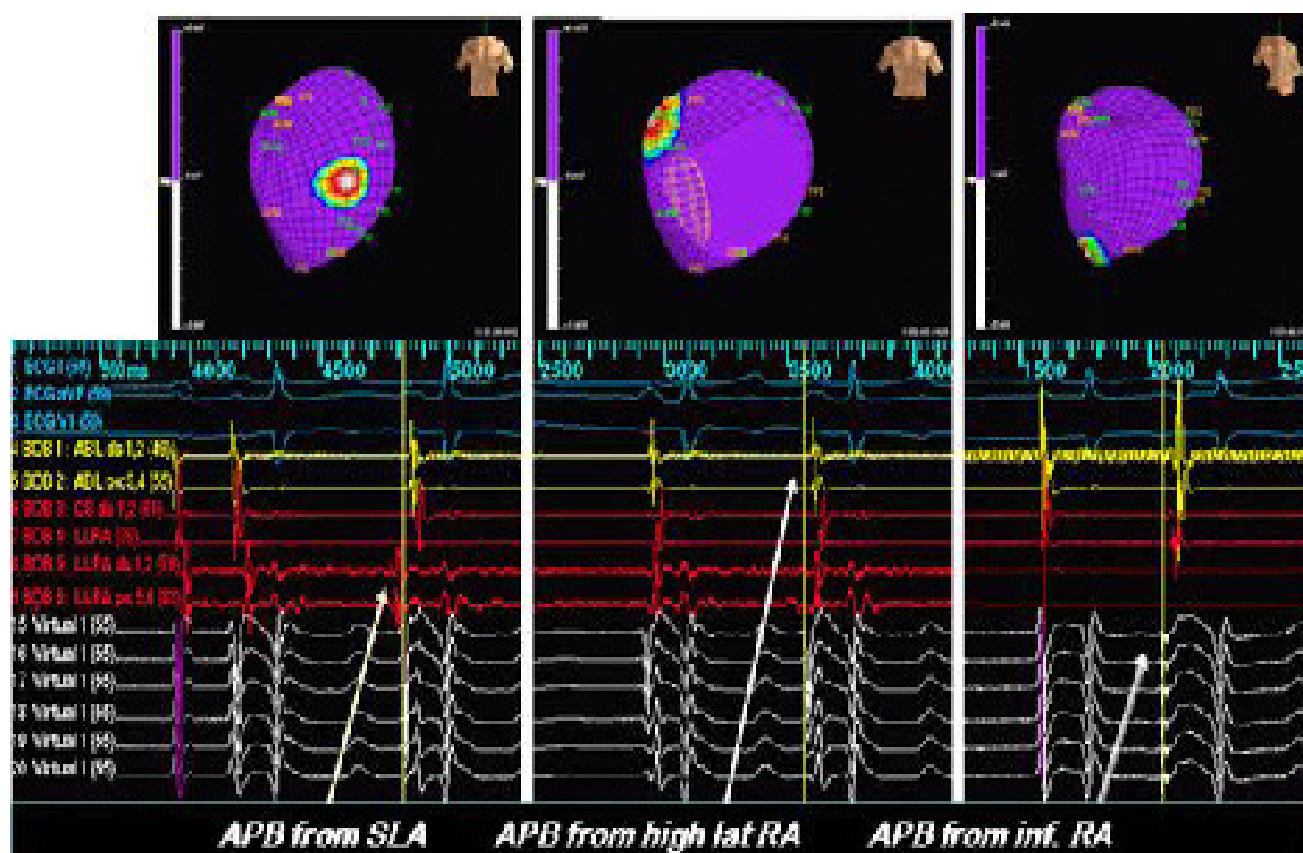


Figure 7: Summary of the (a) region of origin of the atrial premature beats in the left figure panel, and (b) atrial tachyarrhythmias in the patient population as demonstrated by biatrial and non-contact mapping.

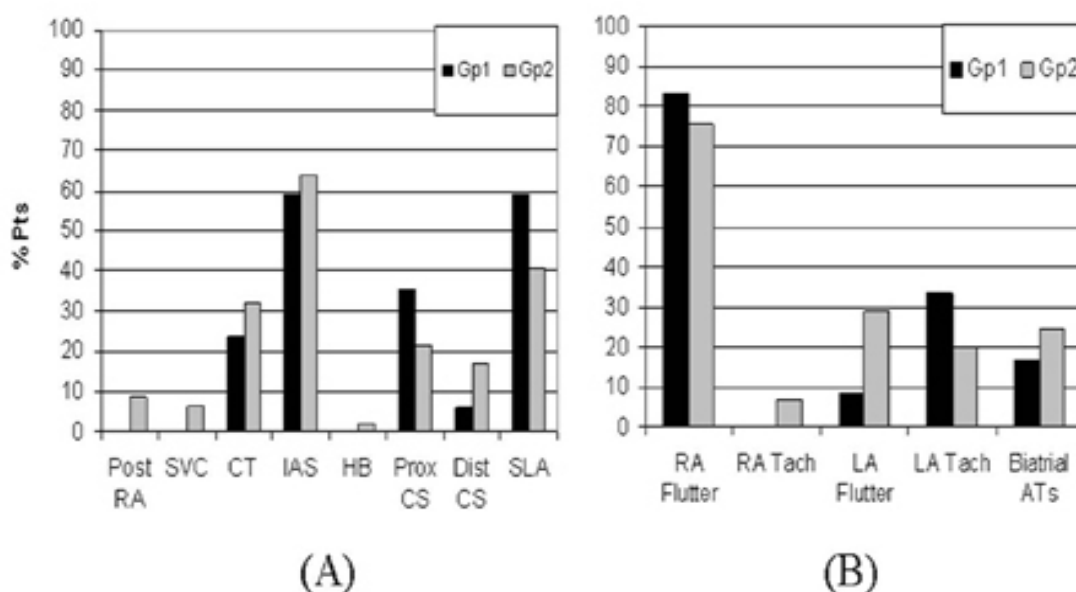
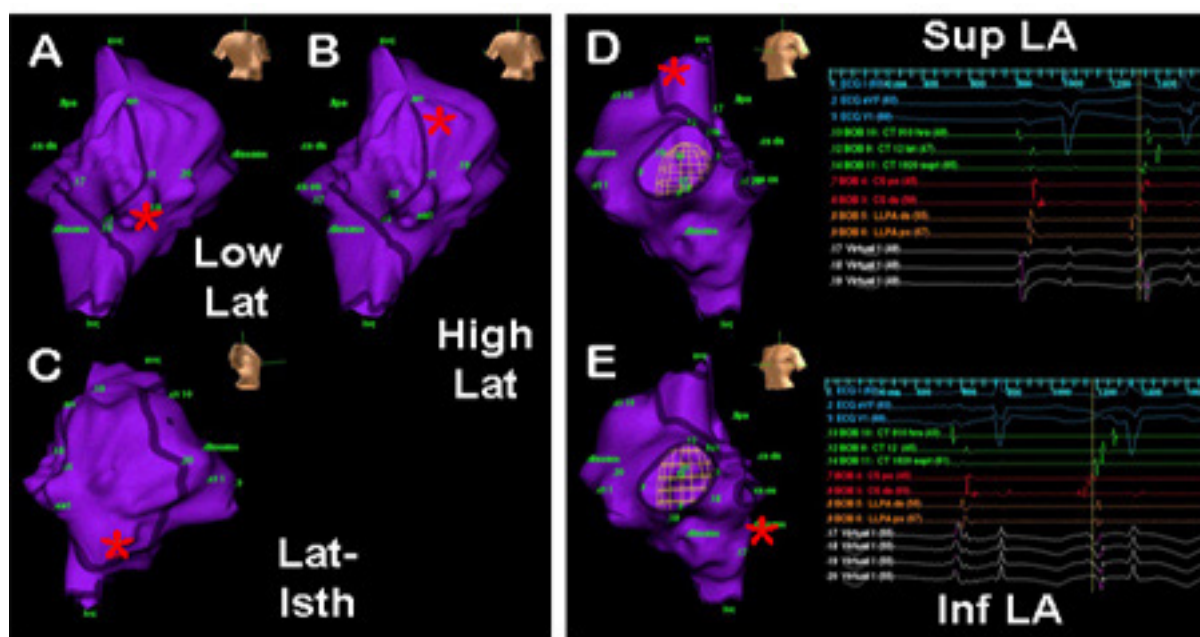


Figure 8: Simultaneous biatrial and NCM to identify differing sites of origin of five APBs recorded in a single patient in rapid sequence in a single procedure. The RA three-dimensional NCM contour is shown with the body torso orientation on the top right of each panel and selected ECG recordings, electrograms from the biatrial contact catheter map and virtual recordings from the NCM are shown on the right. The site of origin of the APB is shown with a red asterisk and can be spatially related using the body torso orientation. The left column shows APBs arising in the RA at three differing locations. The right column shows catheter electrograms showing LA onset of two different APBs with widely disparate RA breakthrough locations and activation patterns. Abbreviations: SVC = superior vena cava, IVC = inferior vena cava; CT 1-8 = Lateral RA; HLRA, MLRA, LLRA = high, middle, and low lateral RA, respectively; HCT = high lateral RA; LCT = low lateral RA; HIAS = high interatrial septum; CT 11-20 = septal locations; CSpx = coronary sinus ostium; CS dis = coronary sinus distal; LLPA and LPA = left pulmonary artery. The numbers represent virtual electrogram recording sites.



propagation (Figure 9). During RA propagation, a single dominant wavefront activated the RA. After AF onset, a macroreentrant wavefront with a head to tail relationship was seen. There was no period of electrical quiescence noted. Figure 10 demonstrates a cascade of ATs initiated by a left atrial APB probably arising in a superior pulmonary vein. The APB shows a breakthrough into the RA septum (top panel) and is followed by a left sided AT (middle panel) with a similar RA breakthrough and finally induces a counterclockwise RA flutter (lower panel).

Discussion

There are several major findings to report from these early experiences.

(1) There is a broad distribution of triggering beats in the RA, septum and LA/pulmonary veins in a drug-refractory AF population from paroxysmal to persistent/permanent pts.

(2) Both Gp. 1 and Gp.2 patients demonstrated equal frequency of biatrial regional foci and distribution; commonly with multiple regional sources of APBs in an individual patient. The reproducible origin of APBs and ATs in this study argues against catheter-mediated initiation of the arrhythmias.

(3) At sustained AF onset, focal triggers initiate an organized tachyarrhythmia, which may be focal or reentrant in nature and may localize to an adjoining atrial region or recruit a larger atrial circuit.

(4) In patients with paroxysmal AF or in those without structural heart disease, LA tachycardias and RA flutter are commonly present while a much broader spectrum of tachyarrhythmias are seen in patients with persistent/permanent AF or in the presence of structural heart disease.

Implications of biatrial mapping for mechanisms of AF

In the early twentieth century, several different mechanisms were proposed including Lewis who propounded the theory that AF was “an impure flutter with fibrillatory conduction”.¹¹ It was in 1959 that Moe and Abildskov replaced this concept with the multiple wavelet hypothesis based on computer simulations of AF.¹² Available animal models studied by Allesie and coworkers

corroborated the concept in the multiple wavelet model and they described the basis of AF as random functional reentry, with wavelength being critical to defining the reentrant circuit.¹³ Subsequently, their studies have shown that persistence of sustained AF results in functional electrical remodeling in the atrium.¹⁴

Human studies have provided vignettes from different sources as to clinical mechanisms. Atuel and coworkers have shown the importance of electrophysiologic changes in the substrate in AF patients.¹⁵ Intraoperative mapping studies of Cox and Schuessler indicated evidence for macroreentrant circuits in human AF.¹⁶ Focal triggers of AF originating from pulmonary veins were identified and have been studied extensively.⁴ Considerably less focus has been paid to other regions of AF origin. While some investigators have described superior vena caval triggers, other sites or arrhythmias triggering AF have been poorly defined.¹⁷

Regional Mapping of AF

Hitherto, catheter mapping of human AF has been limited to EGM recordings in specific regions of interest (e.g., pulmonary veins) and regional mapping has been limited to intraoperative studies.^{17,18} A major limitation of the regional catheter method has been infrequent and sporadic recording of spontaneous sustained AF, requiring repetitive, stable rhythms. Absence of regional or global mapping limits the trigger analysis to one or few regions of interest and provides limited insight into the behavior of both atria during initiation or perpetuation of AF. Haisseguire et al., used Lasso catheters for the focal mapping of pulmonary veins, where rapidly firing foci play an important role in the initiation and maintenance of AF.⁴ Other investigators have employed duodecapolar Halo catheters placed around the tricuspid annulus, however, it is difficult to obtain regional mapping information. These techniques require catheter manipulation and stabilization to record from multiple sites. As a direct consequence, the changing nature of electrical activation patterns in AF pose a severe limitation to sequential mapping methods. Our approach overcomes many of these issues and permits the recording of important biatrial behavior in the vast majority of pts in the study (90%).

Biatrial Contact and NCM Mapping of AF

Simultaneous biatrial contact and high-resolution NCM has been able to

(a) Provide more mechanistic information on triggers (atrial premature beats (APBs), initiation and evolution of spontaneous AF, and ATs),
 (b) Permit study of different AF populations,
 (c) Provide a global view of the EP behavior of both atria. Used simultaneously, we demonstrated that these two techniques provide extensive mechanistic information on triggers, initiation, and evolution of human AF in contrast to currently employed techniques. We can suggest from this approach that the progression of AF from paroxysmal to persistent and permanent forms is characterized, not by change in triggering APB distribution, but by the more extensive distribution of ATs. The varying frequency of AF recurrences with single therapeutic interventions in AF including RA maze procedures, focal pulmonary vein ablation or pacing therapy and inadequate long term rhythm control as seen in clinical trials may be due to multiple organized tachycardias

and triggers.¹⁹⁻²² Our findings support extensive biatrial interventions or a hybrid therapy approach for long-term suppression of AF,²³⁻²⁵ and (d) Allows for tailored linear ablation procedures to be designed. Figure 11 demonstrates a left atrial isolation with linear lesions including a roof line and a mitral isthmus line.

Limitations

There are technical limitations of NCM including a loss of resolution beyond a 4 cm radius of the balloon electrode and pulmonary artery recordings that cannot be equated with detailed endocardial LA catheter and balloon mapping that would allow for more detailed LA localization. The NCM system employs contact catheters to create a 3D representation of the endocardial anatomy of the patient's chamber of interest, however to provide the most accurate representation of the patient's true anatomy one must have the ability to import a cardiac CT/MRI into the mapping system for navigation purposes.

Figure 9: Biatrial and right atrial noncontact high resolution map of the onset of AF from the right side of the interatrial septum. Body torso orientation is shown in the inset, with a left lateral view of the right atrium. The red asterisk shows the onset of the AF wavefront in a single beat.

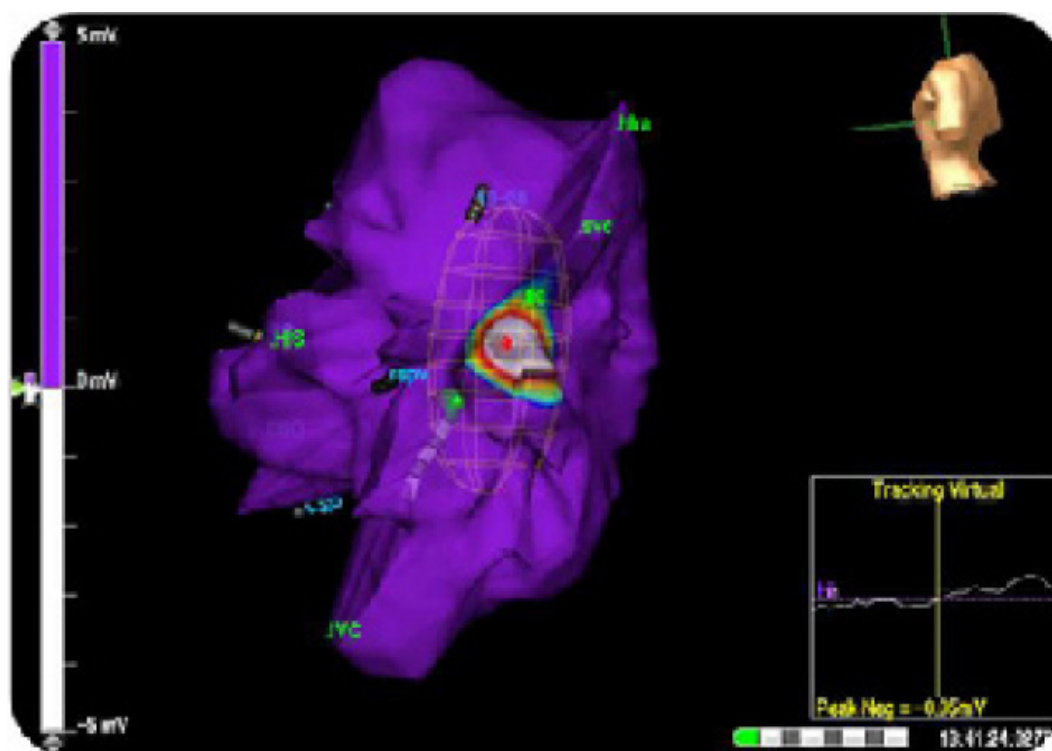


Figure 10: Noncontact mapping demonstrates a cascade of ATs initiated by a left atrial APB probably arising in a superior pulmonary vein. The APB shows a breakthrough into the RA septum (top panel) and is followed by a left sided AT (middle panel) with a similar RA breakthrough and finally induces a counterclockwise RA flutter (lower panel). The biatrial catheter electrogram map and virtual electrograms are shown. Abbreviations: LPV = left pulmonary vein, RA = right atrium, Tach = tachycardia.

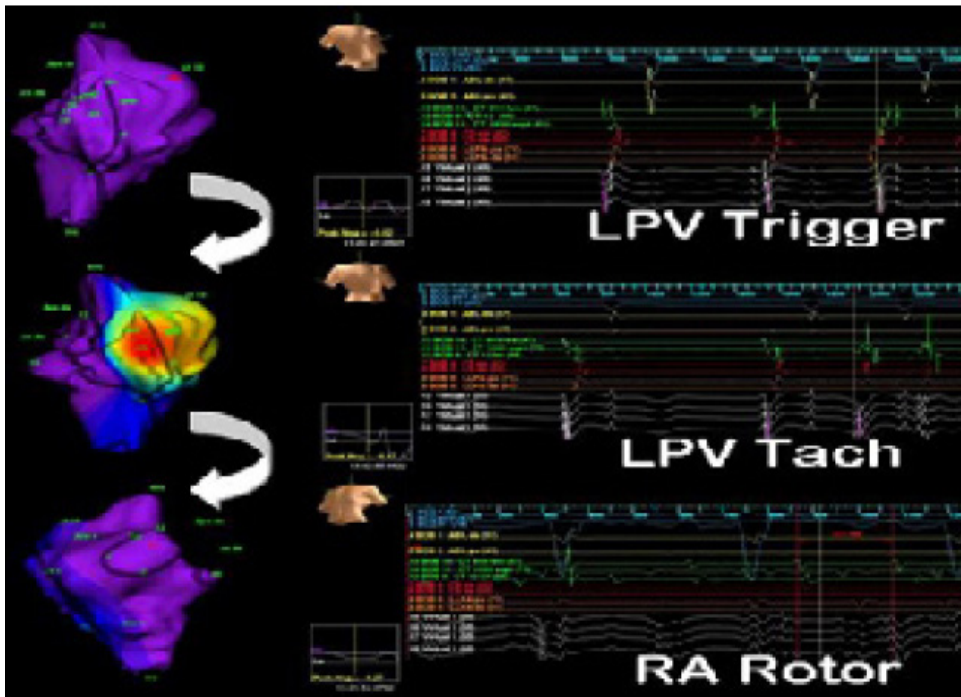
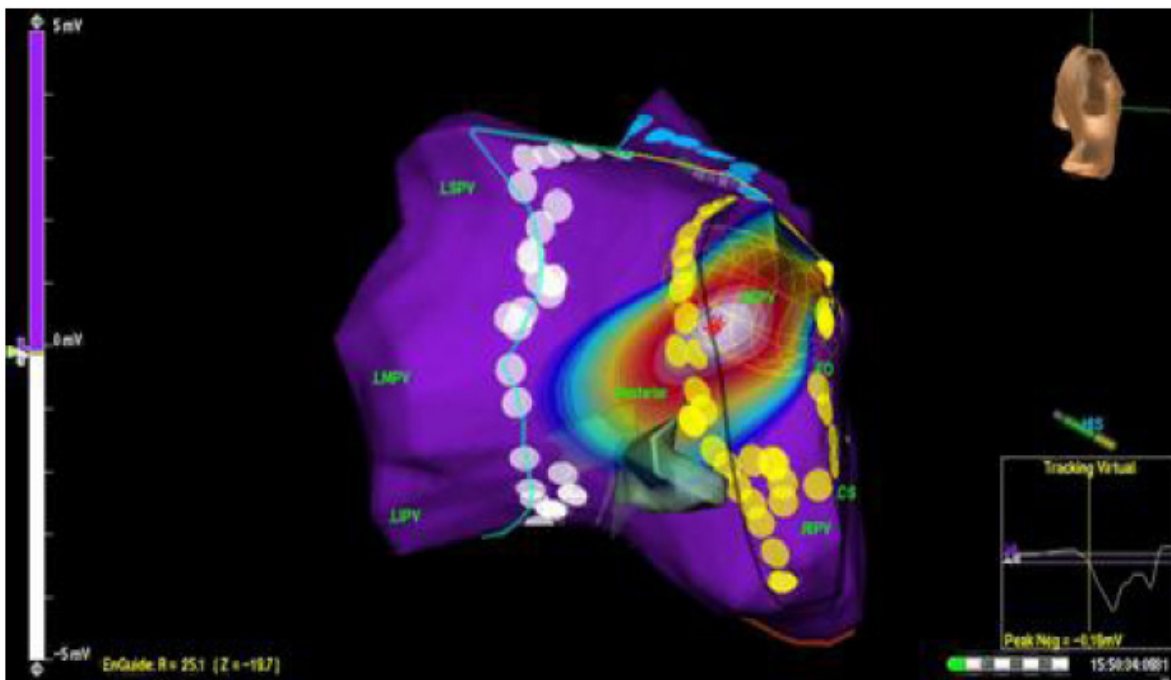


Figure 11: Example of a tailored left atrial compartmentalization procedure with linear lesions including bilateral pulmonary vein antral isolation, a roof line and a mitral isthmus line. The wavefront seen is a tachycardia arising from a superior pulmonary vein that is entrapped in a posterior compartment.



Conclusions

The methodologies described in this report provide a clinically relevant, global atrial mapping technique to help classify AF initiation and maintenance in a given patient and provide targets for interventional therapeutic procedures. In large part, owing to the ability of the technique to record widely disparate triggers and ATs in a rapid and reliable fashion. Simultaneous biatrial and NCM permits successful AF mapping in different AF populations and demonstrates a biatrial spectrum of spontaneous triggers and organized monomorphic tachycardias with multiple or biatrial locations. Evolution into sustained AF can be studied with global biatrial contact and NCM in humans. These methodologies bridge the divide between observations obtained with regional catheter recordings and intraoperative findings in humans.

References

- Allessie M, Ausma J, Schotten U. Electrical, contractile and structural remodeling during atrial fibrillation. *Cardiovasc Res* 2002;54:230-246.
- Shinagawa K, Shi YF, Tardif JC, Leung T-K, Nattel S. Dynamic nature of atrial fibrillation substrate during development and reversal of heart failure in dogs. *Circulation*. 2002; 105: 2672-78.
- Mihm MJ, Yu F, Carnes CA, Reiser PJ, McCarthy PM, Van Wagoner DR, Bauer JA. Impaired myofibrillar energetics and oxidative injury during human atrial fibrillation. *Circulation*. 2001; 104: 174-80.
- Saksena S, Hettrick DA, Koehler JL, Grammatico A, Padeletti L. Progression of paroxysmal atrial fibrillation to persistent atrial fibrillation in patients with bradyarrhythmias. *Am Heart J*, 2007. 154(5): p. 884-92.
- Haissaguerre M, Jais P, Shah DC, Gencel L, Pradeau V, Garriques S, Chouairi S, Hocini M, Le Metayer P, Roudant R, Clementy J. Right and left atrial radiofrequency catheter therapy of paroxysmal atrial fibrillation. *J Cardiovasc Electrophysiol*. 1996; 7: 1132-44.
- Haissaguerre M, Jais P, Shah DC, Takahashi A, Hocini M, Quiniou S, Garriques S, Le Mouroux A, Le Metayer P, Clementy J. Spontaneous initiation of atrial fibrillation by ectopic beats originating in the pulmonary veins. *N Engl J Med*. 1998; 339(10): 659-66.
- N WS, Tai CT, Hsieh CF, Lin YK, Tsao HM, Huang JL, Yu WC, Yang SP, Ding YA, Chang MS, Chen SA. Catheter ablation of paroxysmal atrial fibrillation initiated by non-pulmonary vein ectopy. *Circulation*. 2003; 107: 3176-83.
- Mansour M, Forleo GB, Pappalardo A, Heist EK, Avella A, Laurenzi F, De Giralmo P, Bencardino G, Dello Russo A, Mantica M, Ruskin JN, Tondo C. Initial experience with the Mesh catheter for pulmonary vein isolation in patients with paroxysmal atrial fibrillation. *Heart Rhythm*. 2008; 5(11): 1510-6.
- Saksena S, Giorgberidge I, Mehra R, Hill M, Prakash A, Krol RB, Mathew P. Electrophysiology and endocardial mapping of induced atrial fibrillation in patients with spontaneous atrial fibrillation. *Am J Cardiol*, 1999. 83(2): p. 187-93.
- Saksena S, Prakash A, Krol RB, Shankar A. Regional endocardial mapping of spontaneous and induced atrial fibrillation in patients with heart disease and refractory atrial fibrillation. *Am J Cardiol*, 1999. 84(8): p. 880-9.
- Lewis T. *The Mechanism and Graphic Registration of the Heart Beat*. 3rd ed. 1925, London: Shaw & Sons. 319-374.
- Moe GK, Abildskov JA. Atrial fibrillation as a self-sustaining arrhythmia independent of focal discharge. *Am Heart J*, 1959. 58(1): p. 59-70.
- Rensma PL, Allessie MA, Lammers WJ, Bonke FI, Schalij MJ. Length of excitation wave and susceptibility to reentrant atrial arrhythmias in normal conscious dogs. *Circ Res*, 1988. 62(2): p. 395-410.
- Wijffels M.C, Kirchhof CJ, Dorland R, Allessie MA. Atrial fibrillation begets atrial fibrillation. A study in awake chronically instrumented goats. *Circulation*, 1995. 92(7): p. 1954-68.
- Attuel P, Childers R, Cauchemez B, Poveda J, Mugica J, Coumel P. Failure in the rate adaptation of the atrial refractory period: its relationship to vulnerability. *Int J Cardiol*, 1982. 2(2): p. 179-97.
- Cox JL, Canavan TE, Schuessler RB, Cain ME, Lindsay BD, Stone C, Smith PK, Corr PB, Boineau JP. The surgical treatment of atrial fibrillation. II. Intraoperative electrophysiologic mapping and description of the electrophysiologic basis of atrial flutter and atrial fibrillation. *J Thorac Cardiovasc Surg*, 1991. 101(3): p. 406-26.
- Tsai CF, Tai CT, Hsieh MH, Lin WS, Yu WC, Ueng KC, Ding YA, Chang MS, Chen SA. Initiation of atrial fibrillation by ectopic beats originating from the superior vena cava: electrophysiological characteristics and results of radiofrequency ablation. *Circulation*, 2000. 102(1): p. 67-74.
- Konings KT, Kirchhof CJ, Smeets JR, Wellens HJ, Penn OC, Allessie MA. High-density mapping of electrically induced atrial fibrillation in humans. *Circulation*, 1994. 89(4): p. 1665-80.
- Garg A, Finneran W, Mollerus M, Birgersdotter-Green U, Fujimura O, Tone L, Feld GK. Right atrial compartmentalization using radiofrequency catheter ablation for management of patients with refractory atrial fibrillation. *J Cardiovasc Electrophysiol*, 1999. 10(6): p. 763-71.
- Gerstenfeld EP, Callans DJ, Dixit S, Zado E, Marchlinski FE. Clinical outcome after radiofrequency catheter ablation of focal atrial fibrillation triggers. *J Cardiovasc Electrophysiol*, 2001. 12(8): p. 900-8.
- Gillis AM, Wyse DG, Connolly SJ, Dubuc M, Philippon F, Yee R, Lacombe P, Rose MS, Kerr CD. Atrial pacing periablation for prevention of paroxysmal atrial fibrillation. *Circulation*, 1999. 99(19): p. 2553-8.
- Wyse DG, Waldo AL, DiMarco JP, Domanski MJ, Rosenberg Y, Schron EB, Kellen JC, Greene HL, Mickel MC, Dalquist JE, Corley SD for Atrial Fibrillation Follow-up Investigation of

Rhythm Management (AFFIRM) Investigators. A comparison of rate control and rhythm control in patients with atrial fibrillation. *N Engl J Med*, 2002. 347(23): p. 1825-33.

23. Madan. N, Saksena S. Long-term rhythm control of drug-refractory atrial fibrillation with "hybrid therapy" incorporating dual-site right atrial pacing, antiarrhythmic drugs, and right atrial ablation. *Am J Cardiol*, 2004. 93(5): p. 569-75.

24. Saksena S, Madan N. Hybrid therapy of atrial fibrillation: algorithms and outcome. *J Interv Card Electrophysiol*, 2003. 9(2): p. 235-47.

25. Swartz J, Pellersels G, and Silvers J. A catheter-based curative approach to atrial fibrillation in humans (abstract). *Circulation*, 1994. 90: p. I-335.