



New Migraine with Visual Disturbance after Cryoballoon Ablation of Atrial Fibrillation

Annupreet Nadha, Eric S Williams

Cardiac Electrophysiology, Swedish Heart & Vascular Institute, Swedish Medical Center, Seattle, WA 550 17th Avenue, Suite 450; Seattle, WA, USA 98122.

Abstract

We report the case of a 58-year-old woman who developed a headache and visual disturbances after a cryoballoon ablation procedure for atrial fibrillation at our institution. She presented to the emergency department four days post ablation and was admitted the hospital for overnight observation. Serial neurological examinations and neuroimaging were unremarkable for stroke or transient ischemic attack. The patient had some brief transient visual changes which resolved completely after several days, with no further clinical sequelae. She followed up in the outpatient neuro-ophthalmology clinic and had a normal visual field examination. She was given a diagnosis of new onset migraine with visual aura.

Case Report

A 58-year-old woman with a history of hyperlipidemia and drug-refractory paroxysmal atrial fibrillation was referred to our electrophysiology practice for catheter ablation. Her preoperative medications only included digoxin and aspirin, and these were not withheld prior to the procedure. A preoperative transesophageal echocardiogram confirmed the absence of thrombus in the left atrial appendage. Transseptal catheterization of the left atrium was performed with the aid of intracardiac echocardiography (AcuNav, Siemens Medical Solutions, Inc., Mountain View, CA) by direct puncture of the mid-posterior fossa ovalis with a 71-cm Brockenbrough transseptal needle (BRK-1, St. Jude Medical, St. Paul, MN) and an 8.5-French 63-cm guiding introducer sheath (SL-1, St. Jude Medical), followed by an over-the-wire exchange for a 12-French steerable sheath (FlexCath Advance, Medtronic Inc., Minneapolis, MN). Unfractionated heparin was administered via intravenous boluses started prior to transseptal puncture, followed by a continuous infusion to achieve activated clotting times >300 seconds during ablation in the left atrium. Pulmonary vein isolation and superior vena cava isolation were performed under general anesthesia using a 28-mm cryoballoon ablation catheter (Arctic Front Advance, Medtronic Inc.) and a 4-mm radiofrequency ablation catheter (Blazer II, Boston Scientific, Natick, MA), respectively. Left atrial mapping and ablation were completed within 75 minutes exclusively with

the cryoballoon sheath and catheter, and an additional 15 minutes were spent with the sheath and a radiofrequency ablation catheter in the right atrium to complete superior vena cava isolation. Heparin anticoagulation was then reversed with protamine, and six hours post procedure she was started on therapeutic oral anticoagulation with rivaroxban. She was discharged the next day in good condition.

On postoperative day#1, she developed a left occipital headache described as sharp but non-pulsatile that was initially mild in severity and relieved with oral acetaminophen. On post-operative day #3, the patient developed the sudden onset of visual symptoms described as bright flashes of light accompanied by blurriness of her peripheral vision bilaterally. Over the next 45 minutes, her vision normalized, at which time she developed recurrence of her left-sided headache. She had the return of similar visual symptoms the following day, and presented to the emergency department. Her blood pressure was 113/73 with a pulse of 94 beats per minute. She was alert and oriented to time, person and place. Her neurologic examination was non-focal. Laboratory studies, including complete blood count, renal function, and serum electrolytes were all normal. Serum digoxin level was 0.6 ng/mL. Electrocardiography and cardiac monitoring confirmed normal sinus rhythm. She underwent computed tomography (CT) imaging of her head, which showed no intracranial hemorrhage or mass lesion; CT angiography demonstrated no intracranial vascular stenosis. Magnetic resonance imaging of her brain was performed, which revealed only minimal nonspecific white matter disease, and no evidence of acute or subacute infarction [Figure 1]. Visualized portions of the orbits, optic nerves and visual pathways were also normal.

She was evaluated by the neurology service, who felt her presentation was consistent with a new onset migraine with visual aura. She had no previous history of migraine headaches. She did not have clinical evidence of an ischemic stroke or transient ischemic

Key Words

atrial fibrillation, catheter ablation, cryoballoon, transseptal catheterization, migraine.

Corresponding Author

Eric S. Williams, MD
Cardiac Electrophysiology Mercy Clinic Heart and Vascular 625
S. New Ballas Road, Suite 2030 Saint Louis,
MO, USA 63141

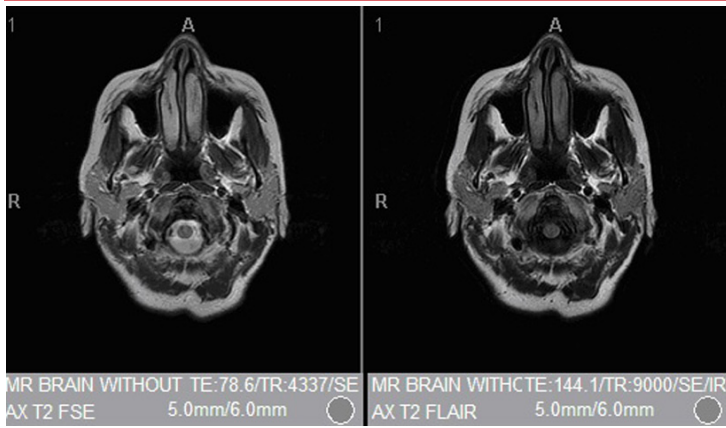


Figure 1: Magnetic resonance imaging (MRI) of the brain obtained post ablation

attack after overnight observation. She was discharged home in good condition. Over the next several days, she experienced some transient blurriness in her vision lasting approximately 45 minutes without headache or loss of peripheral vision. She had a follow-up visit in the neuro-ophthalmology clinic one week postoperatively, and both fundoscopic examination and visual field testing were within normal limits [Figure 2]. She had a follow-up visit in the cardiology clinic one month postoperatively, and described no further clinical sequelae.

Discussion

Catheter ablation of atrial fibrillation (AF) has evolved as a safe and highly effective treatment for drug-refractory symptomatic AF.^[1] Over the last few years, cryoballoon ablation has become an increasingly utilized technique for the treatment of AF in the electrophysiology laboratory.^[2] There have been a number of reports describing headache and migraines after AF ablation, including studies that suggest an increased incidence during and after cryoballoon AF ablation.^{[3]-[7]}

There appears to be a specific link between the iatrogenic atrial septal defect (IASD) caused by transseptal puncture and the development of post-procedure migraines. In a series of 571 consecutive patients undergoing transseptal catheterization at the time of catheter ablation for left-sided cardiac arrhythmias at a single center, isolated migraine aura occurred with an incidence of about 0.5%. In these patients, transient and reversible visual symptoms were noted in the first week, with a negative workup for stroke or transient ischemic attack in all cases.^[3] A larger series of 2,069 patients, undergoing radiofrequency catheter ablation for AF, saw a 2.3% incidence of post-procedure headaches, with new-onset definite migraines described in 1.1% of patients.^[5] Another study did find an association between new or worsening migraine symptoms and silent cerebral infarcts on brain MRI after AF ablation, which suggest thromboembolism and/or hypercoagulability may play a role in the development of post-procedure migraines.^[8] In fact, in this study, therapeutic levels of warfarin anticoagulation maintained during the peri-procedural period were associated with freedom from migraine. Specifically, it is hypothesized that IASD, similar to a native patent foramen ovale, can result in paradoxical embolism of platelets, thrombin and other substances that might contribute to the pathogenesis of migraine.^[9]

Cryoballoon AF ablation is performed using a larger transseptal sheath (12 French inner diameter, as opposed to 8 or 8.5 French for radiofrequency AF ablation), which may be associated with a higher risk of persistent post-procedure IASD.^[10] In a study of 87 consecutive

patients followed for three months after cryoballoon ablation, 8% reported new symptoms of headache with ocular symptoms such as scotoma.^[4] Most symptoms had disappeared when patients were reevaluated in the outpatient clinic three months after the ablation procedure. To the extent that the larger transseptal hole may allow for a greater propensity for thrombo-embolism and potentially migraine symptoms, anticoagulation strategies such as uninterrupted and therapeutic pre-procedure oral anticoagulation and intravenous heparinization prior to transseptal puncture, may be even more important for cryoballoon AF ablation than for radiofrequency AF ablation cases. Interestingly, in the study by Mohanty et al., there were no cases of new migraine or silent cerebral infarcts in the cohort that underwent AF ablation with therapeutic INR on the day of the ablation procedure. Pre-procedure warfarin was not utilized in our patient as she opted for an oral anticoagulant that would not require INR monitoring. It is common practice in our institution to suspend anticoagulation with a direct oral anticoagulant such as rivaroxaban 24 to 48 hours pre-procedure, or initiate it postoperatively in patients who have not been previously anticoagulated. This practice is in contradistinction to the management of our patients on warfarin, which is not suspended pre-procedure, and may in retrospect have increased the risk of post-procedure migraine in this patient. Recent data on the use of direct oral anticoagulants during AF ablation suggest that uninterrupted apixaban administration may be a feasible and effective strategy in preventing thromboembolic events without increasing the risk of major bleeding complications.^[11]

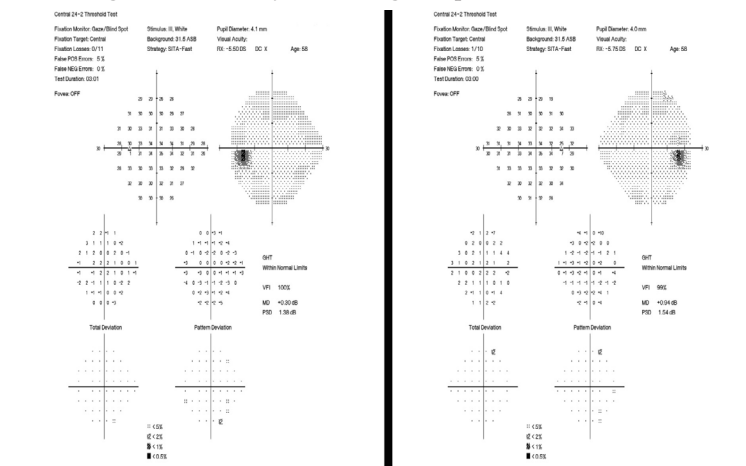


Figure 2: Visual field testing of left (left panel) and right (right panel) eyes post ablation

Conclusions

Migraine with visual aura is an increasingly recognized postoperative complication of AF catheter ablation procedures, and may be related to the presence and size of transseptal sheaths used intraoperatively, and the peri-procedural anticoagulant regimen. Neuroimaging and a thorough ophthalmologic examination are necessary to rule out potential thromboembolic and/or vascular causes in patients presenting with acute visual disturbances post ablation.

Disclosures

None.

References

1. Wilber David J, PapponeCarlo, NeuzilPetr, De PaolaAngelo, MarchlinskiFrank, NataleAndrea, MacleLaurent, DaoudEmile G, CalkinsHugh, HallBurr, ReddyVivek, AugelloGiuseppe, ReynoldsMatthew R, VinekarChandan,

- LiuChristine Y, BerryScott M, BerryDonald A. Comparison of antiarrhythmic drug therapy and radiofrequency catheter ablation in patients with paroxysmal atrial fibrillation: a randomized controlled trial. *JAMA*. 2010;303 (4):333–40
2. Packer Douglas L, KowalRobert C, WheelanKevin R, IrwinJames M, ChampagneJean, GuerraPeter G, DubucMarc, ReddyVivek, NelsonLinda, HolcombRichard G, LehmannJohn W, RuskinJeremy N. Cryoballoon ablation of pulmonary veins for paroxysmal atrial fibrillation: first results of the North American Arctic Front (STOP AF) pivotal trial. *J. Am. Coll. Cardiol*. 2013;61 (16):1713–23
 3. Chilukuri Karuna, SinhaSunil, BergerRonald, MarineJoseph E, ChengAlan, NazarianSaman, ScherrDaniel, SpraggDavid, CalkinsHugh, HenriksonCharles A. Association of transeptal punctures with isolated migraine aura in patients undergoing catheter ablation of cardiac arrhythmias. *J. Cardiovasc. Electrophysiol*. 2009;20 (11):1227–30
 4. Jordaens L, JanseP, Szili-TorokT, Van BelleY. Migraine accompagnée after transeptal puncture. *Neth Heart J*. 2010;18 (7-8):374–5
 5. Noheria Amit, RoshanJohn, KapaSuraj, SrivathsanKomandoor, PackerDouglas L, AsirvathamSamuel J. Migraine headaches following catheter ablation for atrial fibrillation. *J Interv Card Electrophysiol*. 2011;30 (3):227–32
 6. Pison Laurent, PeetersPim, BlaauwYuri, VernooyKevin, KumarNarendra, PhilippensSuzanne, CrijnsHarry J, VlaeyenJohan, SchoenenJean, TimmermansCarl. Headache during cryoballoon ablation for atrial fibrillation. *Europace*. 2015;17 (6):898–901
 7. Linhart Markus, BellmannBarbara, Mittmann-BraunErica, SchrickeJan W, BitzenAlexander, AndriéRené, YangAlexander, NickenigGeorg, LickfettLars, LewalterThorsten. Comparison of cryoballoon and radiofrequency ablation of pulmonary veins in 40 patients with paroxysmal atrial fibrillation: a case-control study. *J. Cardiovasc. Electrophysiol*. 2009;20 (12):1343–8
 8. Mohanty Sanghamitra, MohantyPrasant, RutledgeJ Neal, Di BiaseLuigi, YanRachel Xue, TrivediChintan, SantangeliPasquale, BaiRong, CardinalDeb, BurkhardtJ David, GallinghouseJoseph G, HortonRodney, SanchezJavier E, BaileyShane, HranitzkyPatrick M, ZagrodzkyJason, Al-AhmadAmin, NataleAndrea. Effect of catheter ablation and periprocedural anticoagulation regimen on the clinical course of migraine in atrial fibrillation patients with or without pre-existent migraine: results from a prospective study. *Circ Arrhythm Electrophysiol*. 2015;8 (2):279–87
 9. Saravanan Palaniappan, LangChristopher, DavidsonNeil. Migraine following trans-septal access for catheter ablation of cardiac arrhythmias. *Headache*. 2009;49 (7):1065–7
 10. Chan Ngai-Yin, ChoyChi-Chung, LauChun-Leung, LoYing-Keung, ChuPui-Shan, YuenHo-Chuen, MokNgai-Shing, TsuiPing-Tim, LauSuet-Ting. Persistent iatrogenic atrial septal defect after pulmonary vein isolation by cryoballoon: an under-recognized complication. *Europace*. 2011;13 (10):1406–10
 11. Di Biase Luigi, LakkireddyDhanujaya, TrivediChintan, DenekeThomas, MartinekMartin, MohantySanghamitra, MohantyPrasant, PrakashSameer, BaiRong, ReddyMadhu, GianniCarola, HortonRodney, BaileyShane, SigmundElisabeth, DerndorferMichael, SchadeAnja, MuellerPatrick, SzoelloesAtilla, SanchezJavier, Al-AhmadAmin, HranitzkyPatrick, GallinghouseG Joseph, HongoRichard H, BeheirySalwa, PüererfellnerHelmut, BurkhardtJ David, NataleAndrea. Feasibility and safety of uninterrupted periprocedural apixaban administration in patients undergoing radiofrequency catheter ablation for atrial fibrillation: Results from a multicenter study. *Heart Rhythm*. 2015;12 (6):1162–8