JAFIB®

Original Research

Journal of Atrial Fibrillation

www. jafib.com

Ablation of "Background Tachycardia" in Long Standing Atrial Fibrillation: Improving the Outcomes by Unmasking a Residual Atrial Fibrillation Perpetuator

José Carlos Pachón-M, Enrique I Pachón-M, Tomas G Santillana P, Tasso Julio Lobo, Carlos Thiene C Pachón, Juán Carlos Pachón-M, Remy Nelson Albornoz V, Juán Carlos Zerpa A, Felipe Ortencio, Mauricio Arruda

Institutional review board statement: The study was reviewed and approved by theinstitutional review boards of Sao Paulo Cardiology Institute (IDPC) and Sao Paulo University (USP).

Abstract

Background: Catheter ablation of long-standing persistent AF (LSAF) remains challenging. Since AF-Nest (AFN) description, we have observed that a stable, protected, fast source firing, namely "Background Tachycardia"(BT), could be hidden beneath the chaotic AF. Following pulmonary vein isolation (PVI)+AFN ablation one or more BT may arise or be induced in 30-40% of patients, which could be the culprit forAF maintenance and ablation recurrences.

Methods and Results: We studied 114 patients, from 322 sequential LSAF regular ablations, having spontaneous or induced residual BT after EGM-guided PVI+AFN ablation of LSAF; 55.6±11y/o, 97males (85.1%), EF=65.5±8%, LA=42.8±6.7mm. Macroreentrant tachycardias were excluded. Pre-ablationAF 12-leads ECG Digital processing(DP) and spectral analysis(SA) was performed searching for BT before AF ablation and its correlation with BT during ablation.After PVI, 38.1±9 AFN sites/patient and 135 sustained BTs (1-3, 1.2±0.5/patient) were ablated. BT cycle length(CL) was 246.3±37.3ms. In 79 patients presenting suitable DP for SA, the BT-CL was 241.6±34.3ms with intra procedure BT-CL correlation r=0.83/p<0.01. Following BT ablation, AF could not be induced. During FU of 13→60 months(22.8±12m), AF freedom for BT RF(+) vs. BT RF(-) groups were 77.9% vs. 56.4% (p=0.009), respectively. There was no significant complication.

Conclusions: BT ablation following PVI and AFN ablation improved long-term outcomes ofLSAF ablation. BT is likely due to sustained microreentry, protected during AF by entry block. BT can be suspected by spectral analysis of the pre-ablation ECG and is likely one important AF perpetuator by causing electrical resonance of the AFN. This ablation strategy warrants randomized, multicenter investigation.

Background

Despite great progress, the long-term outcomes of catheter ablation for long standing atrial fibrillation (LSAF) remain suboptimal [1],[2]. Pulmonary vein isolation (PVI) [3],[4] is recognized as the cornerstone for paroxysmal atrial fibrillation (AF) ablation [5],[6],[7] but insufficient as a stand-alone ablation approach for LSAF [8],[9].The adjunct of linear ablation lesion sets [10],[11],[12]; ablation of complex fractionated atrial electrograms (CFAE) [13],[14]; extensive ablation including the left atrial (LA) posterior wall [15], superior vena cava (SVC) [16], coronary sinus and LA appendage or even vagal denervation [17],[18] may improve outcomes slightly but compromises procedural complexity and safety [19],[20],[21].

We have found that the AF Nests (AFN) ablation had a favorable impact on the long-term outcome after a single procedure [22],[23]. It decreased overall recurrences as compared to our conventional PV antral isolation plus CFAE ablation [24]. Interestingly, following PVI and AFN ablation,most recurrences are caused by an organized, typically fast atrial tachycardia. This residual tachycardia often appears as a transitional rhythm during AF ablation upon its organization or termination,[Figure 1]

By using spectral analysis with Fast Fourier Transform (FFT) we have found that this tachycardia is present during AF, before ablation,[25] which we have named "Background Tachycardia" (BT) [22],[26],[27]. Rapid atrial pacing following PVI and AFN ablation can also commonly induce one or more of these organized atrial tachycardias. By studying this tachycardia with spectral mapping we have found that it commonly arises from an AFN exhibiting a specific case of focal microreentry, (fractal microreentry[25]), characterized by entry block, which ensures its maintenance during AF without overdrive reversion by the AF itself. In this study, we evaluated the long-term outcome of BT ablation as an adjunct to PVI plus substrate modification by AFN ablation in patients with LSAF. In addition, we assessed the feasibility of identifying the BT by digital processing and spectral analysis of the AF on the surface electrocardiogram (ECG) prior to the ablation procedure.

Key Words

Arrhythmia, Atrial fibrillation, Ablation, Spectral Analysis, Rotors, AF-Nest.

Corresponding Author
Jose Carlos Pachon-Mateos,
pachon@usp.br
Professor, Director, HCor Arrhythmias Service Juquis St, 204/41-A – Indianapolis – Sao Paulo – Brazil – 04081010
Telephone: +55-11-78384203

Patients and methods

Study Population

In this prospective study were enrolled 114 consecutive patients with

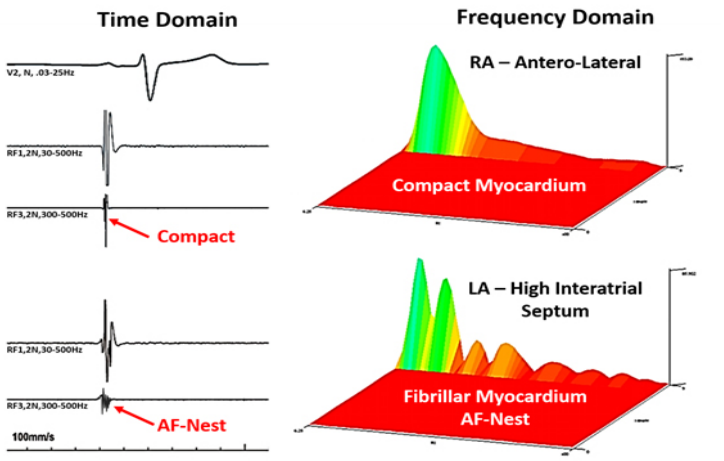

Figure 1: Features of the compact (above) and fibrillar myocardium (below: AF-Nest 22,27,30) in the time domain (left) and in the frequency domain – spectral analysis by FFT (right). In this study, both methods were used after PVI.

symptomatic persistent (AF that lasts longer than 7 days, including episodes that are terminated by cardioversion, either with drugs or by DC cardioversion, after 7 days or more) or LSAF (continuous AF lasting for ≥1 year when it was decided to adopt a rhythm control strategy), refractory to conventional medical treatment, in whom it was possible to induce at least one BT following PVI plus AFN ablation. The group encompasses patients with persistent and long-standing persistent AF with a mean history duration of 13.5±14.3 months, ranging from 2 to 62 months.Written informed consent was obtained from all patients prior to the procedure.

Mapping and Ablation Protocol

The procedures were performed under general anesthesia. A duodecapolar catheter was placed in the CS. Transeptal access was guided by transesophageal echocardiography. 3-D Electroanatomic mapping system (EnSiteNavX - St. Jude Medical) and a circular multi-electrode catheter were used for EGM-guided PVI. An open irrigation ablation catheter(Thermo-cool, Biosense Webster or Biotronik; 30W/45oC/17ml/minute) was used for radiofrequency (RF) delivery. Subsequently, if required, electrical cardioversion was performed to restore sinus rhythm.Following PVI, AFN sites were ablated being identified in sinus rhythm either by, conventional recording with filter settings of 100 and 300 to 500Hz pass-band to bipolar EGMs or by using a computerized spectrometer[22],[27],[28], [Figure 2].

Background Tachycardia (BT)

Following PVI plus AFN ablation, at least one BT was induced by decremental atrial pacing down to cycle length (CL) of 200ms from the distal coronary sinus (CS) or right atrium (RA). Macroreentrant atrial tachycardias were excluded. Only microreentry with a confirmed entry block was considered as BT,according to the following criteria:

1. Presence of entry block (unresponsive to overdrive suppression);
2. Radial distribution reproduced by pace-mapping;
3. Presence of significant isoelectric line in all ECG leads and;
4. Focal ablation.

Table 1: BT ablation outcome. AA: antiarrhythmic drugs; *Kaplan-Meier Cumulative Survival.

BT Ablation Outcome	N	%	Success without AA (60 months*)	P
RF Termination, RF(+) group	62	54.4	77.9%	
Non-RF Termination, RF(-) group	52	45.6	56.4%	
Spontaneous Reversion	22	19.2		p=0.009
External Cardioversion	15	13.2		
Mechanical Reversion	15	13.2		

Ablation Endpoint

Our stepwise ablation strategy is presented in [Figure 3]. The procedure was terminated due to:

Inability to re-induce sustained tachyarrhythmia;Successful BT ablation orUnsuccessful BT ablation requiring electrical cardioversion.

Post-Procedure Follow-up

All patients were followed in our AF clinics as well as via telephone and Internet. Strict rhythm monitoring was obtained, including ECG and 24h-Holter at 1, 3, 6 months and then yearly or whenever there was AF/AT recurrences and/or symptoms. The follow-up (FU) ranged from 13 to 60 months with a mean of 22.8 ± 12 months.

Spectral Analysis of ECG Prior to Ablation

Seventy-nine of 114 patients (69.3%) had a suitable ECG for digital QRS-T wave subtraction(≥5 minutes of 12-lead noise-free ECG in AF without aberrancy, ventricular ectopic beats and significant pauses), [Figure 5]. A customized system was used for QRS-T averaging, digital subtraction and spectral analysis of the isolated atrial activity. The fundamental frequency achieved by integrating the FFT of each 12-leads was compared with the BT frequency obtained after PVI plus AFN ablation.

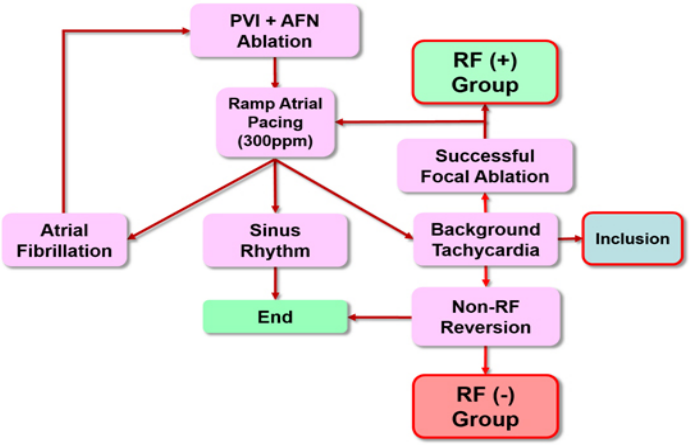

Figure 2: Study design. Only patients in whom it was possible to induce and characterize at least one BT following PVI and AFN in the same session were included. The cases were followed and compared according to RF reversion, RF(+) group or non-RF reversion, RF(-) group.

Statistical Analysis

Quantitative data are shown as the mean value ± standard deviation.Normality was evaluated by the Kolmogorov-Smirnov test. Paired-samples two-tailed t-test was applied to establish comparisons between continuous data before and after BT ablation.Survival analysis was obtained with Kaplan-Meier. A Pearson's correlation was applied to test the real BT frequency with the suspected BT frequency obtained by spectral analysis of the ECG before ablation. Statistical analysis was performed using IBM SPSS StatisticsVersion 19 software. All values were considered statistically significant at two-tailed value less than 0.05.

Results

From a cohort of 322 consecutive persistent and long standing

Table 2: Location of the focus of the last BT defined by RF BT interruption and sinus rhythm recovery. Typically, they were found in the AFN areas. ND: not defined / not mapped (cases with spontaneous or mechanical reversionby the mapping catheter or who were cardioverted due to prolonged procedure). See Figure 5 for more details (the cells' colors show the BT lication in the map) . IA: interatrial.

Atrium	Site	N	%
RA41 (35.9)	RA wall	26	22.8
	RA AV node	3	2.6
	RA IA septum	12	10.5
LA 40 (35.1)	LA wall	7	6.1
	LA IA septum	13	11.4
	LA PV	17	14.9
	CS ostium	3	2.6
Not Defined		33	28.9
Total		114	100.0

atrial fibrillation ablation, after isolation of the pulmonary veins and AF-Nests ablation, it was possible to induce a tachycardia compatible with BT in 114(35.4%) subjects, 97 males (85.1%).The mean age was 55.6±11 (24-77) years. The mean left atrial (LA) diameter was 42.3±7 (27-67) mm, and the mean left ventricle (LV) ejection fraction by transthoracic anteroposterior echocardiographyview was 65.5±8 (47-76%). The AF-Nests were most frequent in the PV antrum, at the interatrial septum, in the left posterior septal space, in the cristaterminalis, at the superior vena cava insertion and close to the coronary sinus ostium.

PVI and AFN ablation

EGM-guided PVI was achieved in all patients. Subsequently, filtered conventional or spectral mapping was applied to guide AFN ablation (mean of 38.1±9 AFN per patient). Following PVI and AFN ablation, 135 BT were induced, 1.2±0.5 per patient, ranging from one to three, one in 92 patients (80.7%), two in 14 patients (12.3%) and three in 8 patients (7%).The ablation BT outcomes are presented in [Table 1].

BT Ablation

BT was successfully ablated in 62 patients (54.4%), RF(+)group. On the other hand, BT ablation could not be completed in 52 patients (45.6%), RF(-)group due to spontaneous reversion while mapping (22); mechanical reversion by the catheter (15) or electrical cardioversion due to prolonged procedure time (15), [Table 1].

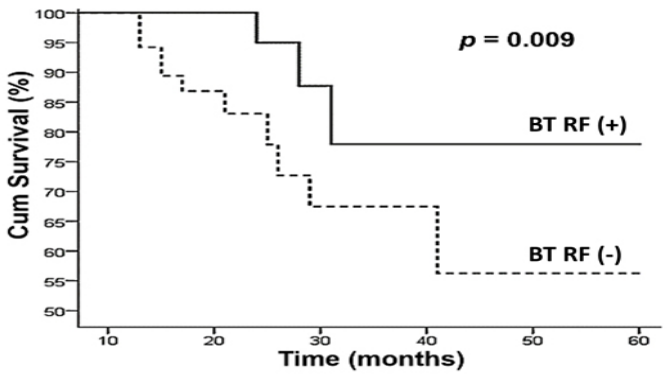

Figure 3: Cumulative Kaplan-Meier survival curves comparing the outcome (up to 60 months) of group RF(+) (reverted by RF) with group RF(-) (non-RF reversion).

The mean fluoroscopy time was 49.4±18 minutes and the average total procedure time was 4.3±1.4 hours. There were no significant major complications. Two patients exhibited BT in the atrioventricular (AV) node region successfully ablated but leading to transient 2nd degree, type I AV block in one and transient complete AV block in the other. Groin hematomas occurred in three patients and arterial-venous fistula, treated by ultrasound transducer compression, occurred in one patient.

After a mean follow-up of 22.8±12 months (13-60 months) AF free survival, defined as no AF or BT without antiarrhythmic drugs was 77.9% in RF(+) Group and 56.4% in the RF(–) Group (p=0.009), [Figure 4].

Researching for the BT before Ablation by Spectral Analysis of the ECG

The BT frequency obtained by digital processing and spectral analysis of the extracted atrial activity on a pre-ablation ECG was compared with the actual spontaneous or induced BT frequency

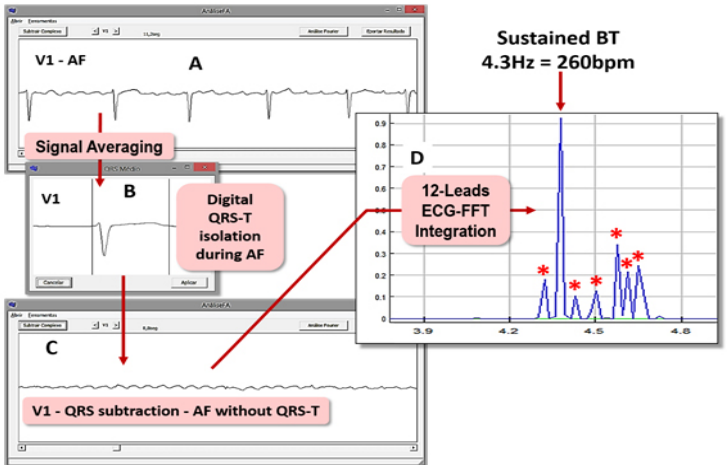

Figure 4: Methodology to search the BT in the ECG before ablation. At the end, it allows the spectral analysis of isolated atrial activity from the conventional ECG. A: standard ECG; B: pure QRS-T without AF, obtained by digital signal averaging of the whole ECG; C: QRS-T subtraction from the tracing A obtaining a clean and continuous AF without ventricular activity; D: the spectrum of "isolated AF" is obtained by applying Fourier in C and integration of the 12-ECG leads. In this example, there is a clearly dominant peak that matches a tachycardia with a frequency of 4.3Hz (231ms/260bpm) and six other non-sustained (*). The main one is likely one AF perpetuator in this case, keeping the AFN resonating under high frequency stress.

by endocardial mapping during ablation, [Figure 5]. Only stable ECG,suitable for digital processing (lasting five minutes or more, free of noise, significant pauses, ventricular ectopic beatsand aberrancy),obtained in 79 patients (69.2%), were included in this analysis.There was a high positive correlation in predicting BT CL from the surface ECG (2-tailed Pearson positive correlation coefficient r = 0.83, p<0.01), [Figure 6].

Discussion

In this prospective study, we describe an ablation strategy for patients with LSAF. In addition to PVI, it includes the adjunctive ablation of AFN and spontaneous or inducible specific residual atrial tachycardia, namely BT.

In this study BT was considered when stable rapid atrial tachycardia was obtained under the following conditions:

1. During AF ablation the atrial rhythm often evolved to a rapid

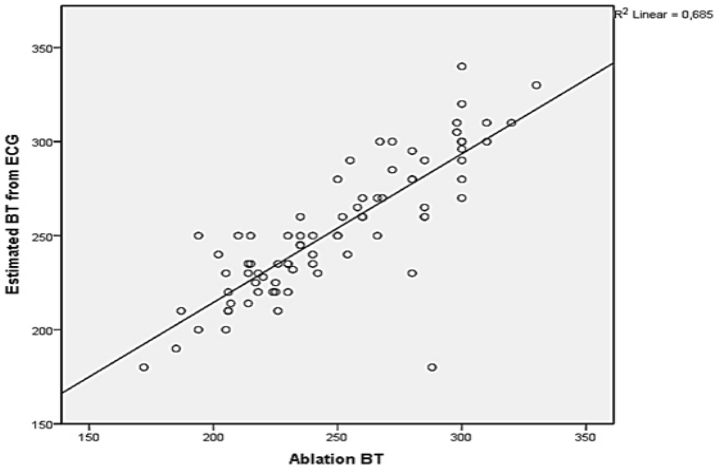

Figure 5: **The mean BT frequency by ECG analysis before AF ablation was 253.3±35.6bpm (CL=241.6±34.6ms) and the mean BT frequency after AF ablation was 249.1±37.3bpm (CL=246.3±37.3ms) with a high Pearson 2-tailed positive correlation coefficient r = 0.83, p<0.01).**

and regular tachycardia. From that moment on, although we no longer had FA, we still had a sustained atrial tachycardia;

2. In many cases, at the end of ablation, having the sinus rhythm recovered, the rapid atrial stimulation (up to 300ppm) even no longer inducing AF, it was able to reproduce a fast and sustained regular atrial tachycardia.

From this moment onwards, having excluded atrial flutter and gross atrial macroreentry tachycardias, we compared this tachycardia with the dominant frequency obtained by spectral analysis using FFT applied to the pure AF signal (after QRS-T subtraction) before ablation. This spectral analysis, prior to AF ablation, clearly indicates that there is at least one organized dominant tachycardia under in the AF environment. The most interesting is that the frequency of this tachycardia had a high positive correlation with the residual tachycardia found after ablation and considered BT in this study. This suggests that this tachycardia probably exists before ablation, hereafter being called "Background Tachycardia". Even more interesting is the fact observed in this study that the attempt to ablate this BT seems to greatly increase the long-term success rate of the long-lasting AF ablation.

In this study, we found that these tachycardias usually present the following features:

1. High frequency,
2. Entry block characterized by the absence of "reset" and the impossibility of interference or overdrive reversion. This property shows that this tachycardia is protected by an entry block which allows the tachycardia to exist even during AF, preventing it to be reverted by the large number of stimuli under the AF electrical storm,
3. Focal origin suggested by electroanatomical mapping, by means of entrainment and punctual elimination, without the need of blocking lines;
4. Surface ECG with isoelectric line suggestive of focal tachycardia rather than macroreentry [Figure 7],
5. The origin of focal microreentry protected with entry block is also suggested by the impossibility of reversion by overdrive, but by the immediate stopping with cardioversion, suggesting that it is not originated by hyperautomatism.

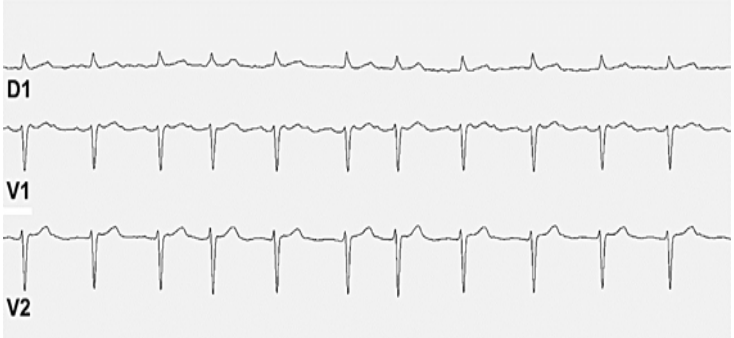

Figure 6: **Recurrence three months after ablation. Usually the complaint of palpitation with rapid and irregular pulse leads to the diagnosis of AF. Indeed, D1 and V2 leads can be confused with AF. However, careful analysis of V1 suggests a regular fast atrial tachycardia instead of AF (typical of BT). This diagnosis is fundamental, as the treatment must target BT focal ablation rather than a new conventional AF ablation.**

Tachycardias with BT features were induced only in 114 (35.4%) of 322 LSAF cases. This means that PV isolation and AF-Nests ablation was probably sufficient to eliminate a great number of non-discovered BTs. Interestingly, BT with similar rates could be suspected on surface ECG during AF, prior to ablation, by spectral analysis of the surface AF recording without the QRS-ST complex. Successful BT ablation had a significant impact on long-term procedural efficacy with a 2-year AF freedom. The lack of statistical significance between the two groups (RF+ versus RF-) in the variables known to influence the clinical outcome reinforces this hypothesis, [Table 2].

Additionally, it is conceivable that AF-Nests ablation contributed to the favorable outcomes as even patients in whom we could not eliminate the BTs, experienced no recurrences in 82% at 2 years post ablation. As the study suggests, those atrial sites exhibiting AF-Nests may also harbor BTs. This could reflect at least a transient modification or elimination of the critical substrate responsible for initiation and maintenance of AF, even without complete PVI or even with PV reconnection. Undeniably, further substrate and/or modulators may emerge over time leading to AF and/or BTs recurrences.

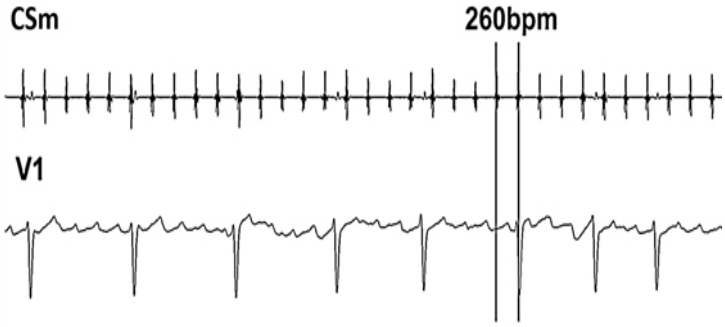

Figure 7: **Regular tachycardia induced after PVI and AFN ablation in the same patient of the Figure 4. Instead of AF, it was induced a very rapid atrial tachycardia matching the frequency predicted by the ECG spectral analysis, before ablation. It suggests that this tachycardia existed before ablation and is likely responsible for the maintenance of AF (BT). Prior the ablation, the noise caused by the AFN resonance precludes the visualization and mapping of this tachycardia. CSm: recording of atrial activity within the coronary sinus.**

Our concepts of AFN and BT are summarized below since they may contribute to explain or have pathophysiologic implications for the mechanisms of LSAF[22],[29]. Ongoing and future investigations may further solidify these findings in that the AFN and BT are

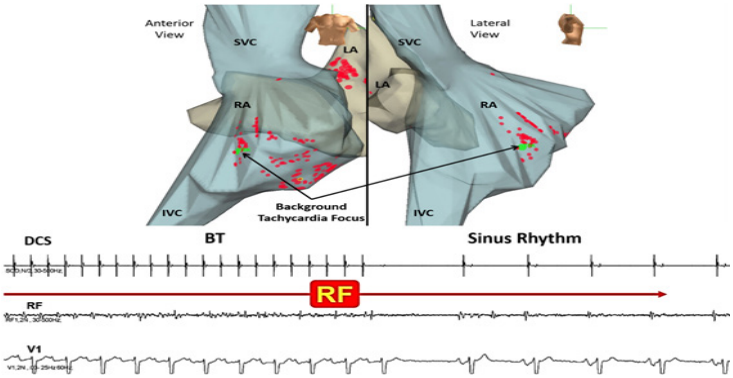

Figure 8: **Upper: 3-D geometric endocardial reconstruction of the left and right atria by electro-anatomic mapping. The red dots represent AFNs ablated with RF. There is an AFN group in the anterior-inferior wall of the RA nesting the BT focus reverted by RF ablation in a very small area (focal ablation). Lower: BT reversion during RF application in the RA lower anterior region as shownon the electroanatomic mapping(upper).**

important players inthe LSAF physiopathology.

Background Tachycardia (BT)

The assessment of BT electrophysiological properties and its structural correlates is challenging and was not the purpose of this study. However, typically a BT [Figure 7] consists of a fast (249.1±37.3bpm, CL=246.3±37.3ms), focal microreentrant tachycardia exhibiting entrance block due to lack of resetting and overdrive suppression. Rarely, by using high pacing output (20 mA/1.5ms) directly over a BT site, we could revert it. This seems to work as an AFN micro-cardioversion. Nevertheless, this was not evaluated systematically ever since our purpose was to revert the BT by ablation.BT spectral analysis suggests that it is formed by a specific type of microreentry (fractal microreentry)explaining its main feature, the entry block.

It is likely that one or more unrecognized BTs coexist during AF and may even play a "clock" role, protected by entry block, perpetuating AF. Interestingly, there was a significant distribution of BTs in RA 35.9% vs. 35.1% in LA. However, since PVI and AFN ablation in the LA were performed prior BT induction, it is probable that some LA BTs were unintentionally eliminated underestimating the actual number of BTs in the LA. However, the presence of BTs in RA suggests that this chamber should be systematically treated in LSAF ablation, [Figure 9].

AFNests Ablation

The AFNwere described in the nineties, even in the normal heart, by scanning the atrial endocardium with on-line spectral analysis in sinus rhythm[22],[27],[30],[31],[32].Recently, their relationship with the neuro-myocardial interface was confirmed[33] as suggested by the original study[22].This technique revealed that AFN are atrial clusters of fibrillar myocardium, which main feature is cell-to-cell electrical disconnection.AFN are different from CFAEs[28]. They exhibit a heterogeneous, multi-peak frequency spectra in sinus rhythm. The AFN favor anisotropic conduction[34],are possible sources for microreentry and electrical resonance[35] and may give us some insight on why AF can occur in apparently normal hearts without fibrosis, in which are clearly related to the insertion of the veins (pulmonary veins, coronary sinus and cava veins) and to the neuro-endocardial interface[27],[33],[36],[37]. In all these areas, a significant intersection and blending of different conductive and non-conductive tissues gives rise to the very distinct AFN spectral properties.Despite potentially anisotropic, there is normal conduction through the AFN during sinus rhythm; where as at faster rates they trigger repetitive responses (electrical resonance[35]) likely due to progressive micro-reentries(fractal microreentry) creating a self-limited but an essential AF substrate even in the absence of disease[27].The spectral analysis has endorsed that the AFN electrical resonance is the main responsible for the irregular and intense electrical noise visible on the baseline AF ECG[22],[35].Nevertheless, as the resonance is a self-limited decremental oscillatory phenomenon, it may account for paroxysmal AF, however long-standing and permanent AF require one or more continuous, uninterrupted driver such as BT, suspected on pre-procedure ECG during AF and showed after, during ablation, [Figure 5]. The electrical noise caused by AFN resonance precludes the BT visualization, but with progressive AFN ablation,the noise decreases or disappears allowing the BT visualization.Extensive AFN ablation makes the AF reinduction very difficult. Following PVI and unintentional AFN ablation during AF, the rhythm may be progressively organized and may convert into a fast, regular residual atrial tachycardia, here described as "Background tachycardia", [Figure 1].

Uncovering the BT in the ECG before Ablation

Based on earlier observations of BT behavior as a potentialAF sustainer, we postulated that it could be extracted from the previous conventional ECG with AF. This was achieved by using spectral analysis of the isolated atrial activity extracted from the AF ECG before ablation. With a specific methodology and software[25], [Figure 5], we found that the anticipated BT frequency had a strong positive correlation with the frequency of actual BT induced after ablation with 2-tailed Pearson correlation coefficient equal to 0.83 ($p<0.01$) having the normality confirmed with Kolmogorov-Smirnov test, [Figure 6]. This is a significant indication that BT actually coexists during AF, protected by entry block, and probably plays a role like a "clock" perpetuating the AF. These findings show that, under the apparent chaotic LSAF atrial activity, there is at least one organized fast tachycardia, [Figure 5], in which the spectral analysis shows more six ancillary and non-sustained BTs contributing to the complex

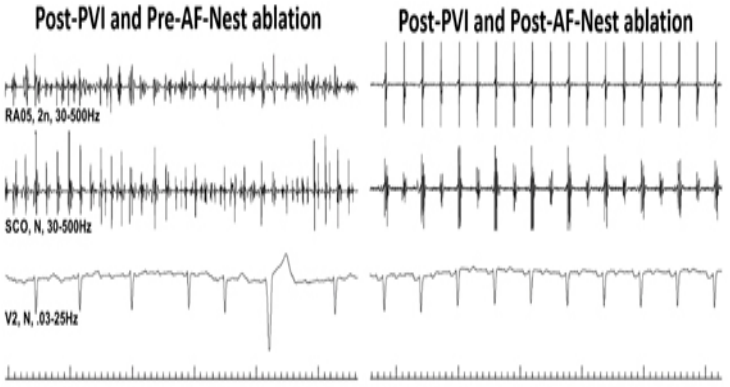

Figure 9: **Tracings of the same patient before and after AFN ablation. Instead of reverting the AF, the ablation resulted in a progressive rhythm organization, exposing BT after eliminating the resonance noise. The observation of this group of patients suggests that this type of tachycardia exists during AF before ablation, protected by an entry block. It works as one AF maintainer or clock. SCO: sinus coronary ostium.**

AF electrical activity. The interaction of these very fast tachycardias with the dynamic changes of the atrial refractory period may cause intermittent spiral activation, possibly given rise to"rotors" and "spiral waves".

AF Physiopathology Based on Spectral Study and Background Tachycardia

The [Figure 10] shows a model of the possible participation of at least one BT in the AF physiopathology.

Insights About the Futur of AF Ablation

BT facilitates the understanding of the physiopathology of AF using spectral analysis concepts. In addition, we are exhaustively seeking for a way to identify the BTs prior to AF ablation, during AF. When this became possible, it is likely that we will be able to revert a long-lasting AF with focal ablation and only then, in sinus rhythm, to perform the PVs isolation, simplifying the procedure of persistent and long-lasting AF. Our expectation is that the evolution of the technology around this concept could improve the understanding of the AF physiopathology, simplify the ablation of refractory AF cases, improve the outcome for the patient and reduce the effort of the electrophysiologist.

Relationship with BT to Rotors and Microreentryduring AF

Although beyond the scope of this study, it isplausible that the BT isone driving source for LSAF as described by Jalife[38],[39], and Narayan[40], expressed as rotors with AF termination by ablating these stable presumed sources. The ability of AF re-induction following rotor ablation is not yet well established clinically. In our study, following AFN and BT ablation, AF is typically not inducible. We have observed that some BT, especially the ones with high frequency, may show a behavior compatible with rotors. It may be due to the perifocal atrial refractory period dynamics, promoting constant, rapid and progressive changes in the perifocal activation leading to "spiral activations".

Our approach precludes mapping and ablation of BT before PVI and AFN ablation whereas a computerized system allows mapping-guided rotor ablation as utilized in the CONFIRM trial[40]. However,

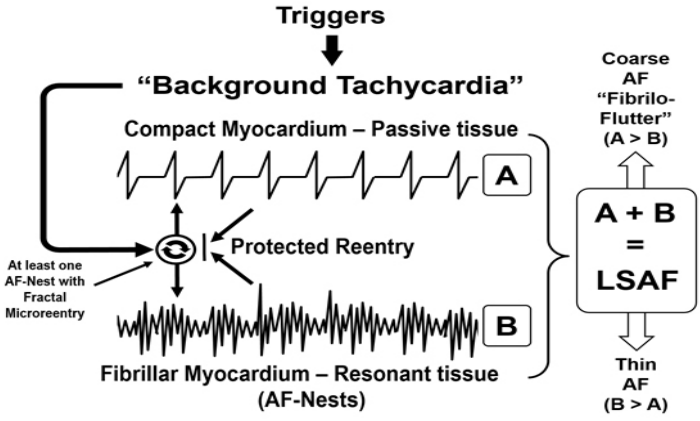

Figure 10: AF physiopathology based on the BT and AF-Nests. A fast BT keeps the "Fibrillar Myocardium" (AF-Nests) resonating with very fast and disorganized electrical activity (B) while the "Compact Myocardium" shows a regular and organized response (A). LSAF results from the sum of all these electrical activities (A+B). A "coarse AF" may appear if A>B and "thin AF" may arise case B>A and/or by the presence of more than one BT. The BT survival is assured by the entrance block and the LSAF and even the permanent one may be reinforced by the presence of more than one BT.

it brings new mechanistic insight in AF physiopathology.Another very likely association may exist between BT and focal sources or microre entry recently described by Haissaguerre and colleagues by utilizing a high resolution, 3-D body surface mapping system "ECGI" integrated with a pre acquired cardiac CT scan[41]. As we have described, the numbers and distribution of BT are similar to their findings using ECGI during AF.

Even though both computerized mapping systems may allow ablation during AF, our approach includes ablation of other critical tissue / substrate such as the AFN sites in addition to BT as driving sources, accounting for our satisfactory long-term outcomes.

Study Limitations

The incidence of BT following ablation of LSAF may be greatly dependent on the actual ablation strategy and stimulation protocol. Since we performed PVI and extensive AFN ablation, BT could only be observed in 35.4% of 322 patients. The incidence of BT could have been higher without AFN ablation (note that BT was apparently present on pre-ablation ECG in all patients with suitable ECG, 69.3%) or lower incidence with a less aggressive stimulation protocol. We were fairly aggressive by including rapid atrial pacing up to 300 ppm. The lack of a standard protocol for AF induction post AF ablation is a limitation of this and others AF ablation studies.

Future software versions of the ECG spectral analysis will overcome current limitations requiring long, stable and low noise recording, without ventricular ectopic beats, aberrancy or major oscillations of RR, QT intervals and baseline, which precluded ECG analysis in 30.7% of patients in this initial trial.

In addition, the adjunct of AFN ablation to PVI may have accounted to a fairly satisfactory ablation outcome even in the RF(-) group with incomplete BT mapping and ablation. The AFN mapping without spectroscopy may be less accurate, however, as it was a complement to PVI and under specific filter settings, we believe that this presumed limitation has been irrelevant.

An implantable loop recorder was not used to assess the outcome of our ablation strategy. All patients were followed up by the conventional resources utilized in most studies, irrespective of BT ablation results.

Even though the BT concept here described may be the critical driving source for LSAF, our mapping and ablation strategy lack the ability to target BT during AF.

Unfortunately, we still cannot accurately identify the BT during AF, however it was possible to find that the spectral analysis of pure AF signal (without QRS-T) prior to ablation, has a dominant frequency with a high positive correlation with the BT frequency obtained after ablation, suggesting that they could be the same tachycardia. At this moment, we are working deeply on this issue, because when to be possible to identify the BT during AF, we could start the long-standing AF ablation by a focal ablation, reverting the AF and isolating the PVs subsequently.

Additionally, this study did not have the merit of analyzing the pathological characteristics of the foci-related tissues as well as the voltage mapping. These questions will be extremely important in the next studies.

Conclusions

The adjunct of Background Tachycardia ablation to PVI and AF-Nests ablation was safe and improved long-term results of long-standing AF ablation. Background Tachycardia is likely due to sustained microreentry, protected during AF by entry block. It

can be revealed during AF by ECG spectral analysis and is likely one important driver that perpetuates AF by causing resonance of specific tissues, namely the AF-Nests. Our findings may bring new insight into the physiopathology of long-standing AF. This ablation strategy warrants randomized, controlled, multicenter investigation.

Conflict Of Interests

None.

Disclosures

None.

References

1. Cappato Riccardo, CalkinsHugh, ChenShih-Ann, DaviesWyn, IesakaYoshito, KalmanJonathan, KimYou-Ho, KleinGeorge, NataleAndrea, PackerDouglas, SkanesAllan, AmbrogiFederico, BiganzoliElia. Updated worldwide survey on the methods, efficacy, and safety of catheter ablation for human atrial fibrillation. Circ Arrhythm Electrophysiol. 2010;3 (1):32–8
2. de Vries L J, AkcaF, KhanM, Dabiri-AbkenariL, JanseP, TheunsD A M J, PetersE, de RuiterG, Szili-TorokT. Clinical outcome of ablation for long-standing persistent atrial fibrillation with or without defragmentation. Neth Heart J. 2014;22 (1):30–6
3. Haïssaguerre M, JaïsP, ShahD C, TakahashiA, HociniM, QuiniouG, GarrigueS, Le MourouxA, Le MétayerP, ClémentyJ. Spontaneous initiation of atrial fibrillation by ectopic beats originating in the pulmonary veins. N. Engl. J. Med. 1998;339 (10):659–66
4. Seshadri Niranjan, MarroucheNassir F, WilberDavid, PackerDouglas, NataleAndrea. Pulmonary vein isolation for treatment of atrial fibrillation: recent updates. Pacing Clin Electrophysiol. 2003;26 (7 Pt 2):1636–40
5. Morady Fred. Treatment of paroxysmal atrial fibrillation by pulmonary vein isolation. Circ. J. 2003;67 (7):567–71
6. Haïssaguerre M, JaïsP, ShahD C, GarrigueS, TakahashiA, LavergneT, HociniM, PengJ T, RoudautR, ClémentyJ. Electrophysiological end point for catheter ablation of atrial fibrillation initiated from multiple pulmonary venous foci. Circulation. 2000;101 (12):1409–17
7. Scanavacca Mauricio Ibrahim, SosaEduardo. [Catheter ablation of atrial fibrillation: techniques and results]. Arq. Bras. Cardiol. 2005;85 (4):295–301
8. Oral Hakan, KnightBradley P, TadaHiroshi, OzaydinMehmet, ChughAman, HassanSohail, ScharfChristoph, LaiSteve W K, GreensteinRadmira, PelosiFrank, StrickbergerS Adam, MoradyFred. Pulmonary vein isolation for paroxysmal and persistent atrial fibrillation. Circulation. 2002;105 (9):1077–81
9. Parkash Ratika, VermaAtul, TangAntony S L. Persistent atrial fibrillation: current approach and controversies. Curr. Opin. Cardiol. 2010;25 (1):1–7
10. Pappone C, RosanioS, OretoG, TocchiM, GugliottaF, VicedominiG, SalvatiA, DicandiaC, MazzoneP, SantinelliV, GullettaS, ChierchiaS. Circumferential radiofrequency ablation of pulmonary vein ostia: A new anatomic approach for curing atrial fibrillation. Circulation. 2000;102 (21):2619–28
11. Oral Hakan, PapponeCarlo, ChughAman, GoodEric, BogunFrank, PelosiFrank, BatesEric R, LehmannMichael H, VicedominiGabriele, AugelloGiuseppe, AgricolaEustachio, SalaSimone, SantinelliVincenzo, MoradyFred. Circumferential pulmonary-vein ablation for chronic atrial fibrillation. N. Engl. J. Med. 2006;354 (9):934–41
12. Lin Yazhou, JuWeizhu, YangBing, ChenHongwu, ZhangFengxiang, LiMingfang, YuJinbo, CaoKejiang, ChenMinglong. Does linear ablation and defragmentation really improve the success rate of persistent AF? Follow-up results and electrophysiological findings from 169 consecutive patients. Int. J. Cardiol. 2013;168 (1):452–7
13. Nademanee Koonlawee, McKenzieJohn, KosarErol, SchwabMark, SunsaneewitayakulBuncha, VasavakulThaveekiat, KhunnawatChotikorn, NgarmukosTachapong. A new approach for catheter ablation of atrial fibrillation: mapping of the electrophysiologic substrate. J. Am. Coll. Cardiol. 2004;43 (11):2044–53
14. De Bortoli Alessandro, OhmOle-Jørgen, HoffPer Ivar, SunLi-Zhi, SchusterPeter, SolheimEivind, ChenJian. Long-term outcomes of adjunctive complex fractionated electrogram ablation to pulmonary vein isolation as treatment for non-paroxysmal atrial fibrillation. J Interv Card Electrophysiol. 2013;38 (1):19–26
15. Pappone Carlo, RosanioSalvatore. Evolution of non-pharmacological curative therapy for atrial fibrillation. Where do we stand today?. Int. J. Cardiol. 2003;88 (2-3):135–42
16. Arruda Mauricio, MlcochovaHanka, PrasadSubramanya K, KilicaslanFethi, SalibaWalid, PatelDimpi, FahmyTamer, MoralesLuis Saenz, SchweikertRobert, MartinDavid, BurkhardtDavid, CummingsJennifer, BhargavaMandeep, DresingThomas, WazniOussama, KanjMohamed, NataleAndrea. Electrical isolation of the superior vena cava: an adjunctive strategy to pulmonary vein antrum isolation improving the outcome of AF ablation. J. Cardiovasc. Electrophysiol. 2007;18 (12):1261–6
17. Scherlag Benjamin J. Re: Vagal denervation and atrial fibrillation inducibility: epicardial fat pad ablation does not have long-term effects. Heart Rhythm. 2006;3 (10):1248; author reply 1248–9
18. Nakagawa Hiroshi, ScherlagBenjamin J, PattersonEugene, IkedaAtsuhsi, LockwoodDeborah, JackmanWarren M. Pathophysiologic basis of autonomic ganglionated plexus ablation in patients with atrial fibrillation. Heart Rhythm. 2009;6 (12 Suppl):S26–34
19. Pappone Carlo, OralHakan, SantinelliVincenzo, VicedominiGabriele, LangChristopher C, MangusoFrancesco, TorraccaLucia, BenussiStefano, AlfieriOttavio, HongRobert, LauWilliam, HirataKirk, ShikumaNeil, HallBurr, MoradyFred. Atrio-esophageal fistula as a complication of percutaneous transcatheter ablation of atrial fibrillation. Circulation. 2004;109 (22):2724–6
20. Saad Eduardo B, RossilloAntonio, SaadCynthia P, MartinDavid O, BhargavaMandeep, ErciyesDemet, BashDianna, Williams-AndrewsMichelle, BeheirySalwa, MarroucheNassir F, AdamsJames, PisanòEnnio, FanelliRaffaele, PotenzaDomenico, RavieleAntonio, BonsoAldo, ThemistoclakisSakis, BrachmannJoannes, SalibaWalid I, SchweikertRobert A, NataleAndrea. Pulmonary vein stenosis after radiofrequency ablation of atrial fibrillation: functional characterization, evolution, and influence of the ablation strategy. Circulation. 2003;108 (25):3102–7
21. Prystowsky Eric N, CammJohn, LipGregory Y H, AllessieMaurits, BergmannJean-François, BreithardtGünter, BrugadaJosep, CrijnsHarry, EllinorPatrick T, MarkDaniel, NaccarelliGerald, PackerDouglas, TamargoJuan. The impact of new and emerging clinical data on treatment strategies for atrial fibrillation. J. Cardiovasc. Electrophysiol. 2010;21 (8):946–58
22. Pachon M Jose C, Pachon MEnrique I, Pachon MJuan C, LoboTasso J, PachonMaria Z, VargasRemy N A, PachonDenilda Q_V, Lopez MFrancisco J, JateneAdib D. A new treatment for atrial fibrillation based on spectral analysis to guide the catheter RF-ablation. Europace. 2004;6 (6):590–601
23. JC Pachon M, EIPachon M. Apparatus and methods for arrhythmia treatment based on spectral mapping during sinus rhythm. USPTO-USA Patent Number US 8216228 B2. United States Patent and Trademark Office Website
24. Arruda Mauricio, NataleAndrea. Ablation of permanent AF: adjunctive strategies to pulmonary veins isolation: targeting AF NEST in sinus rhythm and CFAE in AF. J Interv Card Electrophysiol. 2008;23 (1):51–7
25. JC Pachon M, EIPachon M. Spectral Study of Atrial Fibrillation by Digital QRST Subtraction. USPTO Provisional Patent process No. 61928619. United States Patent and Trademark Office Website. http://patft.uspto.gov/netahtml/PTO/index.html Priority date January 17, 2014. 2014
26. Mateos JC Pachón, Mateos EIPachón, TJ ETLobo. Atrial Fibrillation RF Catheter Ablation Based on the Spectral Mapping of the AF-Nests 2nd ISHNE AF World-Wide InternetSymposium 2007. http://www.ishne.org/vs/2nd-

af-2007/lectures/ing_pachonmateos_jose.html. 2007

27. Mateos José Carlos Pachón, MateosEnrique I Pachón, LoboTasso J, PachónMaria Zélia C, MateosJuán Carlos Pachón, PachónDenilda Queiroz V, VargasRemy Nelson A, PiegasLeopoldo S, JateneAdib D. Radiofrequency catheter ablation of atrial fibrillation guided by spectral mapping of atrial fibrillation nests in sinus rhythm. Arq. Bras. Cardiol. 2007;89 (3):124–34, 140-50
28. Calkins Hugh, KuckKarl Heinz, CappatoRiccardo, BrugadaJosep, CammA John, ChenShih-Ann, CrijnsHarry J G, DamianoRalph J, DaviesD Wyn, DiMarcoJohn, EdgertonJames, EllenbogenKenneth, EzekowitzMichael D, HainesDavid E, HaissaguerreMichel, HindricksGerhard, IesakaYoshito, JackmanWarren, JalifeJose, JaisPierre, KalmanJonathan, KeaneDavid, KimYoung-Hoon, KirchhofPaulus, KleinGeorge, KottkampHans, KumagaiKoichiro, LindsayBruce D, MansourMoussa, MarchlinskiFrancis E, McCarthyPatrick M, MontJ Lluis, MoradyFred, NademaneeKoonlawee, NakagawaHiroshi, NataleAndrea, NattelStanley, PackerDouglas L, PapponeCarlo, PrystowskyEric, RavieleAntonio, ReddyVivek, RuskinJeremy N, SheminRichard J, TsaoHsuan-Ming, WilberDavid. 2012 HRS/EHRA/ECAS expert consensus statement on catheter and surgical ablation of atrial fibrillation: recommendations for patient selection, procedural techniques, patient management and follow-up, definitions, endpoints, and research trial design. J Interv Card Electrophysiol. 2012;33 (2):171–257
29. JC Pachon M, EIPachon M, ArrudaM, NataleA, LoboT, MateosJCP, VargasRNA, PiegasLS, JateneAD. Background Tachycardia and AF-Nests Ablation. New Aspects of Atrial Fibrillation Physiopathology and Spectral Ablation. Abstract: 15th World Congress in Cardiac Electrophysiology and Cardiac Techniques. Europace (2006) 8 (suppl 1). [DOI: 10.1093/europace/8.suppl_1.i]. 2006;8
30. Tsai Wen-Chin, LinYenn-Jiang, TsaoHsuan-Ming, ChangShih-Lin, LoLi-Wei, HuYu-Feng, ChangChien-Jung, TangWei-Hua, TuanTa-Chun, UdyavarAmeya R, WangHi-Hung, ChenShih-Ann. The optimal automatic algorithm for the mapping of complex fractionated atrial electrograms in patients with atrial fibrillation. J. Cardiovasc. Electrophysiol. 2010;21 (1):21–6
31. Lin YJ, KaoT, TaiCT, ChangSL, LoLW, TuanTC. Spectralanalysis during sinus rhythm predicts an abnormal atrial substrate inpatients with paroxysmal atrial fibrillation. Heart Rhythm 2008; 5:968 – 974. [doi: 10.1016/j.hrthm.2008.03.039. PubMed PMID: 18598950.]. 2008;5:968–974
32. Calkins Hugh, KuckKarl Heinz, CappatoRiccardo, BrugadaJosep, CammA John, ChenShih-Ann, CrijnsHarry J G, DamianoRalph J, DaviesD Wyn, DiMarcoJohn, EdgertonJames, EllenbogenKenneth, EzekowitzMichael D, HainesDavid E, HaissaguerreMichel, HindricksGerhard, IesakaYoshito, JackmanWarren, JalifeJose, JaisPierre, KalmanJonathan, KeaneDavid, KimYoung-Hoon, KirchhofPaulus, KleinGeorge, KottkampHans, KumagaiKoichiro, LindsayBruce D, MansourMoussa, MarchlinskiFrancis E, McCarthyPatrick M, MontJ Lluis, MoradyFred, NademaneeKoonlawee, NakagawaHiroshi, NataleAndrea, NattelStanley, PackerDouglas L, PapponeCarlo, PrystowskyEric, RavieleAntonio, ReddyVivek, RuskinJeremy N, SheminRichard J, TsaoHsuan-Ming, WilberDavid. 2012 HRS/EHRA/ECAS Expert Consensus Statement on Catheter and Surgical Ablation of Atrial Fibrillation: recommendations for patient selection, procedural techniques, patient management and follow-up, definitions, endpoints, and research trial design. Europace. 2012;14 (4):528–606
33. Chang Hung-Yu, LoLi-Wei, LinYenn-Jiang, LeeShih-Huang, ChiouChuen-Wang, ChenShih-Ann. Relationship between intrinsic cardiac autonomic ganglionated plexi and the atrial fibrillation nest. Circ. J. 2014;78 (4):922–8
34. Spach M S, JosephsonM E. Initiating reentry: the role of nonuniform anisotropy in small circuits. J. Cardiovasc. Electrophysiol. 1994;5 (2):182–209
35. Pachon M Jose Carlos, ArrudaMauricio. Spectral mapping identifies critical atrial myocardial sites prone to "electrical resonance": could it be the missing puzzle piece in the physiopathology of AF maintenance?. J. Cardiovasc. Electrophysiol. 2012;23 (11):1163–4
36. JC Pachon M, EIPachon M, TGSantillana P, LoboTJ, PachonCTC, PachonMateos JC, AlbornozVRN, JCZerpa A. Simplified Method for Vagal Effect Evaluation in Cardiac Ablation andElectrophysiological Procedures. JACC: Clinical Electrophysiology, Volume 1, Issue 5, October 2015, Pages 451-460, [ISSN 2405-500X, http://dx.doi.org/10.1016/j.jacep.2015.06.008.]. 1997;1:451–460
37. Lellouche Nicolas, BuchEric, CeligojAndrew, SiegermanCarin, CesarioDavid, De DiegoCarlos, MahajanAman, BoyleNoel G, WienerIsaac, GarfinkelAlan, ShivkumarKalyanam. Functional characterization of atrial electrograms in sinus rhythm delineates sites of parasympathetic innervation in patients with paroxysmal atrial fibrillation. J. Am. Coll. Cardiol. 2007;50 (14):1324–31
38. Jalife J, BerenfeldO, SkanesA, MandapatiR. Mechanisms of atrial fibrillation: mother rotors or multiple daughter wavelets, or both?. J. Cardiovasc. Electrophysiol. 1998;9 (8 Suppl):S2–12
39. Jalife José. Rotors and spiral waves in atrial fibrillation. J. Cardiovasc. Electrophysiol. 2003;14 (7):776–80
40. Narayan Sanjiv M, KrummenDavid E, CloptonPaul, ShivkumarKalyanam, MillerJohn M. Direct or coincidental elimination of stable rotors or focal sources may explain successful atrial fibrillation ablation: on-treatment analysis of the CONFIRM trial (Conventional ablation for AF with or without focal impulse and rotor modulation). J. Am. Coll. Cardiol. 2013;62 (2):138–47
41. Haissaguerre Michel, HociniMeleze, ShahAshok J, DervalNicolas, SacherFrederic, JaisPierre, DuboisRemi. Noninvasive panoramic mapping of human atrial fibrillation mechanisms: a feasibility report. J. Cardiovasc. Electrophysiol. 2013;24 (6):711–7