

Innappropriate Sinus Tachycardia After Superior Vena Cava Isolation In Addition To Pulmonary Veins Isolation Of Paroxysmal Atrial Fibrillation Cryoballoon Ablation

Prof. Dr. Murat Sucu, Prof. Dr. Kudret Aytemir, Assoc. Dr. Hikmet Yorgun

Gaziantep University, Cardiology Department, Electrophysiology Division, Gaziantep, Turkey.

Abstract

We report a case of persistent inappropriate sinus tachycardia (IST) after pulmonary vein and superior vena cava (SVC) isolation with cryoballoon ablation for paroxysmal atrial fibrillation (PAF). After the cryoballoon ablation (CBA) procedure, the patient presented with sinus tachycardia of 105 beats/minute. The patient was successfully treated with metoprolol and ivabradine therapy

Introduction

Inappropriate sinus tachycardia after cryoballoon ablation for PAF has never been described. We defined a case of persistent inappropriate sinus tachycardia after pulmonary vein and superior vena cava isolation with cryoballoon ablation for PAF. This tachycardia was successfully treated with ivabradine plus metoprolol combinationResults.

Case Report

A 42-year-old man underwent pulmonary vein isolation with cryoballoon ablation for drug-resistant PAF. Pulmonary vein isolation was performed during atrial fibrillation. After successful pulmonary vein isolation with CBA procedure, a mapping catheter was positioned in the superior vena cava (SVC) to map the origin of the atrial fibrillation. We found superior vena cava triggers. During atrial fibrillation, intracardiac mapping indicated firing foci in the superior vena cava. Cryoballoon ablation successfully removed superior vena cava potentials, resulting conduction block between superior vena cava and right atrium. One month after the CBA procedure, sinus tachycardia was observed in the patient. Before ablation, his mean heart rate was 65 beats/minute and a 24 hour Holter recording revealed a mean heart rate of 89 beats/minute (Maximum 112 beats/min – min 78 beats/min) after CBA (Figure 1). The resting heart rate was >100 b.p.m in the patients however average HR was 89-90 b.p.m on Holter recording. Additional causes of sinus tachycardia like pericardial effusion, fever and anemia were all excluded after the procedure. In our patient, increased heart rate

was not evident shortly after the procedure but one month after the ablation procedure. In addition, transthoracic echocardiography or chest X-ray findings demonstrated no findings regarding pulmonary thromboembolism like increase in right ventricular dimensions, increase in tricuspid insufficiency or pulmonary artery pressure in our patient. Besides those, the decrease in mean heart rate just after ivabradine therapy also confirms the diagnosis mainly based in the increased automaticity in sinus node. The ECG of the patient was not compatible with AT but a focal atrial tachycardia cannot be excluded just based on 12 lead ECG as in the case of focal atrial tachycardia originating from the superior part of crista terminalis. However, the initiation of the tachycardia was not abrupt and termination was not occurred suddenly in our patient indicating the rhythm originating from sinus node even the warming up and the cooling down of the atrial tachycardias are considered. Beyond those, the response of tachycardia after cryoablation to ivabradine is also compatible with sinus tachycardia apart from other rhythm disturbances. Because of the persistent complaint of palpitations, metoprolol succinate was introduced as 50 mg twice daily. This therapy was continued for 2 weeks and because of the patient's continuing complaints ivabradine was added to the therapy. During the metoprolol treatment a small decrease in heart rate was observed as 10 beats/min, but this was not enough for the patient and after that ivabradine treatment was added which caused a significant gradual decrease in heart rate as well as improvement in the patient's symptoms with a mean heart rate of 65 b.p.m.

The procedural details of the pulmonary veins isolation with cryoballoon ablation have been described previously.¹ A 28 mm diameter balloon was used in the patient. During right pulmonary vein cryoballoon ablation application, the right phrenic nerve was continuously paced from the superior vena cava. If the strength of diaphragmatic contraction decreased, cryoballoon application was immediately stopped. In addition, we applied the same procedure

Disclosures:
None.

Corresponding Author:
Dr. Murat Sucu,
Gaziantep University, Cardiology Department,
Electrophysiology Division,
Gaziantep, Turkey.

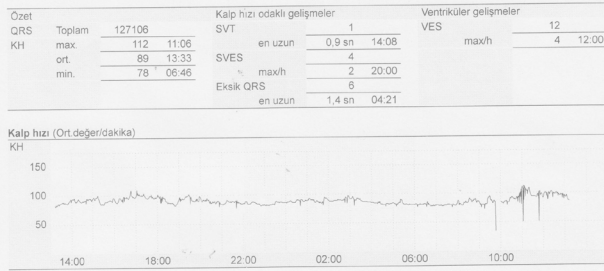


Figure 1: Superior vena cava potentials recorded during the procedure

during superior vena cava isolation. A circular mapping catheter was placed in superior vena cava, where large and high frequency signals were recorded (Figure 2). Isolation of electrical activity in superior vena cava was achieved with only one cryoballoon ablation procedure (Figure 3). After successful pulmonary vein and superior vena cava isolation, atrial fibrillation was terminated spontaneously. The termination of AF was after SVC ablation during the procedure and it was immediate after the end of the procedure. The rhythm

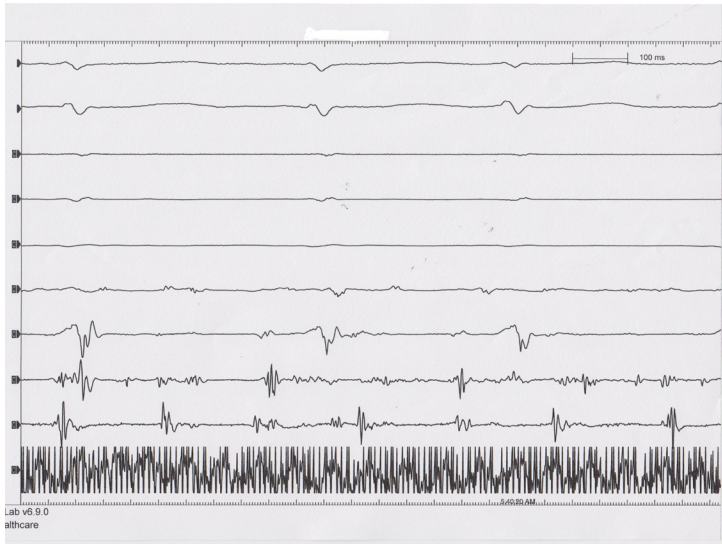


Figure 2: Cryoballoon application for superior vena cava

after the ablation was sinus rhythm and we did not observe any atrial fibrillation during the post procedural follow-up (Figure 4).

Discussion

Cryoballoon ablation of PAF can be safely performed without complications. Our case report has two clinically interesting points. First of all, to the best of our knowledge, this is the first case in the case in the literature describing the the occurrence of IST after cryoballoon ablation of PAF. Second important point is the firing SVC foci necessitating isolation during the cryoballoon ablation procedure for PAF. The patient was 42-year old male without any other risk factors according to the CHADSVASC scoring therefore anticoagulation as warfarin was just given for the 3 months after the cryoablation in this patient and warfarin was cessated after 3 months. Anticoagulation regimen was just given for the 3 months as warfarin after the procedure in this patient due to the zero CHADS2-VASC score. Inappropriate sinus tachycardia after pulmonary vein and superior vena cava ith cryoballoon ablation for PAF has not been

reported before. Atrial fibrillation is also initiated by ectopic foci other than pulmonary veins.^{2,3} The SVC is thought to be the most

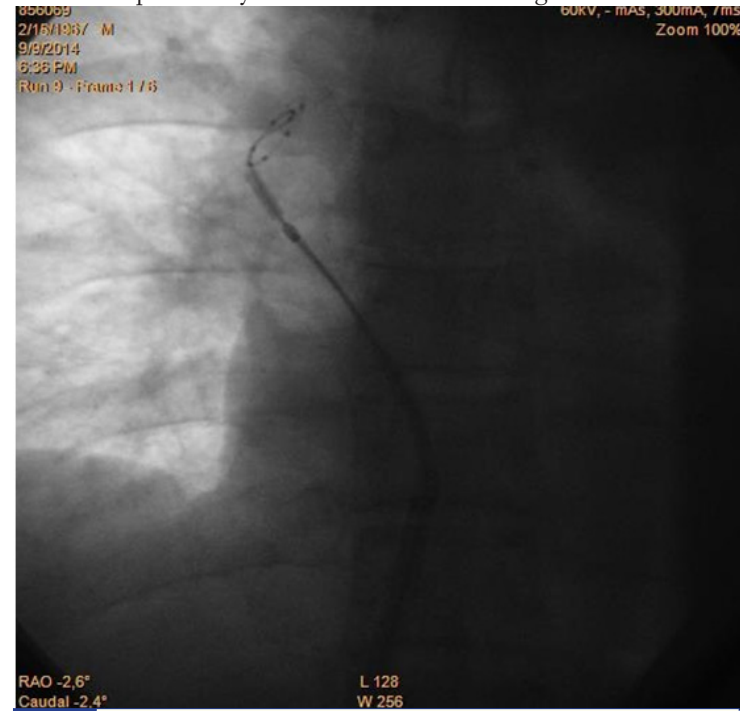


Figure 3: Holter monitoring After Cryoballoon Ablation

common source of ectopic foci and has been reported to play a role in arrhythmia initiation and maintenance in 6%-12% of patients with PAF.⁴ Corrado et al. reported in their randomized study that the patients who underwent SVC isolation as an adjunctive therapy to pulmonary vein isolation had significantly lower recurrence rate of atrial fibrillation than those who underwent only pulmonary vein isolation.⁵ Inappropriate sinus tachycardia is likely due to cryoballoon ablation induced damage to autonomic ganglionic structures around the heart. Damage to the vagus innervation of sinus node could also be involved in the mechanisms of inappropriate sinus tachycardia

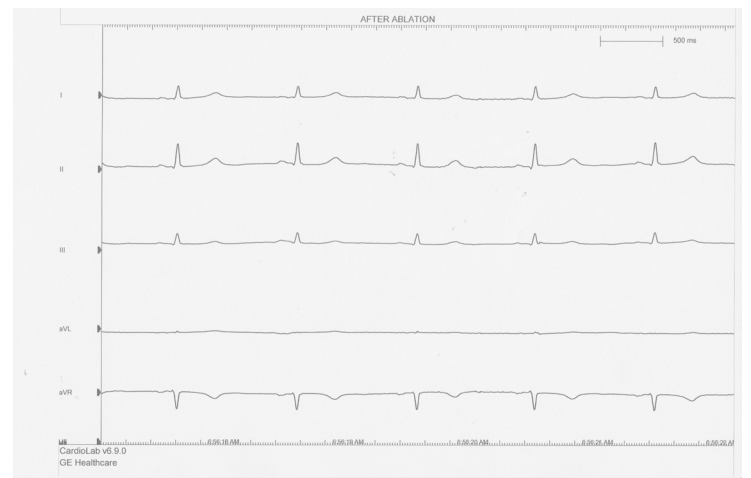

Figure 4: After Cryoballoon Ablation ECG

after AF ablation.⁶ Hyperactivity of the sympathetic nervous system that innervates the sinoatrial node has also been proposed to explain IST.⁷ Inappropriate sinus tachycardia has also been reported as a complication of radiofrequency ablation of some supraventricular tachycardias.⁸ Recently, De Sisti et al. reported the case of successful

use of ivabradine in a patient with inappropriate sinus tachycardia after cryoballoon ablation for atrioventricular nodal re-entrant tachycardia.⁹ Similarly, in a previous study, we investigated the effect of cryoablation on external modifiers of AF-like ganglionated plexi which indicated that vagal reactions during cryoablation, as a surrogate marker of cardiac ANS modification, decreased AF recurrence in a subgroup of patients with paroxysmal and persistent AF.¹⁰ In the light of those data, we think that local denervation during the cryoballoon ablation procedure causing modification of ganglionated plexi might cause the change in mean heart rate which was presented as IST in our patient. Beta blocking agents and calcium channel antagonists are commonly used in the treatment of IST. Ivabradine and metoprolol combination successfully controlled post-cryoballoon ablation IST in our patient.

Conclusion

This is the first case of inappropriate sinus tachycardia after pulmonary vein and SVC isolation with cryoballoon ablation for PAF.

References

1. Andrade JG, Dubuc M, Guerra PG, Macle L, Rivard L, Roy D, et al. Cryoballoon ablation for atrial fibrillation. *Indian Pacing Electrophysiol J.* 2012 ;12:39-53.
2. Lin WS, Tai CT, Hsieh MH, et al. Catheter ablation of paroxysmal atrial fibrillation initiated by nonpulmonary vein ectopy. *Circulation* 2003; 107:3176-3183.
3. Tsai CF, Tai CT, Hsieh MH, et al. Initiation of atrial fibrillation by ectopic beats originating from the superior vena cava: electrophysiological characteristics and results of radiofrequency ablation. *Circulation* 2000; 102:67-74.
4. Arruda M, Mlcochova H, Prasad SK, Kilicaslan F, Saliba W, Patel D, et al. Electrical isolation of the superior vena cava: an adjunctive strategy to pulmonary vein antrum isolation improving the outcome of AF ablation. *J Cardiovasc Electrophysiol.* 2007; 18: 1261-1266.
5. Corrado A, Bonso A, Madalosso M, et al. Impact of systematic isolation of superior vena cava in addition to pulmonary vein antrum isolation on the outcome of paroxysmal, persistent, and permanent atrial fibrillation ablation: results from a randomized study. *J Cardiovasc Electrophysiol* 2010; 21:1-5.
6. Guiot A, Savouré A, Godin B, Anselme F. Collateral nervous damages after cryoballoon pulmonary vein isolation. *J Cardiovasc Electrophysiol.* 2012 ;23:346-51
7. Scherlag BJ, Yamanashi WS, Amin R, Lazzara R, Jackman WM: Experimental model of inappropriate sinus tachycardia: Initiation and ablation. *J Interv Card Electrophysiol* 2005;13:21-29.
8. Moreira JM, Curimbaba J, Filho HC, Pimenta J: Persistent inappropriate sinus tachycardia after radiofrequency ablation of left lateral accessory pathway. *J Cardiovasc Electrophysiol* 2006;17:678-681.
9. De Sisti A, Tonet J, Benkaci A, Frank R. A case of inappropriate sinus tachycardia after atrio-ventricular nodal reentrant tachycardia cryoablation successfully treated by ivabradine. *Europace.* 2010 ;12:1029-31.
10. Yorgun H, Aytemir K, Canpolat U, Şahiner L, Kaya EB, Oto A. Additional benefit of cryoballoon-based atrial fibrillation ablation beyond pulmonary vein isolation: modification of ganglionated plexi. *Europace.* 2014 ;16:645-51.