JAFIB
Case Report
Journal of Atrial Fibrillation

www. jafib.com

3D Intracardiac Echocardiography/Cartosound™ Imaging Of Esophagus Guided Left Atrial Posterior Wall Ablation For Atrial Fibrillation

Jian-Fang Ren, MD, David J. Callans, MD, Francis E. Marchlinski, MD, Jeffrey A. Stiffler, BA, Mouhannad M. Sadek, MD, Gregory E. Supple, MD

Cardiac Electrophysiology Laboratory Division of Cardiovascular Medicine University of Pennsylvania Health System Philadelphia, PA.

Abstract

Two imaging cases highlight the important role of 3D ICE/Cartosound™ in the intracardiac echocardiographic imaging of esophagus and Cartosound™ guidance of radiofrequency lesions delivered safely at the left atrial posterior wall adjacent to esophagus during atrial fibrillation ablation.

Introduction

Esophageal injury during left atrial (LA) ablation at the LA posterior wall (LAPW) adjacent to the esophagus for atrial fibrillation (AF) can result in life threatening complications including perforation and atrioesophageal fistula.[1-8] Strategies for avoiding esophageal injury have been developed including esophageal temperature monitoring and on-line 2-dimensional (2D) intracardiac echocardiographic (ICE) imaging as well as adjusting the power, temperature and duration of lesion application.[8] However, these strategies need to be further improved. We introduce 3 dimensional (3D) ICE imaging of esophagus as complementary tool to real-time 2D ICE in guiding LAPW ablation for AF.

3D ICE Imaging Of Esophagus And Cartosound™ Guiding LAPW Lesions

All AF ablation procedures were guided/monitored by 2D ICE imaging. During the ablation procedure, 3D ICE imaging of esophagus and LA with pulmonary veins (PVs) was performed using a Sequoia ultrasound system (Siemens Medical Solutions) equipped with SoundStar® 3D diagnostic ultrasound catheter (10F, 90cm, Biosense Webster, Inc., Diamond, Bar, CA) and Cartosound™ mapping system. The SoundStar® catheter was inserted into the femoral vein through an 11-Fr introducer sheath and advanced into the right atrium (RA). As described previously,[9] ICE imaging was used to guide transseptal catheterization, assist positioning of the mapping and ablation catheters at the PV ostia, measure ostial flow before and after radiofrequency (RF) lesions and monitor for possible complications. Esophageal imaging features (lumen, anterior and posterior wall) were described in detail as reported previously.[7-8] To image and monitor the esophagus and the LAPW contiguous to esophagus, the ICE transducer was placed in the mid/high RA and rotated clockwise to scan between the left and right mid/lower PV ostia during the ablation procedure. Based on acquisition of esophageal images, scanning its border from left to right side and tracing the esophageal outline on the 2D images (Fig.1A), 3D Cartosound imaging of esophagus and its laterally spatial relationship with LAPW could be obtained and reconstructed (Fig.1B). Importantly, these details are not directly seen with 2D ICE, which usually displays the esophagus and its antero-posterior border (Fig. 1A). During LA mapping and RF ablation, SmartTouch™ (Biosense Webster, Inc. Diamond Bar, CA) was used to provide optimal catheter tissue contact conditions (contact force ranged from 6 to 34 g).[10] During RF lesions delivered at the LAPW for the left PV isolation (PVI) 3D Cartosound with esophageal imaging in the left posterior oblique projection could provide additional anatomical detail and accurate spatial location of LAPW related to the left lateral border of the esophagus, not directly seen with 2D ICE (Fig.1C and D). Similarly, RF lesions were delivered at the LAPW for the right PVI using 3D Cartosound guidance (Fig.1E and F). Based on the 3D Cartosound spatial imaging and real-time 2D ICE lesion morphological monitoring, RF power and duration can be accurately adjusted and controlled to avoid esophageal injury.

The ultrasound imaging of the esophagus depends on whether the esophagus is collapsed or distended. A variety of esophageal imaging features including whether filled with gas, fluid, or both, movement within its segment, or variably collapsed lumen may identify the

Disclosures:
Dr. Marchlinski and Dr. Callans have research grant and participated in clinical research protocol sponsored by Biosense Webster, but their work is unrelated to the content of this article. The other authors have no relationships relevant to the contents of this paper to disclose.

Corresponding Author:
Jian-Fang Ren, MD
Cardiac Electrophysiology Section
Division of Cardiovascular Medicine
University of Pennsylvania Health System
111 N 9th Street, Philadelphia, PA 19107.

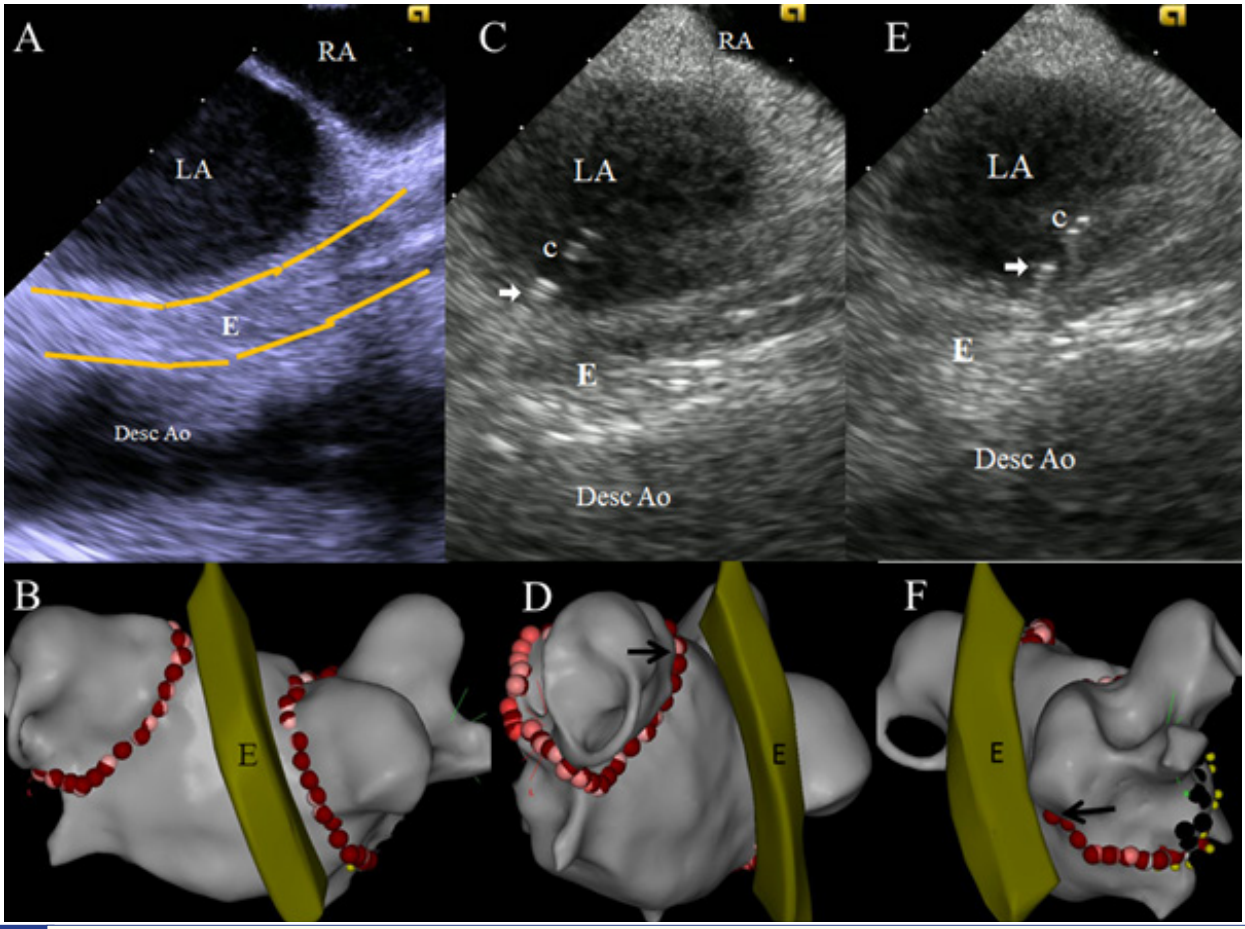

Figure 1: **2D- and 3D-ICE/Cartosound imaging of esophagus (E) and guiding radiofrequency (RF) lesions at the left atrium (LA) posterior wall (PW) contiguous to the E in a 59 year old man with successful pulmonary vein (PV) isolation (PVI) for paroxysmal atrial fibrillation. This patient had mildly enlarged LA (diameter=4.2 cm), normal left ventricle in size and function (ejection fraction = 60%), normal right ventricular size and pulmonary artery systolic pressure estimated at 37 mmHg. 2D ICE image at the baseline of LA immediately contiguous to the E (the outline traced with yellow lines) (Fig.1A), and 3D ICE/Cartosound image of the E and LAPW with complete PVI lesions around the PVs (pink to red tags, representative of different contact force ranged from 6 to 34 g/300 to 600 gsec detected by SmartTouch™) in a postero-anterior projection (Fig.1B); 2D ICE image of LA with significantly swollen wall except the wall contiguous to the E post RF lesions (Fig.1C), and 3D ICE/Cartosound image of the E and LAPW with left PVI lesions, defined the spatial relationship between the most medial lesion (arrow, corresponding to that lesion indicated with an arrow in Fig.1C) for left PVI and the left border of the E in a left posterior oblique projection (Fig.1D); similarly, 2D ICE image of LA contiguous to the E post PVI lesions (Fig.1E), and 3D ICE/Cartosound image of E and LAPW with right PVI lesions, defined the spatial relationship between the most medial lesion (arrow, corresponding to that lesion indicated with an arrow in Fig.1E) for right PVI and the right border of the E in a right posterior oblique projection (Fig.1F). The esophageal diameter measured 10 mm in 2D ICE images and its segmental contract movement with a little change in lumen diameter noted in Fig.1E. c=ablation catheter; Desc Ao=descending aorta; RA=right atrium.**

esophagus with real-time 2D ICE monitoring during LA ablation procedure.[7] It is important to frequently check the esophageal lumen diameter and spatial relationship with the LAPW by real-time 2D ICE to confirm the accuracy of the esophageal image reconstruction with 3D Cartosound before lesions are delivered at the LAPW-esophageal region. As reported previously,[8] esophageal diameter ranged from 6 to 25 mm measured in patients undergoing AF ablation. Significantly changes in diameter were occasionally observed during the ablation procedure (Fig.2). Real-time 2D ICE monitoring and 3D Cartosound with esophageal imaging reconstruction could provide on-line guidance for RF lesions delivered safely at the LAPW-esophageal region.

Discussion

3D ICE/Cartosound imaging is a newly developed catheter-based diagnostic ultrasound imaging modality. It is complementary to the 2D ICE and has the advantage of providing additional anatomical detail and improved spatial relationships. This detail is critical to be defined between LAPW and the esophagus. 3D Cartosound imaging of LAPW-esophageal region defines the lateral (left and right) border of the esophagus and identifies the spatial relationship between the LAPW and esophagus near the PV ostia. This definition is not simultaneous and directly seen with the 2D ICE which provides images of mainly the anterior (immediately contiguous to the LAPW) and posterior (adjacent to the descending aorta) wall of the esophagus. Therefore, 3D ICE/Cartosound imaging can add important spatial/anatomical relationships between the LAPW with PV ostia and esophagus, which enhance the capability of modifying ablation lesions in proximity to the esophagus by adjusting the power, temperature, and duration of lesion application.

3D ICE/Cartosound imaging can monitor/guide the RF lesions delivered at the LAPW-esophageal region and complement the esophageal temperature probe. Whether it can be used instead

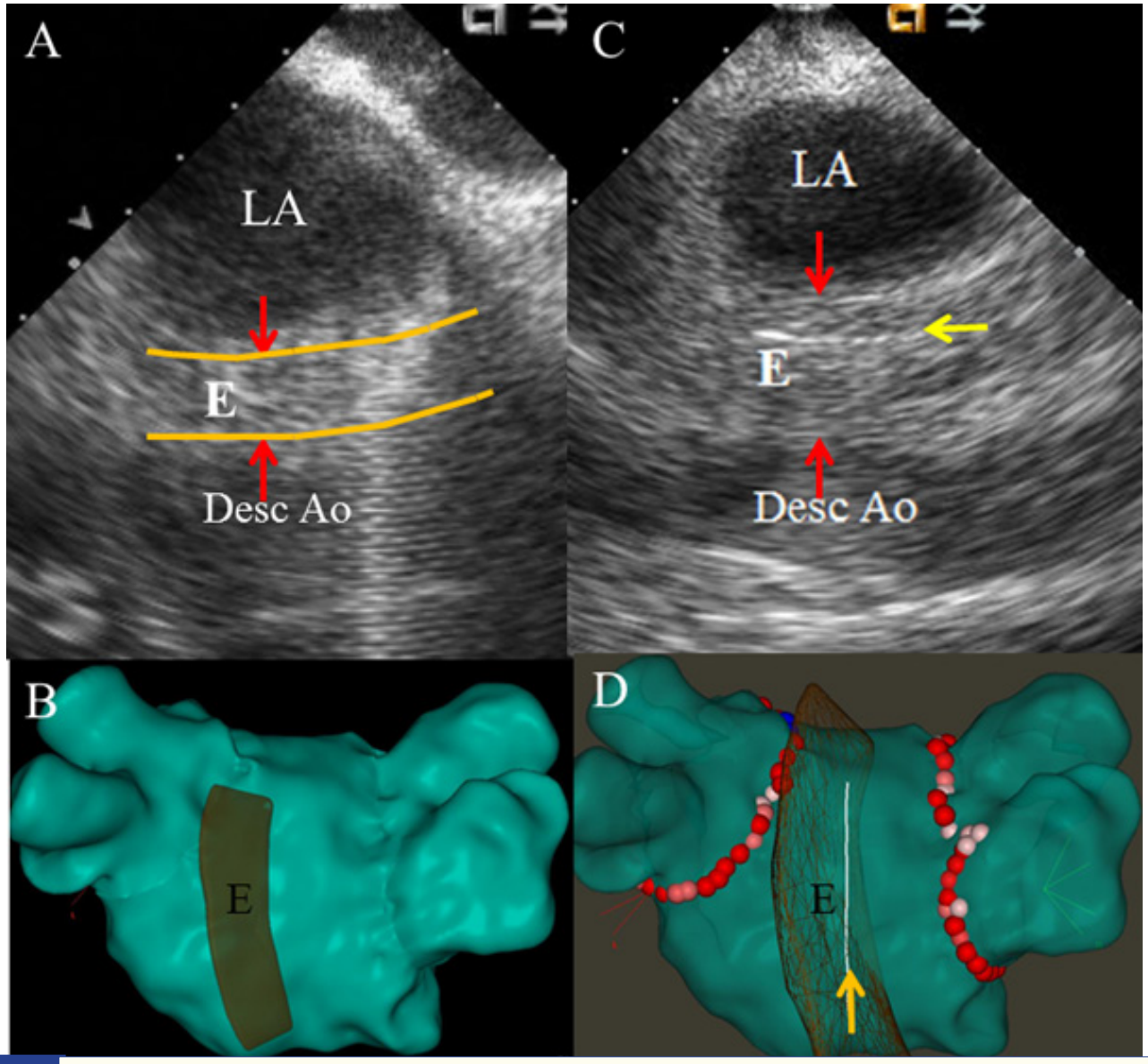

Figure 2: **2D- and 3D-ICE/Cartosound imaging of esophagus (E) and guiding radiofrequency (RF) lesions at the left atrium (LA) posterior wall (PW) contiguous to the E in a 53 year old man with successful pulmonary vein isolation for paroxysmal atrial fibrillation. This patient had enlarged LA (diameter=5.1cm), normal left ventricle in size and function (ejection fraction=55%), normal right ventricular size and pulmonary artery systolic pressure estimated at 28 mmHg. 2D ICE image at the baseline of LA immediately contiguous to the E (the outline traced with yellow lines, diameter = 10mm, between the two red arrows)(Fig.2A), and 3D ICE/Cartosound image of the LA with pulmonary veins and an E segment immediately contiguous to LAPW in a postero-anterior projection (Fig.2B); 2D ICE image of LA with significantly swollen wall except the wall contiguous to the E post RF lesions, significant change in the E diameter (21 mm, between the two red arrows) during the ablation procedure (Fig.2C), and 3D ICE/Cartosound image of the E with enlarged diameter and LAPW with complete PVI lesions, defined the spatial relationship between the E and LAPW lesions around the pulmonary veins (pink to red tags, representative of different contact force ranged from 6 to 34 g/300 to 600 gsec detected by SmartTouch™) in a postero-anterior projection (Fig.2D). Based on the 3D Cartosound spatial imaging and real-time 2D ICE lesion morphological monitoring, reduction of RF power and shortened duration were taken with the ablation delivered at the most medial lesions for left PVI to avoid E injury. The positioning of E temperature probe (yellow arrow) was imaged in the E antero-posterior view with 2D ICE imaging, whereas a significant eccentric positioning of the e temperature probe was identified in the E postero-anterior projection view (yellow arrow) with real-time 3D CartoUnivu™. Desc Ao=descending aorta.**

this probe remains to be determined. Real-time 3D-CartoUnivu™ (Biosense Webster, Inc. Diamond Bar, CA) is a novel technology that combines the information from a choice of fluoroscopy systems with the mapping capabilities of the Carto system. During the procedure, all catheter locations are shown in real-time over the Carto map and registered fluoro image. This allowed for accurate and proper position of the ablation catheter tip on real-time 3D "overlapped" imaging. It has the capability to overlap esophageal temperature catheter (probe) imaging on the 3D Cartosound electroanatomic map (Fig.2D). Of note, although the positioning of esophageal temperature probe tip can be adjusted to meet the level of the ablation catheter electrode based on the fluoroscopic imaging, lateral displacement can exaggerate the distance between the lesion site and the probe location in the esophageal lumen (Fig.2C and D) and may limit its accuracy and sensitivity in monitoring the temperature change during the RF delivered at the LAPW-esophageal region.

Current limitations of the technology

At present, the technology of 3D ICE is not true real-time

imaging. 3D ICE was performed with a mono-plane transducer using a multiple scan approach for sequential data acquisition, gated to ECG and respiration. Although 3D ICE reconstructed esophageal imaging can be obtained within minutes, this methodology is limited by the need for multiple image sampling producing long data acquisition times and some image artifacts. In addition, as compared to the real-time 2D ICE, 3D ICE has a relative low spatiotemporal resolution and slow imaging acquisition rate. To overcome these limitations, real-time 3D ICE with further miniaturization of matrix-array transducer and the use of an advanced integrated circuit will be required, which allows a significant portion of beam forming to be housed and processed inside the transducer.

Conclusion

Esophageal injury during LA ablation at the LAPW-esophageal region can result in atrio-esophageal fistula. Because of the high mortality of this complication, avoiding and preventing esophageal injury is paramount during LA ablation procedures. 3D ICE/Cartosound can provide additional anatomical detail and define spatial relationship between LAPW and the esophagus near the pulmonary vein ostia. It provides an important complementary role to real-time 2D ICE and esophageal temperature monitoring for guiding RF lesions safely delivered at the LAPW-esophageal region.

References

1. Gillinov AM, Pettersson G, Rice TW. Esophageal injury during radiofrequency ablation for atrial fibrillation. J Thorac cardiovasc Surg 2001;122:1239-1240.
2. Sonmez B, Demirsoy E, Yagan N, et al. A fatal complication due to radiofrequency ablation for atrial fibrillation: atrio-esophageal fistula. Ann Thorac Surg 2003;76:281-283.
3. Doll N, Borger M, Fabricius A, et al. Esophageal perforation during left atrial radiofrequency ablation: is the risk too high? J Thorac Cardiovasc Surg 2003;125:836-842.
4. Scanavacca MI, D'avila A, Parga J, Sosa E. Left atria-esophageal fistula following radiofrequency catheter ablation of atrial fibrillation. J Cardiovasc Electropgysiol 2004;15:960-962.
5. Pappone C, Oral H, Santinelli V, et al. Atrio-esophageal fistula as a complication of percutaneous transcatheter ablation of atrial fibrillation. Circulation 2004;109:2724-2726.
6. Bunch TJ, Nelson J, Foley T, et al. Temporary esophageal stenting allows healing of esophageal perforation following atrial fibrillation ablation procedures. J Cardiovasc Electrophysiol 2006;17:435-439.
7. Ren JF, Marchlinski FE, Callans DJ, Schwartzman D. Practical intracardiac echocardiography in electrophysiology, Oxford, UK: Blackwell-futura, 2006:191-203.
8. Ren JF, Lin D, Marchlinski FE, Callans DJ, Patel V. Esophageal imaging and strategies for avoiding injury during left atrial ablation for atrial fibrillation. Heart Rhythm 2006;3:1156-1161.
9. Ren JF, Marchlinski FE, Callans DJ, Zado ES. Intracadiac Doppler echocardiographic quantification of pulmonary vein flow velocity: an effective technique for monitoring pulmonary vein ostia narrowing during focal atrial fibrillation ablation. J Cardiovasc Electrophysiol 2002;13:1076-1081.
10. Natale A, Reddy VY, Monir G, et al. Paroxysmal AF catheter ablation with a contact force sensing catheter: results of the prospective, multicenter SMART-AF trial. J Am Coll cardiol 2014;64:647-656.