JAFIB
Featured Review
Journal of Atrial Fibrillation

# Which Is The Appropriate Arrhythmia Burden To Offer RF Ablation For RVOT Tachycardias?

Andreas Rillig, Tina Lin, Feifan Ouyang, Karl-Heinz Kuck, Roland Richard Tilz

*Department of Cardiology, Asklepios Klinik St. Georg, Hamburg, Germany.*

**Abstract**

**Premature ventricular complexes (PVCs) and ventricular tachycardia (VT) in patients with structurally normal hearts originate from the right ventricular outflow tract (RVOT) in the majority of cases. In the last few decades catheter ablation of these arrhythmias has been proven to be effective. RVOT VT/PVCs may cause disabling symptoms or arrhythmia induced cardiomyopathy. However, the PVC burden at which catheter ablation should be recommended is still controversial. What adds to the controversy is why some patients with only a low number of PVCs can be highly symptomatic and may even develop arrhythmia induced cardiomyopathy, whilst others may have a higher PVC/VT burden and remain asymptomatic and do not develop cardiomyopathy for a long period of time. Therefore, although catheter ablation of RVOT PVCs has high success and low complication rates, the time point of when ablation should be recommended is currently still under debate. This review discusses the treatment strategies and prognosis for RVOT tachycardias and focuses on the question of which arrhythmia burden is appropriate to offer RF ablation.**

## Introduction

The incidence of PVCs or non-sustained VTs (NSVTs) in subjects with apparently healthy hearts varies according to observational studies and is predominantly dependent on the sampling technique.[1] PVCs were seen in 7.8% of the participants during evaluation of 12-lead ECGs in a large healthy military population, with a much lower incidence seen in younger patients below the age of 20 (4.6%) compared to those older than 50 years of age (21.7%).[2] In another study published by Hinkle et al., the incidence of asymptomatic ventricular arrhythmias was 62% in a mixed population of healthy individuals and patients with known heart disease.[3]

Monomorphic PVCs are usually associated with a favourable prognosis, whereas polymorphic PVCs or NSVTs may indicate an increased risk of cardiovascular morbidity and mortality.[4,5] In addition, the occurrence of PVCs or NSVTs during the exercise or recovery phases may be a predictor for poorer prognosis even when no structural heart disease is present.[6,7] Furthermore, the prognostic implication of PVCs may vary depending on the patient's age, baseline heart disease, left ventricular (LV) function and co-morbidities. In general however, patients with structurally normal hearts and aged less than 30 are not at increased cardiovascular risk, whereas PVCs may be associated with an increased risk in patients older than 30 years.[8]

Generally, PVCs originate predominantly from the right or left outflow tract in young patients. In these patients with structurally normal hearts and right ventricular outflow tract (RVOT) PVC/VTs, MRI studies have shown variable results ranging from completely normal hearts[9] to subtle structural wall abnormalities of the RVOT.[10-14]

This review discusses the diagnosis of RVOT VT/PVCs and the treatment strategy for symptomatic and asymptomatic patients, with a special focus on catheter ablation.

## How To Diagnose RVOT PVCs From Other Sites Of Origin

The 12-lead surface ECG is crucial for identifying the origin of PVCs/VTs from this anatomically complex region.[15, 16] Resting 12-lead ECGs in sinus rhythm are usually normal, with up to 10% of patients presenting with incomplete or even complete right bundle branch block (RBBB).[17] Typically, PVCs originating from the RVOT have an inferior axis with left bundle branch block (LBBB) morphology, and a late R/S transition at V4 in the precordial leads. A QRS duration <140ms is suggestive of a PVC with a 'septal' origin, whereas a QRS duration >140ms favours a 'free wall' origin, particularly when notches are seen in the downstroke of the QRS of the inferior leads.[18,19] (Figure 1).

Due to the close anatomical relationship between the RVOT and left ventricular outflow tract (LVOT), the differences in the ECG characteristics can be subtle (Figure 2). Large R-wave amplitude and duration in V1-V2, and early transition in the precordial leads suggest a PVC/VT origin from the LVOT.[20, 21, 22, 23, 24] In addition, Hoffmayer, et al. demonstrated that ventricular arrhythmias due to arrhythmogenic right ventricular cardiomyopathy (ARVC) have a significantly longer mean QRS duration in lead I, more often exhibit a precordial R/S transition at lead V6, and more often have notching in at least one ECG lead. In fact, a R/S transition at lead V6 was the most specific criterion for ARVC (100% specificity), and a QRS duration ≥120ms in lead I was the most sensitive (88% sensitivity).[25]

**Disclosures:**
None.

**Corresponding Author:**
Andreas Rillig, MD
Lohmühlenstr. 5
20099 Hamburg.

Image A (left side): PVC originating from the RVOT (red arrow)
Image B (right side): Perfect pace map (red arrows) at the ablation side in the RVOT with successful suppression of PVCs

**Figure 1: Typical ECG morphology of PVCs originating from the right ventricular outflow tract (RVOT).**

## Clinical Presentation Of RVOT PVC/VTs

The clinical presentation of patients with RVOT PVC/VTs varies and usually occurs as follows:

1) Most patients report various symptoms such as dyspnea, reduced exercise capacity, palpitations, a racing heart rate, dizziness, pre-syncope and syncope.

2) Other associated symptoms include coughing, dysphagia and claudication.[26-30] The development of tachycardia-induced cardiomyopathy with LV dilatation can worsen the clinical symptoms of heart failure and reduced exercise capacity.[31]

3) Quality of life (QOL) is often reduced in patients with RVOT PVC/VTs. Radiofrequency (RF) ablation of PVCs and VTs in patients with structurally normal hearts has been shown to result in a significantly improved QOL in 6 out of 8 SF-36 domains.[32, 33]

4) Recurrent syncope may occur in patients with RVOT PVC/VT. In these patients and particularly those with short PVC coupling intervals or fast VT cycle lengths (CL), a so-called "malignant variant" of RVOT tachycardia has to be considered, which has a worse prognosis.[34, 35]

## Cardiomyopathy Associated With RVOT PVC/NSVTs

### General Aspects Of PVC/NSVT-Induced Cardiomyopathy

Cardiomyopathy induced by atrial tachyarrhythmias has been well described.[34-37] The suggested underlying pathophysiology is consistent with animal models of tachycardia-induced cardiomyopathy.[40] Furthermore, cardiomyopathy secondary to VT in patients with structurally normal hearts was initially described in the early 1990s,[41-43] and the first reported case of a successfully reversed PVC-induced cardiomyopathy after catheter ablation was published in 2000 by Chugh et al.[44] Although the mechanism for tachycardia-induced cardiomyopathy secondary to atrial tachyarrhythmias with fast ventricular activation is well understood, the mechanisms for PVC-induced cardiomyopathy are less clear. Besides LV dyssynchrony due to LBBB during PVCs,[45] other causes such as increased oxygen consumption[46] have been implicated. Furthermore, the so-called apical-to-basal "squeezing effect" in systole during physiological activation of the LV is disrupted during RVOT PVCs with LBBB morphology, which may further impair LV systolic output.[47]

### What Is The Arrhythmia Burden That Leads To Cardiomyopathy?

The initial case reports of patients with PVC-induced cardiomyopathy described recovered LV systolic function after successful cathter ablation in patients with a high monomorphic PVC burden arising from the RVOT (generally >20000 PVCs/24h).[44, 48-50] However, to date the important question of how many PVCs are required to cause PVC-induced cardiomyopathy is not yet completely answered. Whereas in one study from Carbeillera Pol et al., the PVC burden was not associated with the developement of cardiomyopathy (PVC burden >10% was used as inclusion criteria in this study),[51] several other studies showed correlation between PVC frequency and cardiomyopathy.

In most series, a higher PVC burden was associated with a higher incidence of impaired LV systolic function. Del Carpio Munoz et al. demonstrated that patients with impaired LV function had an increased PVC burden (29.3±14.6% vs 16.7±13.7%, P=0.004).[52] Baman et al.[53] evaluated the impact of PVC burden on reduced LV systolic function in 57 patients with PVCs predominantly originating from the RVOT. The initial mean LV systolic function in this patient population was 35%, which improved by at least 15% or normalized after succesful RF ablation, defined as suppression of the PVC burden >80%. The PVC burden was significantly higher in patients with suppressed LV systolic function compared to those without LV dysfunction (33% vs 13%). A PVC burden cut-off of >24% best separated patients likely to develop impaired LV function from those less likely to develop LV dysfunction (sensitivity 79%, specificity 78%, area under curve 0.89).[53] The authors also stated that a PVC burden cut-off of 16% would result in a higher sensitivity of 90% for PVC-induced cardiomyopathy, but the specificity would decrease to 58%.[53] Importantly, patients with preserved LV function but a dilated LV were associated with an intermediate PVC burden of 22%, which was significantly lower compared to patients with LV systolic dysfunction but significantly higher compared to patients with normal LV systolic function and dimensions.[53] Another interesting finding was that the development of cardiomyopathy was independent of the site of PVC origin. Thus, patients with an epicardial or left-sided PVC origin also developed impaired LV function. This finding was in line with reports from other investigators who described cardiomyopathy induced by monomorphic PVCs originating from other locations such as the LV[54, 55] or from above the pulmonary valve[56-58] that resolved after successful catheter ablation.

In another study from Baman et al., successful RF ablation could be achieved in 82% of patients with PVC/VTs. In these patients,

**The anatomical location and R progression in V1**

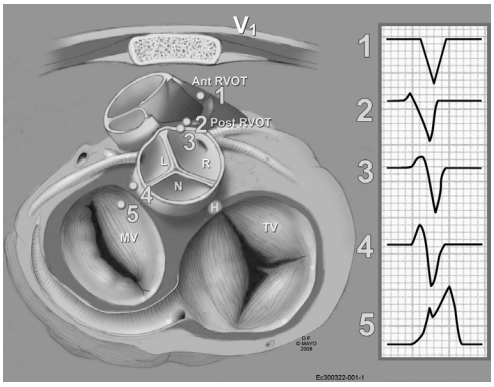


With permission from Tabatabaei et al. Circulation arrhythmia 2009

**Figure 2: Anatomical origin of PVCs and R progression in lead V1.**

**Figure 3:** Holter ECG recordings pre (left panel) and post (right panel) ablation in a patient with frequent PVCs originating from the RVOT.

RF ablation not only improved LV systolic function, it also reduced LV diameters (end-systolic and end-diastolic diameters) after a follow-up period of 6 months.[53] Noteably, cardiomyopathy was also observed in one patient with a PVC burden of only 10%. This is in line with results from several other studies and case reports. In a study published by Yarlagadda et al.,[59] even a PVC burden of only 5500 per day resulted in cardiomyopathy in one patient. Shanmugam et al. reported resolution of significant LV systolic impairment after successful RF ablation in a patient with <5000 PVCs per day (i.e. a PVC burden of 4%/24h).[60] In contrast, Takemoto et al.[31] reported a patient with a PVC burden <10% who did not have improvement of LV dysfunction after successful ablation. This suggests that PVCs in some patients may be associated with the early stages of DCM or other cardiac diseases. Kanei et al. evaluated the prevalence of cardiomyopathy in patients with PVCs as assessed by 24h-holter monitoring categorized as follows: low PVC burden of <1000, intermediate PVC burden of 100-10000 and high PVC burden of >10000. The prevalence of reduced LV function was associated with the number of PVCs (4%, 11% and 32%, respectively) in this retrospective study.[61]

Another entity called interpolated PVCs might be associated with PVC-induced cardiomyopathy.[62] Olgun et al., evaluated 21 patients with PVC-induced cardiomyopathy for the presence of interpolated PVCs. Although overall a higher PVC burden was seen in patients with PVC-induced cardiomyopathy, interpolated PVCs were found to be an independent predictor for cardiomyopathy.[62] The mechanism for this phenomenon is not clear, but it is possible that a higher heart rate in sinus rhythm may lead to a higher likelihood for PVC occurrence. Therefore in these patients, the PVC burden itself may not be a reliable criterion for deciding whether ablation should be performed or not.

**Specific Aspects Of PVC/NSVT-Induced Cardiomyopathy**

In a consecutive series of 294 patients with idiopathic PVCs evaluated by Yokokawa et al., the QRS duration found to be significantly longer in patients who had reversible cardiomyopathy after RF ablation.[63] Importantly, a QRS-duration of >150ms identified patients with reversible cardiomyopathy compared with those without reversible cardiomyopathy with a sensitivity of 80% and specificity of 52%. Although PVCs with an epicardial origin had the longest QRS duration, an epicardial origin itself was independently associated with a reversible cardiomyopathy. Another study published 2011 demonstrated that patients with PVC-induced cardiomyopathy had[64] broader QRS complexes than those without cardiomyopathy. A reasonable explanation for this phenomenon could be that a wider QRS duration leads to a higher degree of dyssynchrony in the heart.[65] Furthermore, symptom duration[66] in patients with PVCs may also be associated with the occurrence of PVC-induced cardiomyopathy. Carbeillera Pol et al.[51] found that patients with PVCs with a broader QRS complex (>150ms) are at higher risk of developing PVC-induced cardiomyopathy after RF ablation. Furthermore, a non-right-sided origin was also associated with irreversible cardiomyopathy. Deyell et al. found that a longer QRS duration was associated with a lower likelihood of recovery from PVC-induced cardiomyopathy. The hypothesis was that a combination of both fibrosis and myofiber disarray may play a role in the prolongation of PVC QRSs.[67]

The incidence of PVC-induced cardiomyopathy is higher in older patients[59] and the pathophysiology is less well understood. It is often more difficult to determine whether PVCs are a result of reduced LV function or the cause. It is well described that PVCs/NSVTs are a common finding on 24-hour holter recordings in patients with ischemic or dilated cardiomyopathy. The indication for primary ICD implantation in these patients to reduce the arrhythmogenic risk for SCD is dependent on LV function and not arrhythmia burden. The increased risk for SCD is present even if no arrhythmias have been documented.

**When Does LV Dysfunction Resolve?**

In patients with PVC-induced cardiomyopathy, an improvement of systolic function can usually be observed post-ablation after a short follow-up period of approximately 3 months.[67] When the LV dysfunction completely resolves is less clear and may vary, as demonstrated by Yokokawa et al., who evaluated the time course of LV function recovery in 87 patients with PVC-induced cardiomyopathy after successful RF ablation, defined as a reduction of >80% of the initial PVC burden (Yokokawa et al HR 2013). The majority (68%) of patients experienced LV function recovery within 4 months post-ablation,[66] whilst in the remaining patients LV recovery was seen after a mean of 12±9 months. Importantly, one patient had LV function normalization only after 45 months. In the patients with delayed improvement of LV function, QRS width was significantly longer. Furthermore, an epicardial origin was an independant predictor for delayed LV recovery from PVC-induced cardiomyopathy.[66] Also, a right-sided PVC origin was associated with faster recovery of LV function. Therefore, it is recommended that final evaluation of LV function recovery after successful PVC ablation should only be performed after a minimum of one year. Although animal studies demonstrated no structural changes such as fibrosis,[68] delayed remodelling or prolongation of Ca2+ channel function has been hypothesized to cause slower LV function recovery in some patients.[66]

## Medical Therapy For The Treatment Of PVC/NSVTs

Data regarding medical therapy for the treatment of idiopathic PVCs or VTs is sparse. Duffe et al. described four patients where PVC-induced cardiomyopathy was successfully treated with beta-blockers or amiodarone.[17, 69, 70] According to the current guidelines for the management of symptomatic PVCs,[71] beta-blockers are the drug of choice. However, the efficacy of beta-blocker therapy (namely

**Table 1:** Overview of relevant studies about RVOT ablation.

| Author Author and year of publication | Patients with reduced LV function, n (%) | PVC burden before ablation | PVC burden after ablation | Success rate n (%) | Systolic ejection fraction at baseline | Systolic ejection fraction after ablation | Patients with normalized systolic LV function, n (%) | LVEDD before ablation (mm) |
|---|---|---|---|---|---|---|---|---|
| Chugh et al. 2000 | 1 | 25.000-56.000 PVCs/24h | 1.100-1.800 PVCs/24h | 1/1 (100) | 43% | 58% | 1 (100) | 65 |
| Redfearn at al. 2003 | 1 | 31.000 PVCs/24h | 1 PVC/24h | 1/1 (100) | Mildly-moderately reduced | 54% | 1 (100) | 59 |
| Shiraishi et al. 2002 | 1 | 50.000 PVCs/24h | 1.100-1.800 PVCs/24h | 1/1 (100) | 34% | normalized | 1 (100) | 65 |
| Efremidis et al. 2008 | 1 | >50.000 PVCs/24h | No PVCs/24h | 1/1 (100) | 40-45% | 55% | 1 (100) | n.a. |
| Deyell et al. 2012 | 48/114 (42) | (Inclusion Criterion PVC burden ≥ 10%/24h) 34.202 ±15.493 PVCs/24h in patients with reversible LV function | n.a. | 37/44 (84%; 4 lost to FU) | 38.2% in Pts with reversible LV function | Median improvement of LV function 17.5% (IQR 10–40) for patients with reversible LV dysfunction | 24/48 (50) | 56±0.7 |
| Ezzat et al. 2007 | 1 | 30000 PVCs/24h (30%/24h) | 2.022 PVCs/24h | 1/1 (100) | 40% | 62% | 1 (100) | 65 |
| Olgun et al. 2011 | 21/51 (41.2) | PVC burden 30±10%/24h | n.a. | 42/51 (82) | 37±10% | 55±9% | 21/21 (100) | n.a. |
| Takemoto et al. 2005 | 14/40 (35) | PVC burden >20%/24h (mean 34±3%) | PVC burden 1.3 ±0.9 | 37/40 (92.5) | 66±2% | 72±2% | 13/14 (93) | 54±1 |
| Yarlagadda et al. 2005 | 8/27 (29.6) | 17541±11479 PVCs/24h | 507±722 | 23/27 (85) | 39±6% | 62±6% | 7/8 (87.5) | n.a. |
| Yokokawa et al. 2013 | 87/264 (33) | PVC burden 26 ±11%/24h | 2% ± 4%/24h | 75/87 (86.2) | 39±10% | 59±4% | 51/ 75 (68) | 56±6 |
| Baman et al. 2010 | 57/174 (32.8) | PVC burden 33 ±14%/24h | 1.9% ±4.4%/24h | 146/174 (84) | 35±9% | 54±10% | 46/57 (81) | 57±6 |

atenolol and metoprolol) is generally modest, with a reduction of PVC burden between 10-25%.[72, 73, 74] The efficacy of calcium channel antagonists such as verapamil varies in several reports, with reasonable efficacy in patients with idiopathic VT[70, 75, 76] but it is less effective in patients with only PVCs, most likely as a result of different underlying mechanisms.[74] Following these, Class I antiarrhythmic drugs such as propafenone or flecainide are recommended. Although treatment of symptomatic patients with PVCs in structurally normal hearts with these antiarrhythmic drugs may be reasonable,[71] they are contraindicated in patients with cardiomyopathy due to their proarrhythmic effects.[77] In these patients, beta-blockers and amiodarone are the only antiarrhythmic drugs available. However, due to the frequent and significant side effects associated with amiodarone,[78] it should only be administered in patients refusing catheter ablation or after failed catheter ablation. Since catheter ablation of RVOT PVC/VTs is a highly effective therapy with a very low complication rate, this should be the treatment of choice.

A recent study by Zhong et al. further highlights the superiority of RF ablation compared with antiarrhythmic drug therapy for the treatment of idiopathic PVCs. In this study, RF ablation reduced the PVC burden by 93%, which was significantly higher compared to treatment with Class I and III antiarrhythmic drugs.[79]

## How To Differentiate Cardiomyopathy Associated With Structural Heart Disease From PVC-Induced Cardiomyopathy?

At times it may not be clear if reduced LV function is due to the early stages of dilated cardiomyopathy or undetected ischemic heart disease, myocarditis or as a result of frequent PVCs in patients without structural heart disease. We propose the following recommendations for the initial evaluation of such patients:

Firstly, patients with idiopathic PVCs are usually young, with a higher incidence seen in women.[71] Echocardiographic findings generally show reduced LV function with global hypokinesia, but without local wall motion abnormalities[54] and with or without enlarged LV diameters but preserved LV wall thickness.[53] Coronary angiography rules out coronary heart disease in these patients.[53, 59] As described above, although a low PVC burden could also cause cardiomyopathy, the PVC burden is usually high (>24% or >20000 PVCs/24hrs), with a predominant monomorphic PVC morphology (literature) most often emanating from the RVOT (53). Polymorphic PVCs are usually a sign of a more complex tachyarrhythmia or extensive myocardial damage, and are more often seen in patients with structural heart disease.[80] Whenever the cause of the cardiomyopathy remains unclear, one should consider antiarrhythmic drug therapy for 3-6 months with the aim for PVC suppression to see if an improvement of LV systolic function occurs. The antiarrhythmic drug of choice is amiodarone as most others are contraindicated,[71] and short-term treatment with this drug is reasonable in selected patients.

## Success Rate And Complications Of RF Ablation

In general, the succes rate of catheter ablation of arrhythmias originating from the RVOT is reported to be high.[81-83] In most studies, the acute success rate is reported to be >80%.[71] After initial successful ablation the recurrence rate is also low, generally not exceeding 5% even after long-term follow-up.[21, 22, 71, 84-86] The acute success rate of catheter ablation is usually lower in patients who have only infrequent PVCs or non-inducibility of the clinical arrhythmia during the procedure. The pathophysiologic basis for idiopathic PVCs, NSVTs and ventricular tachycardias vary, but are considered to be mostly related to triggered activity due to intracellular calcium overload mediated by cyclic-AMP. Therefore, an isoproterenol infusion may be required to induce these arrhythmias during an electrophysiology study.[87-89] Difficulties in inducing the clinical arrhythmia even after isoproterenol administration may decrease the

success rate of catheter ablation in these patients due to the lack of a clear endpoint. When there is non-inducibility of the clinical VT, ablation of monomorphic PVCs with the same morphology as the documented arrhythmia to eliminate the arrhytymia trigger may be a reasonable strategy. In addition to activation mapping, pace-mapping may be performed. Non-contact mapping can be considered in difficult cases to identify the PVC origin even in patients with rare PVCs.[90-92] As deep sedation is considered by some investigators to reduce the spontaneous PVC burden, reducing the amount of sedation and analgesia can often reduce suppression of PVCs and increase their frequency.

In general, catheter ablation of idiopathic PVCs originating from either the RVOT or left-sided structures is usually considered to be safe.[21] Zhong et al. recently published a procedure-related complication rate of 5.6% (12 patients).[79] The use of intracardiac echocardiography may help to better define the anatomy in complex cases during ablation of RVOT arrhythmias and has been previously shown to be helpful, particularly during ablation of tachycardias from the LVOT.[94]

Although RF energy is still the gold standard for ablation within the RVOT[21, 22, 71, 84-86] with high efficacy and safety,[21] cryoablation is a reasonable alternative that allows for almost pain-free ablation.[48, 95]

## What Is The Arrhythmia Burden To Offer RF Ablation?

### RF Ablation To Treat Symptomatic Patients

Catheter ablation in symptomatic patients with PVC/VTs has been described for many decades and is highly effective.[48, 96, 97](Figure 3). These initial results have been confirmed in later studies and have been shown to be superior to medical management.[72-74] Although symptomatic patients usually suffer from a high PVC burden (>10000 PVCs/24h), symptoms are not exclusive to these patients and those with a smaller PVC burden (<5000/24h) may also be highly symptomatic and warrant ablation. The low PVC burden makes activation mapping more difficult and often pace-mapping or non-contact mapping is required[60, 98] for successful mapping and catheter ablation. Nevertheless, effective catheter ablation has also been shown to be able to obtain a significant improvement of QOL.[99] In addition, it has also been proven to be more cost effective.[100] In comparison, medical therapy with atenolol has been shown to be effective in reducing symptoms as well as PVC burden versus placebo, but failed to improve overall QOL.[33]

In conclusion, ablation should be offered to all patients with symptomatic RVOT PVCs refractory to antiarrhythmic drug treatment or when medical therapy is not desired by the patient regardless of the PVC burden.

### RF Ablation In Asymptomatic Patients With Preserved Systolic Ejection Fraction

As described above, RVOT PVCs may result in reduced LV systolic function or even PVC-induced cardiomyopathy. Superior to antiarrhythmic drug therapy, catheter ablation is the treatment option of choice for PVC-induced cardiomyopathy. The cutoff is still not yet defined, however two large studies have demonstrated that a cutoff value of 20% to 24% PVCs per 24 hours is associated with an increased risk of developing reduced LV function and cardiomyopathy. Therefore, in patients with such a high volume of PVCs, prophylactic catheter ablation may be proposed even when patients are asymptomatic. Furthermore as described above, even a PVC burden of less than 5000 PVCs per 24 hours can result in impaired LV systolic function. Therefore, also in this last condition, close monitoring of these patients is recommended to screen for early forms of impairment of LV function. In addition, a complete cardiac work-up should be performed to exclude any underlying early-stage structural cardiomyopathy that may require a different therapeutic strategy.

### RF Ablation In Asymptomatic Patients With Reduced Systolic Ejection Fraction

Whenever reduced LV systolic function is observed in a patient with frequent monomorphic PVCs, catheter ablation should be offered to prevent worsening of LV systolic function or development of heart failure symptoms.

Because LV function impairment has also been described despite a lower PVC burden,[60] catheter ablation should also be offered. Therefore, catheter ablation should be offered to all patients with reduced LV systolic function to prevent further progression of LV dysfunction and to normalize cardiac function. Given that LV function recovery may take up to one year or longer, RF ablation should be recommended without delay in these patients.

### Special Considerations For Particular Conditions

The prognosis in patients with RVOT PVC/VTs is usually favourable. However special attention should be given to patients fulfilling the criteria of potentially malignant variants of RVOT arrhythmias. These include symptoms of recurrent syncope, PVCs with very short coupling intervals, VTs with short cycle lengths, or documented polymorphic RVOT PVCs/VTs or "benign" RVOT PVCs in the presence of channelopathy or structural heart disease. Whenever one of the above-mentioned criteria is present, further treatment should be modified with an early recommendation for catheter ablation independent of the arrhythmia burden or LV function, associated with the evaluation of the need for further treatment based on the underlying cardiopathy.

## Conclusion

Catheter ablation is an excellent option for the treatment of RVOT PVC/VTs and is superior to antiarrhythmic drug treatment. High success rates of >80% are achieved with catheter ablation, even during long-term follow-up and significant complications are rare. Therefore we recommend that ablation may be offered to all patients with symptomatic RVOT PVC/VT refractory to antiarrhythmic drug treatment or when antiarrhythmic drugs are not desired by the patient regardless of the PVC burden. In patients with asymptomatic RVOT PVCs and preserved LVEF, catheter ablation should be considered if the arrhythmia burden is >20-24% to prevent the development of tachycardia-induced cardiomyopathy. In patients with reduced LVEF where a possible etio-pathogenetic link between the PVCs and impaired LVEF is suspected, catheter ablation should be considered unless contraindicated.

Special attention should be given to patients with syncope, very short RVOT-PVC coupling intervals, fast RVOT-VT or polymorphic PVC/VTs. In these cases, evaluation should focus on the exclusion/confirmation of the presence of an underlying structural heart disease with subsequent treatment directed at the management of potential life-threatening arrhythmias.

## References

1. Fuster V, Rydén LE, Cannom DS, Crijns HJ, Curtis AB, Ellenbogen KA, Halperin JL, Le Heuzey JY, Kay GN, Lowe JE, Olsson SB, Prystowsky EN, Tamargo JL, Wann S; Task Force on Practice Guidelines, American College of Cardiology/

American Heart Association; Committee for Practice Guidelines, European Society of Cardiology; European Heart Rhythm Association; Heart Rhythm Society. ACC/AHA/ESC 2006 guidelines for the management of patients with atrial fibrillation-executive summary: a report of the American College of Cardiology/American Heart Association Task Force on Practice Guidelines and the European Society of Cardiology Committee for Practice Guidelines (Writing Committee to Revise the 2001 Guidelines for the Management of Patients with Atrial Fibrillation; Eur Heart J. 2006 Aug;27(16):1979-2030.

2. Hiss RG, Lamb LE. Electrocardiographic findings in 122,043 individuals. Circulation. 1962 Jun;25:947-61.
3. Hinkle LE Jr, Carver ST, Stevens M. The frequency of asymptomatic disturbances of cardiac rhythm and conduction in middle-aged men. Am J Cardiol. 1969 Nov;24(5):629-50.
4. Kennedy HL, Whitlock JA, Sprague MK, Kennedy LJ, Buckingham TA, Goldberg RJ. Long-term follow-up of asymptomatic healthy subjects with frequent and complex ventricular ectopy. N Engl J Med. 1985 Jan 24;312(4):193-7.
5. Viskin S, Belhassen B. Polymorphic ventricular tachyarrhythmias in the absence of organic heart disease: classification, differential diagnosis, and implications for therapy. Prog Cardiovasc Dis. 1998 Jul-Aug;41(1):17-34. Review.
6. Jouven X, Zureik M, Desnos M, Courbon D, Ducimetière P. Long-term outcome in asymptomatic men with exercise-induced premature ventricular depolarizations. N Engl J Med. 2000 Sep 21;343(12):826-33.
7. Frolkis JP, Pothier CE, Blackstone EH, Lauer MS. Frequent ventricular ectopy after exercise as a predictor of death. N Engl J Med. 2003 Feb 27;348(9):781-90. Erratum in: N Engl J Med. 2003 Apr 10;348(15):1508.
8. Chiang BN, Perlman LV, Ostrander LD Jr, Epstein FH. Relationship of premature systoles to coronary heart disease and sudden death in the Tecumseh epidemiologic study. Ann Intern Med. 1969 Jun;70(6):1159-66.
9. Markowitz SM, Weinsaft JW, Waldman L, Petashnick M, Liu CF, Cheung JW, Thomas G, Ip JE, Lerman BB. Reappraisal of Cardiac Magnetic Resonance Imaging in Idiopathic Outflow Tract Arrhythmias. J Cardiovasc Electrophysiol. 2014 Aug 4.
10. Tandri H, Bluemke DA, Ferrari VA, Bomma C, Nasir K, Rutberg J et al. Findings on magnetic resonance imaging of idiopathic right ventricular outflow tachycardia. Am J Cardiol 2004;94:1441 – 5.
11. Globits S, Kreiner G, Frank H, Heinz G, Klaar U, Frey B et al. Significance of morphological abnormalities detected by MRI in patients undergoing successful ablation of right ventricular outflow tract tachycardia. Circulation 1997;96:2633 – 40.
12. Proclemer A, Basadonna PT, Slavich GA, Miani D, Fresco C, Fioretti PM. Cardiac magnetic resonance imaging findings in patients with right ventricular outflow tract premature contractions. Eur Heart J 1997;18:2002 – 10.
13. Molinari G, Sardanelli F, Zandrino F, Parodi RC, Bertero G, Richiardi E, Di Donna P, Gaita F, Masperone MA. Adipose replacement and wall motion abnormalities in right ventricle arrhythmias: evaluation by MR imaging. Retrospective evaluation on 124 patients. Int J Card Imaging. 2000 Apr;16(2):105-15. Erratum in: Int J Card Imaging 2000 Dec;16(6):485.
14. Gaita F, Giustetto C, Di Donna P, Richiardi E, Libero L, Brusin MC, Molinari G, Trevi G. Long-term follow-up of right ventricular monomorphic extrasystoles. J Am Coll Cardiol. 2001 Aug;38(2):364-70.
15. Buxton AE, Waxman HL, Marchlinski FE, Simson MB, Cassidy D, Josephson ME. Right ventricular tachycardia: clinical and electrophysiologic characteristics. Circulation 1983;68:917–27.
16. Miller JM, Pezeshkian NG, Yadav AV. Catheter mapping and ablation of right ventricular outflow tract ventricular tachycardia. J Cardiovasc Electrophysiol 2006;17: 800–2.
17. Lerman BB, Stein KM, Markowitz SM, Mittal S, Iwai S. Ventricular tachycardia in patients with structurally normal hearts. In: Zipes DP ed. Cardiac Electrophysiology: from Cell to Bedside. Philadelphia: Saunders; 2004. p668 – 82.
18. Tanner H, Hindricks G, Schirdewahn P, et al. Outflow tract tachycardia with R/S transition in lead V3: six different anatomic approaches for successful ablation. J Am Coll Cardiol 2005;45:418–423.
19. Dixit S, Gerstenfeld EP, Callans DJ, Marchlinski FE. Electrocardiographic patterns of superior right ventricular outflow tract tachycardias: distinguishing septal and free-wall sites of origin. J Cardiovasc Electrophysiol 2003;14:1–7.
20. Rillig A, Meyerfeldt U, Birkemeyer R, Jung W. Ablation within the sinus of Valsalva for treatment of supraventricular and ventricular tachycardias: what is known so far? Europace. 2009 Sep;11(9):1142-50.
21. Rillig A, Meyerfeldt U, Birkemeyer R, Treusch F, Kunze M, Brasch M, Jung W. Catheter ablation within the sinus of Valsalva- a safe and effective approach for treatment of atrial and ventricular tachycardias. Heart Rhythm. 2008 Sep;5(9):1265-72.
22. Ouyang F, Fotuhi P, Ho SY, Hebe J, Volkmer M, Goya M, Burns M, Antz M, Ernst S, Cappato R, Kuck KH. Repetitive monomorphic ventricular tachycardia originating from the aortic sinus cusp: electrocardiographic characterization for guiding catheter ablation. J Am Coll Cardiol. 2002 Feb 6;39(3):500-8.
23. Ouyang F, Mathew S, Wu S, Kamioka M, Metzner A, Xue Y, Ju W, Yang B, Zhan X, Rillig A, Lin T, Rausch P, Deiß S, Lemes C, Tönnis T, Wissner E, Tilz RR, Kuck KH, Chen M. Ventricular arrhythmias arising from the left ventricular outflow tract below the aortic sinus cusps: mapping and catheter ablation via transseptal approach and electrocardiographic characteristics. Circ Arrhythm Electrophysiol. 2014 Jun;7(3):445-55.
24. Yamada T, McElderry HT, Doppalapudi H, Murakami Y, Yoshida Y, Yoshida N, Okada T, Tsuboi N, Inden Y, Murohara T, Epstein AE, Plumb VJ, Singh SP, Kay GN. Idiopathic ventricular arrhythmias originating from the aortic root prevalence, electrocardiographic and electrophysiologic characteristics, and results of radiofrequency catheter ablation. J Am Coll Cardiol. 2008 Jul 8;52(2):139-47.
25. Hoffmayer KS, Machado ON, Marcus GM, Yang Y, Johnson CJ, Ermakov S, Vittinghoff E, Pandurangi U, Calkins H, Cannom D, Gear KC, Tichnell C, Park Y, Zareba W, Marcus FI, Scheinman MM. Electrocardiographic comparison of ventricular arrhythmias in patients with arrhythmogenic right ventricular cardiomyopathy and right ventricular outflow tract tachycardia.J Am Coll Cardiol. 2011 Aug 16;58(8):831-8.
26. Stec SM, Grabczak EM, Bielicki P, Zaborska B, Krenke R, Kryński T, Dabrowska M, Domagała-Kulawik J, Domeracka-Kolodziej A, Sikorska A, Kulakowski P, Chazan R. Diagnosis and management of premature ventricular complexes-associated chronic cough. Chest. 2009 Jun;135(6):1535-41.
27. Stec S, Zaborska B, Pilus A, Lewandowski P, Kulakowski P. Intermittent claudication caused by frequent premature ventricular complexes: resolution after radiofrequency ablation. Angiology. 2009 Jun-Jul;60(3):378-81.
28. Stec S, Tarnowski W, Binda A, Kulakowski P. Videofluoroscopic modified barium swallow study for premature ventricular complexes-associated dysphagia. Circ Arrhythm Electrophysiol. 2008 Apr;1(1):e1.
29. Stec S, Dabrowska M, Zaborska B, Bielicki P, Maskey-Warzechowska M, Tarnowski W, Chazan R, Kulakowski P. Premature ventricular complex-induced chronic cough and cough syncope. Eur Respir J. 2007 Aug;30(2):391-4.
30. Lelakowski J, Dreher A, Majewski J, Bednarek J. Effects of catheter ablation of idiopathic ventricular ectopic beats on left ventricular function and exercise capacity. Kardiol Pol. 2009 Aug;67(8):847-55.
31. Takemoto M, Yoshimura H, Ohba Y, Matsumoto Y, Yamamoto U, Mohri M, Yamamoto H, Origuchi H. Radiofrequency catheter ablation of premature ventricular complexes from right ventricular outflow tract improves left ventricular dilation and clinical status in patients without structural heart disease. J Am Coll Cardiol. 2005 Apr 19;45(8):1259-65.
32. Pytkowski M, Maciag A, Jankowska A, Kowalik I, Kraska A, Farkowski MM,

Golicki D, Szwed H. Quality of life improvement after radiofrequency catheter ablation of outflow tract ventricular arrhythmias in patients with structurally normal heart. Acta Cardiol. 2012 Apr;67(2):153-9.

33. Krittayaphong R, Sriratanasathavorn C, Bhuripanyo K, Raungratanaamporn O, Soongsawang J, Khaosa-ard B, Kangkagate C. One-year outcome after radiofrequency catheter ablation of symptomatic ventricular arrhythmia from right ventricular outflow tract. Am J Cardiol 2002; 89: 1269-74.
34. Noda T, Shimizu W, Taguchi A, et al. Malignant entity of idiopathic ventricular fibrillation and polymorphic ventricular tachycardia initiated by premature extrasystoles originating from right ventricular outflow tract. J Am Coll Cardiol 2005;46:1288 –1294.
35. Viskin S, Rosso R, Rogowski O, Belhassen B. The "short-coupled" variant of right ventricular outflow ventricular tachycardia: a not-so-benign form of benign ventricular tachycardia? J Cardiovasc Electrophysiol 2005;16:912–916.
36. Grogan M, Smith HC, Gersh BJ, Wood DL. Left ventricular dysfunction due to atrial fibrillation in patients initially believed to have idiopathic dilated cardiomyopathy. Am J Cardiol. 1992;69:1570–1573.
37. Shinbane JS, Wood MA, Jensen DN, Ellenbogen KA, Fitzpatrick AP, Scheinman MM. J Am Coll Cardiol. 1997 Mar 15;29(4):709-15. Review.
38. Lachsinger JA, Steinberg JS. Resolution of cardiomyopathy after ablation of atrial flutter. J Am Coll Cardiol. 1998;32:205–210.
39. Catheter Ablation of Permanent Junctional Reciprocating Tachycardia With Radiofrequency Current. F. Gaita, M. Haissaguerre, C. Giustetto, B. Fischer, R. Ricyucardi, E.Richiardi, M.Scaglione, F. Lamberti, J. F.Warin. Journal of American College of Cardiology 1995 Mar 1; 25(3): 648-54.
40. Umana E, Solares CA, Alpert MA. Tachycardia-induced cardiomyopathy. Am J Med. 2003;114:51–55.
41. Vijgen J, Hill P, Biblo LA, Carlson MD. Tachycardia-induced cardiomyopathy secondary to right ventricular outflow tract tachycardia: improvement of left ventricular systolic function after radiofrequency catheter ablation of the arrhythmia. J Cardiovasc Electrophysiol. 1997; 8:445– 450.
42. Grimm W, Menz, Hoffmann J, Maisch B. Reversal of tachycardia induced cardiomyopathy following ablation of repetitive monomorphic right ventricular outflow tract tachycardia. Pacing Clin Electrophysiol. 2001;24:166 –171.
43. Lerman BB, Stein KM, Markowitz SM, Mittal S, Slotwiner DJ. Ventricular arrhythmias in normal hearts. Cardiology Clin. 2000;18:265–291.
44. Chugh SS, Shen WK, Luria DM, Smith HC. First evidence of premature ventricular complex-induced cardiomyopathy: a potentially reversible cause of heart failure. J Cardiovasc Electrophysiol. 2000 Mar;11(3):328-9.
45. Hoffman BF, Bartelstone HJ, Scherlag BJ, Cranefield PF. Effects of postextrasystolic potentiation on normal and failing hearts. Bull N Y Acad Med 1965; 41:498–534.
46. Chardack WM, Gage AA, Dean DC. Paired and coupled electrical stimulation of the heart. Bull N Y Acad Med 1965;41:462–480.
47. Shiraishi H, Ishibashi K, Urao N, Tsukamoto M, Hyogo M, Keira N, Hirasaki S, Shirayama T, Nakagawa M. A case of cardiomyopathy induced by premature ventricular complexes. Circ J. 2002 Nov;66(11):1065-7.
48. Ezzat VA, Liew R, Ward DE. Catheter ablation of premature ventricular contraction-induced cardiomyopathy. Nat Clin Pract Cardiovasc Med. 2008 May;5(5):289-93.
49. Redfearn DP, Hill JD, Keal R, Toff WD, Stafford PJ. Left ventricular dysfunction resulting from frequent unifocal ventricular ectopics with resolution following radiofrequency ablation. Europace. 2003 Jul;5(3):247-50.
50. Lauck G, Burkhardt D, Manz M. Radiofrequency catheter ablation of symptomatic ventricular ectopic beats originating in the right outflow tract. Pacing Clin Electrophysiol. 1999 Jan;22(1 Pt 1):5-16.
51. Carballeira Pol L, Deyell MW, Frankel DS, Benhayon D, Squara F, Chik W, Kohari M, Deo R, Marchlinski FE. Ventricular premature depolarization QRS duration as a new marker of risk for the development of ventricular premature depolarization-induced cardiomyopathy. Heart Rhythm. 2014 Feb;11(2):299-306.
52. Del Carpio Munoz F, Syed FF, Noheria A, Cha YM, Friedman PA, Hammill SC, Munger TM, Venkatachalam KL, Shen WK, Packer DL, Asirvatham SJ. Characteristics of premature ventricular complexes as correlates of reduced left ventricular systolic function: study of the burden, duration, coupling interval, morphology and site of origin of PVCs. J Cardiovasc Electrophysiol. 2011 Jul;22(7):791-8.
53. Baman TS, Lange DC, Ilg KJ, Gupta SK, Liu TY, Alguire C, Armstrong W, Good E, Chugh A, Jongnarangsin K, Pelosi F Jr, Crawford T, Ebinger M, Oral H, Morady F, Bogun F. Relationship between burden of premature ventricular complexes and left ventricular function. Heart Rhythm. 2010 Jul;7(7):865-9.
54. Efremidis M, Letsas KP, Sideris A, Kardaras F. Reversal of premature ventricular complex-induced cardiomyopathy following successful radiofrequency catheter ablation. Europace. 2008 Jun;10(6):769-70.
55. Satish OS, Yeh KH, Wen MS, Wang CC. Premature ventricular contraction-induced concealed mechanical bradycardia and dilated cardiomyopathy. J Cardiovasc Electrophysiol. 2005 Jan;16(1):88-91.
56. Bhushan M, Asirvatham SJ. The conundrum of ventricular arrhythmia and cardiomyopathy: which abnormality came first? Curr Heart Fail Rep. 2009 Mar;6(1):7-13. Review.
57. Srivathsan KS, Bunch TJ, Asirvatham SJ, Edwards WD, Friedman PA, Munger TM, Hammill SC, Cha YM, Brady PA, Jahangir A, Bradley DJ, Rea RF, Packer DL, Shen WK. Mechanisms and utility of discrete great arterial potentials in the ablation of outflow tract ventricular arrhythmias. Circ Arrhythm Electrophysiol. 2008 Apr;1(1):30-8.
58. Ebrille E, Chandra VM, Syed F, Del Carpio Munoz F, Nanda S, Hai JJ, Cha YM, Friedman PA, Hammill SC, Munger TM, Venkatachalam KL, Packer DL, Asirvatham SJ. Distinguishing ventricular arrhythmia originating from the right coronary cusp, peripulmonic valve area, and the right ventricular outflow tract: utility of lead I. J Cardiovasc Electrophysiol. 2014 Apr;25(4):404-10.
59. Yarlagadda RK, Iwai S, Stein KM, Markowitz SM, Shah BK, Cheung JW, Tan V, Lerman BB, Mittal S. Reversal of cardiomyopathy in patients with repetitive monomorphic ventricular ectopy originating from the right ventricular outflow tract. Circulation. 2005 Aug 23;112(8):1092-7.
60. Shanmugam N, Chua TP, Ward D. 'Frequent' ventricular bigeminy--a reversible cause of dilated cardiomyopathy. How frequent is 'frequent'? Eur J Heart Fail. 2006 Dec;8(8):869-73.
61. Kanei Y, Friedman M, Ogawa N, et al.: Frequent premature ventricular complexes originating from the right ventricular outflow tract are associated with left ventricular dysfunction. Ann Noninvasive Electrocardiol 2008, 13:81–85.
62. Olgun H, Yokokawa M, Baman T, Kim HM, Armstrong W, Good E, Chugh A, Pelosi F Jr, Crawford T, Oral H, Morady F, Bogun F. The role of interpolation in PVC-induced cardiomyopathy. Heart Rhythm. 2011 Jul;8(7):1046-9.
63. Yokokawa M, Kim HM, Good E, Crawford T, Chugh A, Pelosi F Jr, Jongnarangsin K, Latchamsetty R, Armstrong W, Alguire C, Oral H, Morady F, Bogun F. Impact of QRS duration of frequent premature ventricular complexes on the development of cardiomyopathy. Heart Rhythm. 2012 Sep;9(9):1460-4.
64. Del Carpio Munoz F, Syed FF, Noheria A, Cha YM, Friedman PA, Hammill SC, Munger TM, Venkatachalam KL, Shen WK, Packer DL, Asirvatham SJ.Characteristics of premature ventricular complexes as correlates of reduced left ventricular systolic function: study of the burden, duration, coupling interval, morphology and site of origin of PVCs. J Cardiovasc Electrophysiol. 2011 Jul;22(7):791-8.
65. Bleeker GB, Schalij MJ, Molhoek SG, Verwey HF, Holman ER, Boersma E, Steendijk P, Van Der Wall EE, Bax JJ. Relationship between QRS duration and left ventricular dyssynchrony in patients with end-stage heart failure. J Cardiovasc

Electrophysiol. 2004 May;15(5):544-9.
66. Yokokawa M, Good E, Crawford T, Chugh A, Pelosi F Jr, Latchamsetty R, Jongnarangsin K, Armstrong W, Ghanbari H, Oral H, Morady F, Bogun F. Recovery from left ventricular dysfunction after ablation of frequent premature ventricular complexes. Heart Rhythm. 2013 Feb;10(2):172-5.).
67. Deyell MW, Park KM, Han Y, Frankel DS, Dixit S, Cooper JM, Hutchinson MD, Lin D, Garcia F, Bala R, Riley MP, Gerstenfeld E, Callans DJ, Marchlinski FE. Predictors of recovery of left ventricular dysfunction after ablation of frequent ventricular premature depolarizations. Heart Rhythm. 2012 Sep;9(9):1465-72.
68. Huizar JF, Kaszala K, Potfay J, Minisi AJ, Lesnefsky EJ, Abbate A, Mezzaroma E, Chen Q, Kukreja RC, Hoke NN, Thacker LR 2nd, Ellenbogen KA, Wood MA. Left ventricular systolic dysfunction induced by ventricular ectopy: a novel model for premature ventricular contraction-induced cardiomyopathy. Circ Arrhythm Electrophysiol. 2011 Aug;4(4):543-9.
69. Duffee DF, Shen WK, Smith HC. Suppression of frequent premature ventricular contractions and improvement of left ventricular function in patients with presumed idiopathic dilated cardiomyopathy. Mayo Clin Proc. 1998;73:430–433.
70. Lerman BB, Stein KM, Markowitz SM. Idiopathic right ventricular outflow tract tachycardia: a clinical approach. Pacing Clin Electrophysiol, 1996; 19: 2120–137.
71. Aliot EM, Stevenson WG, Almendral-Garrote JM, Bogun F, Calkins CH, Delacretaz E, Bella PD, Hindricks G, Jaïs P, Josephson ME, Kautzner J, Kay GN, Kuck KH, Lerman BB, Marchlinski F, Reddy V, Schalij MJ, Schilling R, Soejima K, Wilber D; European Heart Rhythm Association; European Society of Cardiology; Heart Rhythm Society. EHRA/HRS Expert Consensus on Catheter Ablation of Ventricular Arrhythmias: developed in a partnership with the European Heart Rhythm Association (EHRA), a Registered Branch of the European Society of Cardiology (ESC), and the Heart Rhythm Society (HRS); in collaboration with the American College of Cardiology (ACC) and the American Heart Association (AHA).Europace. 2009 Jun;11(6):771-817.
72. Krittayaphong R, Bhuripanyo K, Punlee K, Kangkagate C, Chaithiraphan S. Effect of atenolol on symptomatic ventricular arrhythmia without structural heart disease: a randomized placebo-controlled study. Am Heart J, 2002; 144: e10. 11.
73. Capucci A, Frabetti L, Gubelli S et al. Tocainide and metoprolol: an efficacious therapeutic combination in the treatment of premature ventricular beats. Clin Cardiol, 1989; 12: 322–331.
74. Stec S, Sikorska A, Zaborska B, Kryński T, Szymot J, Kułakowski P. Benign symptomatic premature ventricular complexes: short- and long-term efficacy of antiarrhythmic drugs and radiofrequency ablation. Kardiol Pol. 2012;70(4):351-8.
75. Niwano S, Wakisaka Y, Niwano H et al. Prognostic significance of frequent premature ventricular contractions originating from the ventricular outflow tract in patients with normal left ventricular function. Heart, 2009; 95: 1230–1237.
76. Zipes DP, Camm AJ, Borggrefe M, Buxton AE, Chaitman B, Fromer M, Gregoratos G, Klein G, Moss AJ, Myerburg RJ, Priori SG, Quinones MA, Roden DM, Silka MJ, Tracy C, Blanc JJ, Budaj A, Dean V, Deckers JW, Despres C, Dickstein K, Lekakis J, McGregor K, Metra M, Morais J, Osterspey A, Tamargo JL, Zamorano JL, Smith SC Jr, Jacobs AK, Adams CD, Antman EM, Anderson JL, Hunt SA, Halperin JL, Nishimura R, Ornato JP, Page RL, Riegel B; American College of Cardiology/American Heart Association Task Force; European Society of Cardiology Committee for Practice Guidelines; European Heart Rhythm Association and the Heart Rhythm Society. ACC/AHA/ESC 2006 guidelines for management of patients with ventricular arrhythmias and the prevention of sudden cardiac death--executive summary: A report of the American College of Cardiology/American Heart Association Task Force and the European Society of Cardiology Committee for Practice Guidelines (Writing Committee to Develop Guidelines for Management of Patients with Ventricular Arrhythmias and the Prevention of Sudden Cardiac Death) Developed in collaboration with the European Heart Rhythm Association and the Heart Rhythm Society. Eur Heart J. 2006 Sep;27(17):2099-140.
77. Preliminary report: effect of encainide and flecainide on mortality in a randomized trial of arrhythmia suppression after myocardial infarction. The Cardiac Arrhythmia Suppression Trial (CAST) Investigators [no authors listed]. N Engl J Med 1989, 321:406–412.
78. Singh BN. Current antiarrhythmic drugs: an overview of mechanisms of action and potential clinical utility. J Cardiovasc Electrophysiol. 1999 Feb;10(2):283-301. Review.
79. Zhong L, Lee YH, Huang XM, Asirvatham SJ, Shen WK, Friedman PA, Hodge DO, Slusser JP, Song ZY, Packer DL, Cha YM. Relative efficacy of catheter ablation vs antiarrhythmic drugs in treating premature ventricular contractions: a single-center retrospective study. Heart Rhythm. 2014 Feb;11(2):187-93.
80. Katritsis DG, Zareba W, Camm AJ. Nonsustained ventricular tachycardia. J Am Coll Cardiol. 2012 Nov 13;60(20):1993-2004.
81. Krittayaphong R, Sriratanasathavorn C, Dumavibhat C, Pumprueg S, Boonyapisit W, Pooranawattanakul S et al. Electrocardiographic predictors of long-term outcomes after radiofrequency ablation in patients with right- ventricular outflow tract tachycardia. Europace 2006;8:601–6.
82. Vestal M, Wen MS, Yeh SJ, Wang CC, Lin FC, Wu D. Electrocardiographic pre- dictors of failure and recurrence in patients with idiopathic right ventricular outflow tract tachycardia and ectopy who underwent radiofrequency catheter ablation. J Electrocardiol 2003;36:327 – 32.
83. Coggins DL, Lee RJ, Sweeney J, Chein WW, Van HG, Epstein L et al. Radiofrequency catheter ablation as a cure for idiopathic tachycardia of both left and Right ventricular origin. J Am Coll Cardiol 1994;23:1333 – 41.
84. Vohra J, Shah A, Hua W, Gerloff J, Riters A. Radiofrequency ablation of idiopathic ventricular tachycardia. Aust N Z J Med. 1996 Apr;26(2):186-94.
85. Talwar KK, Singh B, Goel P, Saxena A, Bahl VK, Kaul U, Wasir HS. Radiofrequency ablation of idiopathic ventricular tachycardia. Indian Heart J. 1996 Jan-Feb;48(1):49-52.
86. Rodriguez LM, Smeets JL, Timmermans C, Wellens HJ. Predictors for successful ablation of right- and left-sided idiopathic ventricular tachycardia. Am J Cardiol. 1997 Feb 1;79(3):309-14.
87. Bunch TJ, Day JD. Right meets left: a common mechanism underlying right and left ventricular outflow tract tachycardias. J Cardiovasc Electrophysiol 2006;17: 1059 – 61,
88. Farzaneh-Far A, Lerman BB. Idiopathic ventricular outflow tract tachycardia. Heart 2005; 91:136 – 8.
89. Iwai S, Cantillon DJ, Kim RJ, Markowitz SM, Mittal S, Stein KM, Shah BK et al. Right and left ventricular outflow tract tachycardias: evidence for a common electrophysiologic mechanism. J CardiovascElectrophysiol 2006;17:1052 – 8.
90. Zhang F, Yang B, Chen H, Ju W, Kojodjojo P, Cao K, Chen M. Noncontact mapping to guide ablation of right ventricular outflow tract arrhythmias. Heart Rhythm. 2013 Dec;10(12):1895-902.
91. Schneider HE, Kriebel T, Jung K, Gravenhorst VD, Paul T. Catheter ablation of idiopathic left and right ventricular tachycardias in the pediatric population using noncontact mapping. Heart Rhythm. 2010 Jun;7(6):731-9.
92. Friedman PA, Asirvatham SJ, Grice S, Glikson M, Munger TM, Rea RF, Shen WK, Jahanghir A, Packer DL, Hammill SC. Noncontact mapping to guide ablation of right ventricular outflow tract tachycardia. J Am Coll Cardiol. 2002;39:1808 –1812.
93. Joshi S, Wilber DJ. Ablation of idiopathic right ventricular outflow tract tachycardia: current perspectives. J Cardiovasc Electrophysiol 2005;16 (Suppl. 1):S52 – 8.
94. Lamberti F, Calo' L, Pandozi C, Castro A, Loricchio ML, Boggi A, Toscano S, Ricci R, Drago F, Santini M. Radiofrequency catheter ablation of idiopathic left ventricular outflow tract tachycardia: utility of intracardiac echocardiography. J Cardiovasc Electrophysiol. 2001 May;12(5):529-35.)

95. Kurzidim K et al. (2005) Cryocatheter ablation of right ventricular outflow tract tachycardia. J Cardiovasc Electrophysiol 16: 366–369.
96. Zhu DW, Maloney JD, Simmons TW, Nitta J, Fitzgerald DM, Trohman RG, Khoury DS, Saliba W, Belco KM, Rizo-Patron C, et al. Radiofrequency catheter ablation for management of symptomatic ventricular ectopic activity. J Am Coll Cardiol. 1995 Oct;26(4):843-9.
97. Tsai CH, Lee TM, Su SF. Regression of ventricular repolarisation inhomogeneity after aortic bileaflet valve replacement in patients with aortic stenosis. Int J Cardiol. 1999 Jul 31;70(2):141-8.
98. Okumura Y, Watanabe I, Nakai T, Ohkubo K, Kofune T, Ashino S, Kofune M, Nagashima K, Hiro T, Hirata A, Nikaido M, Hirayama A. A quantitative and qualitative analysis of the virtual unipolar electrograms from non-contact mapping of right or left-sided outflow tract premature ventricular contractions/ventricular tachycardia origins. J Interv Card Electrophysiol. 2011 Jan;30(1):17-25.
99. Pytkowski M, Maciag A, Jankowska A, Kowalik I, Kraska A, Farkowski MM, Golicki D, Szwed H. Quality of life improvement after radiofrequency catheter ablation of outflow tract ventricular arrhythmias in patients with structurally normal heart. Acta Cardiol. 2012 Apr;67(2):153-9.
100. Huang CX, Liang JJ, Yang B, Jiang H, Tang QZ, Liu XJ, Wan WG, Jian XL. Quality of life and cost for patients with premature ventricular contractions by radiofrequency catheter ablation. Pacing Clin Electrophysiol. 2006 Apr;29(4):343-50.