

Are Balloon Based Strategies Better Than Conventional Radiofrequency Catheter Ablation: Exploring New Frontiers In The Treatment Of Atrial Fibrillation

Alexander Fuernkranz MD, Julian Chun MD, Boris Schmidt MD, Karl-Heinz Kuck MD, Feifan Ouyang MD

II. Medizinische Abteilung, Asklepios Klinik St. Georg, Hamburg, Germany

Abstract

Paroxysmal atrial fibrillation can be eliminated with continuous circular linear lesions around the pulmonary veins using radiofrequency ablation. Due to the technical complexity of this procedure balloon-based devices have been developed to simplify pulmonary vein isolation. Cryoballoon ablation provides excellent safety and is technically less demanding when compared to radiofrequency catheter ablation in selected patients. In this review, advantages as well as drawbacks of this emerging technology in relation to standard catheter ablation are discussed.

Introduction

Atrial fibrillation (AF) is the most common cardiac arrhythmia causing considerable and increasing morbidity and mortality burdens on the population. Identification of electrical triggers from the pulmonary veins (PV) inducing paroxysmal AF led to potentially curative treatment strategies by radiofrequency (RF) ablation.¹ Since this condition has become amenable to ablative therapy there is a constant rise in the number of catheter ablations for AF performed worldwide.² As our understanding of the complex pathophysiology of this arrhythmia increases, the advantages of circular linear lesions to completely isolate the PVs from the left atrium (LA) have become obvious.^{3,4} Inclusion of the LA-PV junction into the isolated regions serves the double purpose of eliminating arrhythmogen-

ic substrate as well as adding a safety margin to the lesions, decreasing the incidence of postablation PV stenosis, currently reported at 2-7 %.⁵ However, to create these long ablation lines with point-to-point lesions using catheters originally designed for focal or comparatively short linear ablations, such as at the cavotricuspid isthmus, is technically demanding and time consuming. Thus, considerable effort is put into the development of balloon-based techniques for PV isolation using a variety of energy sources to simplify PV isolation and add safety by decreasing the incidence of PV stenosis. In this review, we will summarize to what extent the aforementioned goals are met with current-design balloons. As clinical experience is most extensive with the use of cryoenergy, focus will be on cryoballoon ablation.

Corresponding Address: Samuel J. Asirvatham, M.D., Division of Cardiovascular Diseases, Associate Professor of Medicine, Mayo Clinic College of Medicine, 200 First Street SW, Rochester, MN 55905. Submitted on: 23rd December 2008 Accepted on: 23rd January 2009. conflict of interest: Authors have nothing to declare

Cryothermal Lesions

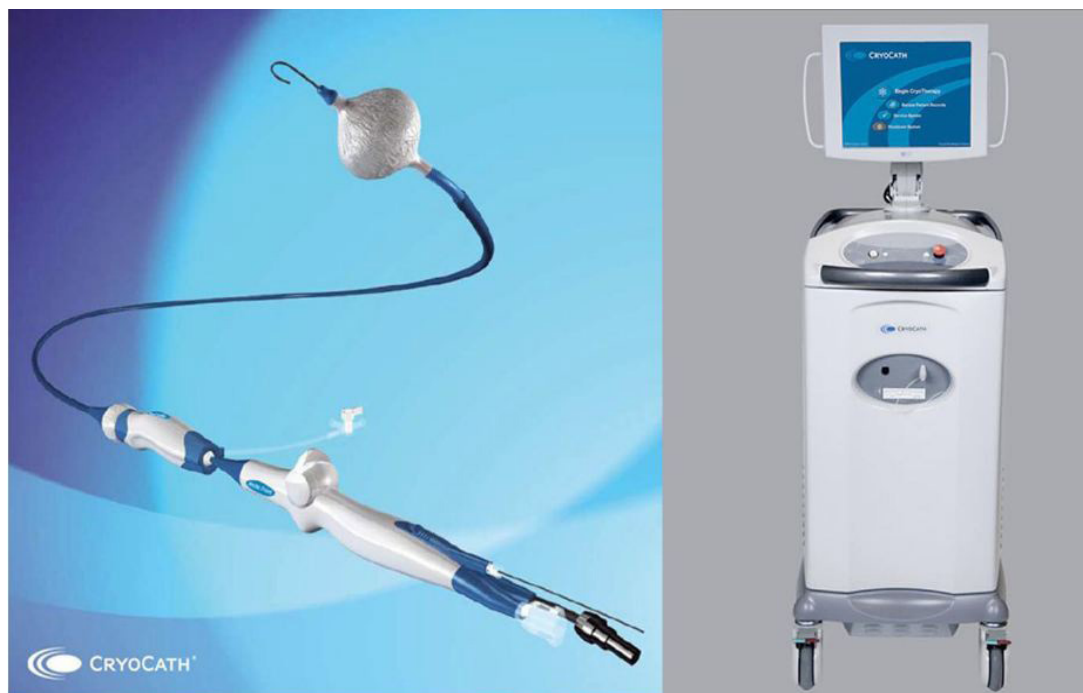Tissue injury by freezing occurs due to direct cellular damage as well as microcirculatory failure shortly after tissue thawing. The prime mechanism of cell death is formation of intracellular ice crystals at rapid freezing rates of about 100°C/min., which occurs only close to the cryocatheter, highlighting the need for good tissue contact. Delayed cellular death occurs for several days after freezing by apoptosis.⁶ Duration of freezing affects tissue damage particularly at some distance to the cryothermal source where growing of ice crystals is slower. Repeated freeze-thaw cycles have been shown to increase tissue destruction in experimental studies.⁷ Lesions created by cryothermal energy differ in several respects from those created by conventional radiofrequency (RF) ablation. Cryolesions show intact endothelial lining⁸ and hence are associated with less thrombus formation as compared to RF lesions.⁹ Consequently, the likelihood of thromboembolic events is less with cryothermal tissue injury.¹⁰ While RF lesions show progressive contraction, cryolesions are associated with minimal collagen formation and tissue shrinkage.¹¹ This is a clear advantage in the face of PV stenosis as a major complication reported after RF ablation.⁵ Accordingly, no PV

stenosis has been observed in experimental animal and human clinical studies when using cryothermal energy.

Cryoballoon: The Technique

The cryoballoon catheter (Arctic Front©, CryoCath Technologies, Montreal, Canada) consists of a double-walled balloon, where the refrigerant N₂O is delivered into the inner lumen, undergoing a liquid-to-gas phase change resulting in rapid cooling down to approximately -80°C (Figure 1). Two balloon sizes are available: 23 and 28 mm diameters. The bidirectionally deflectable catheter is equipped with central lumina for the insertion of a guide wire and injection of contrast medium. After placement of the guide wire into a PV, the catheter is advanced over this wire near the PV ostium where the balloon is inflated. Once in position, a PV angiogram is performed via the distal end of the balloon to ensure circumferential tissue contact. The catheter is used in conjunction with a deflectable 12-French transeptal sheath (FlexCath ©, CryoCath Technologies, Montreal, Canada), which contributes to the operators ability to position the balloon within the left atrium. Given the principals of cryogenic tissue injury, a freezing time of 5 minutes is considered sufficient.¹² Based

Figure 1: The Arctic Front© Cryoballoon Catheter with the FlexCath© steerable 12F sheath. To the right, the Cryoconsole© main apparatus is shown (Pictures provided by CryoCath Technologies, Montreal, Canada).



on experimental data, repeated freezing may augment lesion quality. If this translates into clinical benefit is currently under investigation.

Cryoballoon Versus RF Ablation: Advantages

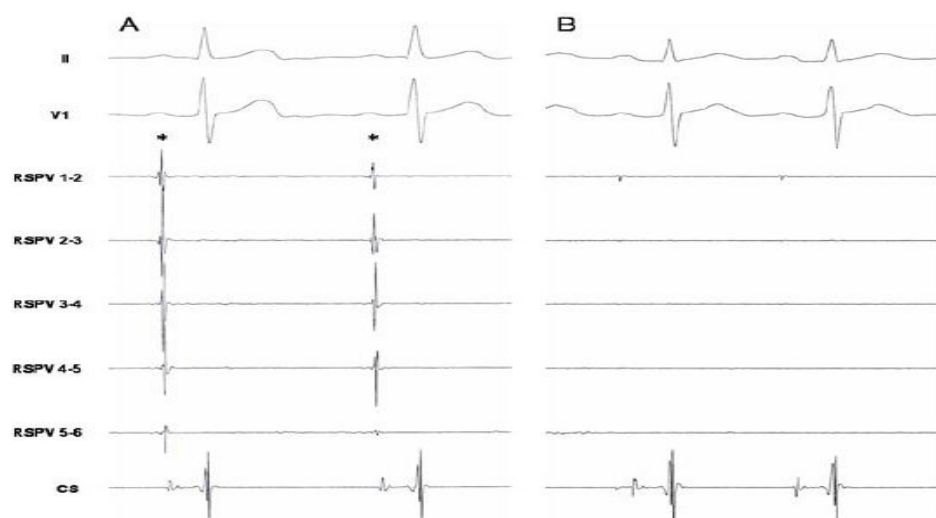
Performing circular linear lesions to isolate ipsilateral pairs of PV ostia from the LA by RF point-point ablation constitutes one of the most complex cardiac catheterization procedures, requiring considerable operator experience. On the other hand, balloon-based catheter ablation systems have the potential to isolate the PV with a single application (Figure 2). Learning curves exhibit rapid improvement.¹² The entire procedure can be monitored by fluoroscopy, obviating the need for additional electro-anatomical mapping or imaging by CT or NMR. Thus, use of balloon based systems may potentially simplify PV isolation in most patients. Concerning cryoballoon ablation, however, several technical aspects have to be noted. To achieve continuous lesions, an occlusive balloon position at target PV sites as confirmed by PV angiography is necessary to limit convective heating by leaking blood flow⁸ (Figure 3). This can be challenging in individual anatomies especially at the right inferior PV, such that additional RF “touch-up” lesions may be necessary to isolate the vein. However, in our experience the vast majority of veins can be acutely isolated with only the big (28 mm) balloon if special ablation techniques

are used.¹³ This strategy (“single big balloon technique”) also adds safety to the procedure because a high balloon-to-ostium diameter ratio restricts the level of isolation to the LA-PV junction. Conventional RF ablation of AF is associated with significant risk. In a worldwide survey representing more than 7000 patients major complications were reported at 6%, including a 1.6% risk for PV stenosis, as well as a 0.9% risk for cerebrovascular events.² Given the favorable properties of cryothermal lesions the latter complications should be decreased using cryoballoon ablation. Indeed, no evidence of PV stenosis or cerebral ischemia has thus far been reported with this technique.^{12,14} Although these data need to be confirmed in larger trials, initial clinical experience indicates a very low risk using cryoballoon ablation in selected patients.

Cryoballoon Versus RF Ablation: Disadvantages

Phrenic nerve (PN) injury (Figure 4), however, occurred with increased frequency in cryoballoon-based as compared to conventional ablation of AF, though it seems to be reversible in the majority of cases.¹² This complication may happen regardless of the energy source used^{12,15-17} as a consequence of the close anatomic relationship between the course of the right PN and the right superior PV.¹⁸ PN injury can be avoided by mapping of the right PN with highoutput pacing in the superior caval

Figure 2: Right superior PV (RSPV) recordings before (A) and after (B) cryoballoon ablation. PV isolation is demonstrated by the lack of a PV spike (asterisk) after cryothermal energy deployment



vein before and continuous pacing during ablation of rightsided PVs (Figure 3). In case of loss of PN capture cryoablation is immediately stopped. Furthermore, as the likelihood of PN damage increases with more distal balloon positions beyond the PV ostium caution should be observed in choosing the adequate balloon dimension or selecting patients eligible for balloon PV isolation. Thus, in patients with right-sided PV diameters of ≥ 26 mm a conventional strategy should be considered.¹³ In the future, a larger (>28 mm) cryoballoon diameter may become available to avoid distal balloon ablation at large septal PVs. Another anatomical obstacle to balloon PV isolation is a long common left-sided trunk reported in 7% of patients in one series.¹⁹ Again, this would lead to ablation in the vein rather than at the LA-PV junction. Reports on chronic success after cryoballoon PV isolation vary due to different follow-up methods.^{12,20} In our cohort, we observed a 52% success rate free of AF after a mean follow up of 312 ± 190 days without a blanking period.¹³ In contrast, circumferential PV isolation using RF energy in patients with paroxysmal AF is associated with

the maintenance of sinus rhythm in 76% after the first procedure.³ Thus, recurrence rates seem to be higher with cryoballoon PV isolation compared to the conventional approach. If this difference is related to cryoenergy or balloon-based techniques per se, or due to different follow-up methods such as exclusion of a blanking period is currently not known. In those patients of our cohort in whom drug-refractory symptomatic recurrence led to a repeat procedure, reconduction of at least one PV was noted and subsequently eliminated using conventional RF catheters.

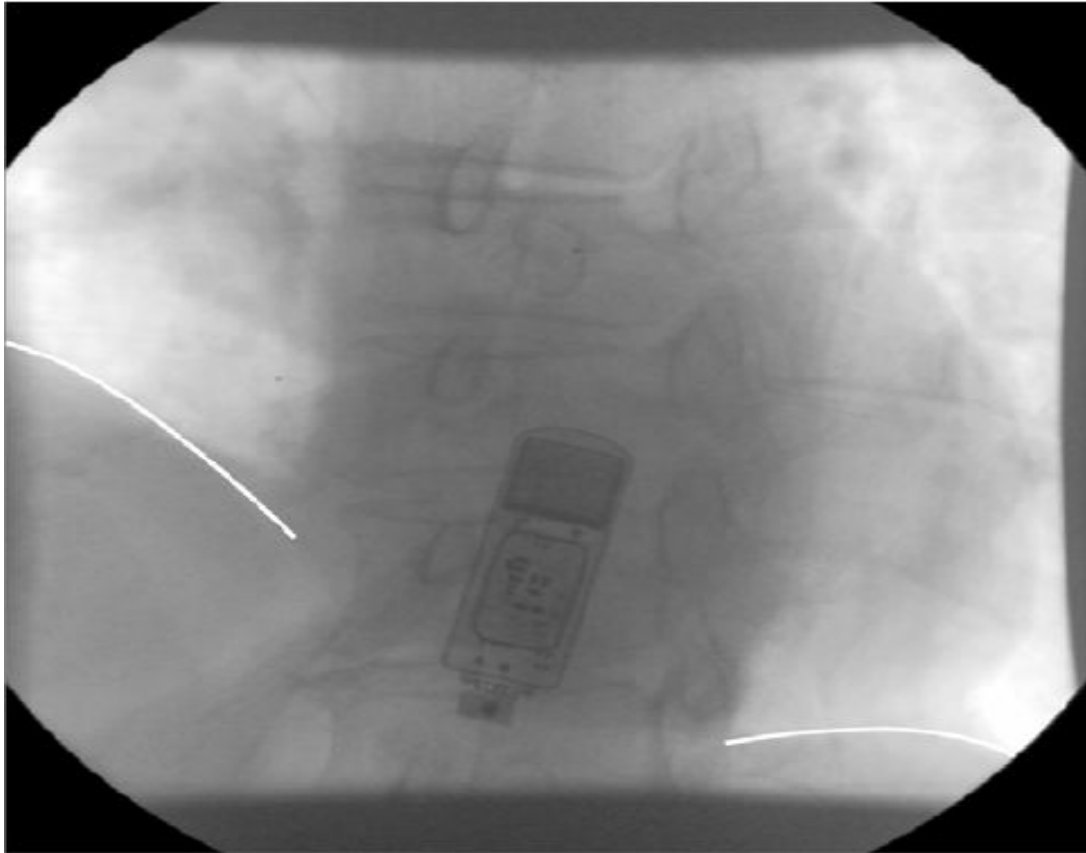
Conclusion

Cryoballoon-based PV isolation in conjunction with the “single big balloon” technique provides excellent safety and is technically less demanding when compared to RF catheter ablation in selected patients. Thus, the device constitutes a valuable augmentation of the electrophysiologists armamentarium to treat paroxysmal AF. Chronic lesion assessment after cryoballoon PV isolation needs to be addressed in future studies.

Figure 3: The cryoballoon in occlusive position at the right superior PV ostium as confirmed by PV angiography (RAO view). A octapolar catheter is in position to perform phrenic nerve pacing in the superior caval vein (asterisk)

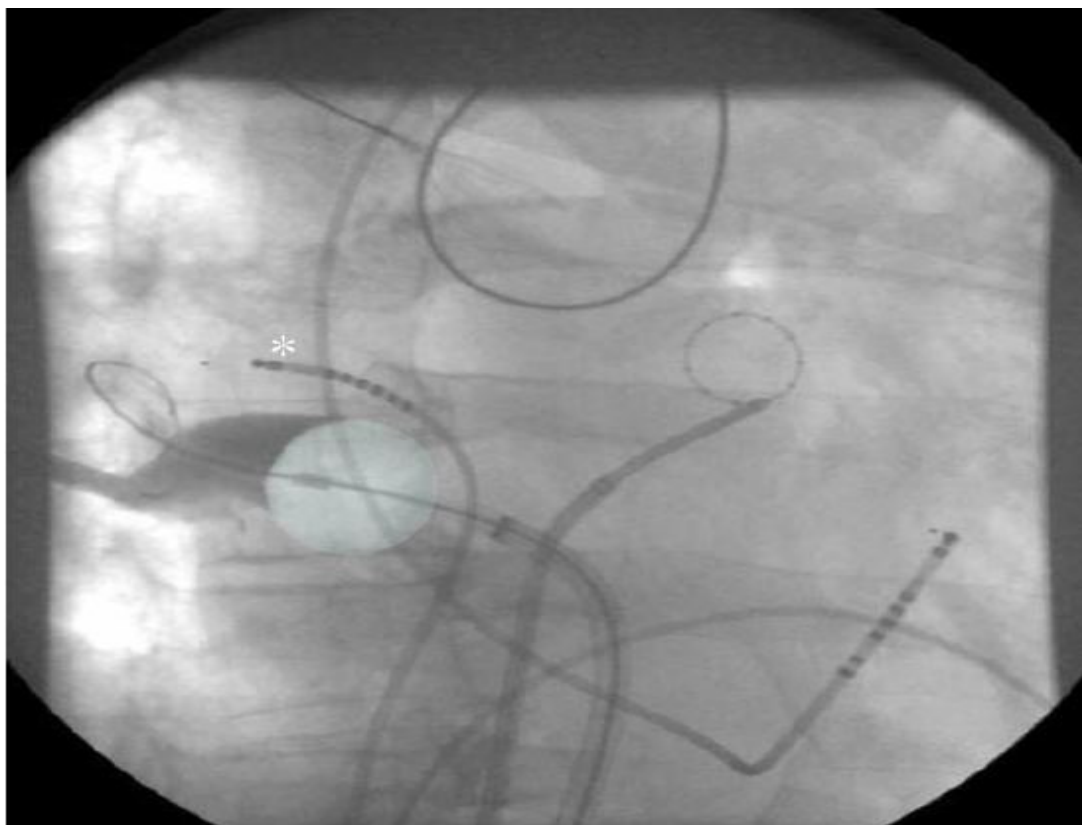

Figure 4: Fluoroscopic demonstration of right-sided phrenic nerve palsy following cryoballoon ablation at the right superior PV (AP view in inspiration, a loop recorder had been implanted in this patient)



References

- Haissaguerre M, Jais P, Shah DC, Takahashi A, Hocini M, Quiniou G, Garrigue S, Le Mouroux A, Le Metayer P, Clementy J. Spontaneous Initiation of Atrial Fibrillation by Ectopic Beats Originating in the Pulmonary Veins. *N Engl J Med*. 1998;339:659-666.
- Cappato R, Calkins H, Chen SA, Davies W, Iesaka Y, Kalman J, Kim YH, Klein G, Packer D, Skanes A. Worldwide Survey on the Methods, Efficacy, and Safety of Catheter Ablation for Human Atrial Fibrillation. *Circulation*. 2005;111:1100-1105.
- Ouyang F, Bansch D, Ernst S, Schaumann A, Hachiya H, Chen M, Chun J, Falk P, Khanedani A, Antz M, Kuck KH. Complete Isolation of Left Atrium Surrounding the Pulmonary Veins: New Insights From the Double-Lasso Technique in Paroxysmal Atrial Fibrillation. *Circulation*. 2004;110:2090-2096.
- Ouyang F, Antz M, Ernst S, Hachiya H, Mavrakis H, Deger FT, Schaumann A, Chun J, Falk P, Hennig D, Liu X, Bansch D, Kuck KH. Recovered Pulmonary Vein Conduction as a Dominant Factor for Recurrent Atrial Tachyarrhythmias After Complete Circular Isolation of the Pulmonary Veins: Lessons From Double Lasso Technique. *Circulation*. 2005;111:127-135.
- Packer DL, Keelan P, Munger TM, Breen JF, Asirvatham S, Peterson LA, Monahan KH, Hauser MF, Chandrasekaran K, Sinak LJ, Holmes DR, Jr. Clinical Presentation, Investigation, and Management of Pulmonary Vein Stenosis Complicating Ablation for Atrial Fibrillation. *Circulation*. 2005;111:546-554.
- Baust JM, Vogel MJ, Van Buskirk R, Baust JG. A molecular basis of cryopreservation failure and its modulation to improve cell survival. *Cell Transplant*. 2001;10:561-571.
- Tse HF, Ripley KL, Lee KL, Siu CW, Van Vleet JF, Pelkey WL, Lau CP. Effects of temporal application parameters on lesion dimensions during transvenous catheter cryoablation. *J Cardiovasc Electrophysiol*. 2005;16:201-204.
- Sarabanda AV, Bunch TJ, Johnson SB, Mahapatra S, Milton MA, Leite LR, Bruce GK, Packer DL. Efficacy and safety of circumferential pulmonary vein isolation using a novel cryothermal balloon ablation system. *J Am Coll Cardiol*. 2005;46:1902-1912.
- Khairy P, Chauvet P, Lehmann J, Lambert J, Macle L, Tanguay JF, Sirois MG, Santoianni D, Dubuc M. Lower Incidence of Thrombus Formation With Cryoenergy Versus Radiofrequency Catheter Ablation. *Circulation*. 2003;107:2045-2050.
- Wong T, Markides V, Peters NS, Davies DW. Percutaneous pulmonary vein cryoablation to treat atrial fibrillation. *J Interv Card Electrophysiol*. 2004;11:117-126.
- Avitall B, Urboniene D, Rozmus G, Lafontaine D, Helms R, Urbonas A. New cryotechnology for electrical isolation of the pulmonary veins. *J Cardiovasc Electrophysiol*. 2003;14:281-286.
- Van Belle Y, Janse P, Rivero-Ayerza MJ, Thornton AS, Jesurun ER, Theuns D, Jordaens L. Pulmonary vein isolation us-

ing an occluding cryoballoon for circumferential ablation: feasibility, complications, and short-term outcome. *Eur Heart J*. 2007;28:2231-2237.

13. Chun KRJ, Schmidt B, Metzner A, Tilz R, Zerm T, Koster I, Furnkranz A, Koektuerk B, Konstantinidou M, Antz M, Ouyang F, Kuck KH. The 'single big cryoballoon' technique for acute pulmonary vein isolation in patients with paroxysmal atrial fibrillation: a prospective observational single centre study. *European Heart Journal*. 2008;ehn570.

14. Reddy VY, Neuzil P, d'Avila A, Laragy M, Malchano ZJ, Kralovec S, Kim SJ, Ruskin JN. Balloon catheter ablation to treat paroxysmal atrial fibrillation: what is the level of pulmonary venous isolation? *Heart Rhythm*. 2008;5:353-360.

15. Antz M, Chun KR, Ouyang F, Kuck KH. Ablation of atrial fibrillation in humans using a balloon-based ablation system: identification of the site of phrenic nerve damage using pacing maneuvers and CARTO. *J Cardiovasc Electrophysiol*. 2006;17:1242-1245.

16. Schmidt B, Antz M, Ernst S, Ouyang F, Falk P, Chun JKR, Kuck KH. Pulmonary vein isolation by high-intensity focused ultrasound: First-in-man study with a steerable balloon catheter. *Heart Rhythm*. 2007;4:575-584.

17. Phillips KP, Schweikert RA, Saliba WI, Themistoclakis S, Raviele A, Bonso A, Rossillo A, Burkhardt JD, Cummings J, Natale A. Anatomic location of pulmonary vein electrical disconnection with balloon-based catheter ablation. *J Cardiovasc Electrophysiol*. 2008;19:14-18.

18. SANCHEZ-QUINTANA DAMI, CABRERA JA, CLIMENT VICE, FARRE JERO, WEIGLEIN ANDR, HO SY. How Close Are the Phrenic Nerves to Cardiac Structures? Implications for Cardiac Interventionalists. *Journal of Cardiovascular Electrophysiology*. 2005;16:309-313.

19. Kato R, Lickfett L, Meininger G, Dickfeld T, Wu R, Juang G, Angkeow P, LaCorte J, Bluemke D, Berger R, Halperin HR, Calkins H. Pulmonary Vein Anatomy in Patients Undergoing Catheter Ablation of Atrial Fibrillation: Lessons Learned by Use of Magnetic Resonance Imaging. *Circulation*. 2003;107:2004-2010.

20. Klein G, Oswald H, Gardiwal A, Lnsebrink U, Lissel C, Yu H, Drexler H. Efficacy of pulmonary vein isolation by cryoballoon ablation in patients with paroxysmal atrial fibrillation. *Heart Rhythm*. 2008;5:802-806.